

## Leptospirosis Diagnostic Challenges, American Samoa

**To the Editor:** Leptospirosis is common in the Pacific Islands (66.4 cases/100,000 population/year compared with 5 cases/100,000 population/year globally) (1) and is often misdiagnosed as dengue because of overlapping clinical features, poor awareness, and inadequate diagnostic facilities (2,3). Clinical manifestations range from asymptomatic to severe disease with pulmonary hemorrhage and renal and hepatic failure.

Global emergence of leptospirosis has been associated with environmental factors including rainfall, flooding, poverty, urbanization, and ecotourism (1–4), to which the Pacific Islands are vulnerable. Seroprevalence of leptospirosis in American Samoa is 15.5% (5), and recent reports confirm its emergence in the Pacific region (6). We report a case of severe leptospirosis in American Samoa (one of the world's wettest inhabited places) and illustrate diagnostic challenges and the need to improve laboratory capacity.

In January 2011 (wet season), a 15-year-old previously healthy Polynesian boy was examined for a 3-day history of fever, myalgia, fatigue, headache, sore throat, pleuritic chest pain, and vomiting. He spent much time outdoors, occasionally slept in the rainforest, and had recently waded through water.

Examination revealed lethargy, injected conjunctivae, mild periumbilical tenderness, fever (38.6°C), tachycardia (133 beats/minute), and hypotension (96/50 mm Hg). Lung sounds were clear, respiratory rate was 22 breaths/minute, and oxygen saturation was 99%. No rash or jaundice was noted. Laboratory investigations showed leukocytosis ( $9.35 \times 10^9$  cells/L), neutrophilia (85%), mild normocytic anemia (12.0

g/dL), and thrombocytopenia ( $42 \times 10^9$  platelets/L); chest radiographs showed mild infiltrate in the left lung.

Differential diagnosis included dengue, influenza, pneumonia, and leptospirosis. The patient was hospitalized for supportive treatment, but the next day he experienced shoulder pain, increased abdominal and chest pain, worsened thrombocytopenia, hypokalemia, hyperbilirubinemia, proteinuria, hematuria, and fecal occult blood. No abnormalities were found for the following: transaminase, alkaline phosphatase, blood urea nitrogen, and creatinine levels; blood culture; serologic test results for hepatitis; and abdominal ultrasonogram.

Intravenous penicillin was given for possible leptospirosis and/or pneumonia. Within 1 hour, the patient's condition deteriorated: temperature increased (40.2°C); and rigors, severe headache, and myalgia developed. Jarisch-Herxheimer reaction was considered (7), and intravenous penicillin was replaced with ceftriaxone. The patient deteriorated further and exhibited hypotension, tachycardia, tachypnea, jaundice, confusion, mucosal bleeding, and required intensive care treatment, including intravenous dopamine for shock. Repeat chest radiograph showed deterioration with bilateral infiltrates. The Figure shows progression of kidney and liver function and thrombocytopenia.

Serum collected on hospitalization day 2 was negative for IgM against *Leptospira* spp. according to the GenBio IgM ImmunoDOT test (San Diego, CA, USA) (8). Serum collected on day 3 was positive for IgM and IgG against dengue virus according to the TECO rapid diagnostic test (Anaheim, CA, USA) (8), suggesting dengue hemorrhagic fever. The patient continued to receive intravenous ceftriaxone because of worsening condition and clinical suspicion of leptospirosis. He improved with antimicrobial drug treatment and

supportive care, and his serum on day 9 was positive for IgM against *Leptospira* spp.

Subsequent serologic testing in Brisbane, Australia, confirmed leptospirosis and excluded dengue. Microscopic agglutination test results confirmed acute infection with *L. interrogans* serovar Copenhageni; rising titers were found in serum collected on days 3 (<50), 8 (100), and 17 (400). All samples were negative for IgM and IgG against dengue virus according to the PanBio Dengue IgM and IgG Capture ELISA tests (Sinnamonn Park, Queensland, Australia) (sensitivity 99.2%, specificity 96.2%) (9).

This case illustrates that leptospirosis in the Pacific Islands presents many clinical challenges. This patient experienced a life-threatening illness with multiple complications associated with severe leptospirosis, including possible Jarisch-Herxheimer reaction. Early diagnosis is crucial because appropriate treatment with antimicrobial drugs can reduce illness and death (1,2). Molecular techniques provide rapid diagnosis during the bacteremic phase but are expensive and often unavailable in developing countries (1–3). Rapid tests for dengue virus have limited sensitivity and specificity and can produce false-positive results in patients with leptospirosis and other conditions (8). Serologic testing for leptospirosis detects acute infections only after the second week of illness, so it was crucial that leptospirosis was not excluded early when results were positive for dengue virus but negative for *Leptospira* spp.

During January 2009–June 2011, incidence rates for dengue and leptospirosis among children  $\leq 16$  years of age in American Samoa were 517 and 159 cases per 100,000 population per year, respectively; incidence was highest in the wettest months. Incidence of each infection peaked in October 2009 (1,512 and 798 cases/100,000

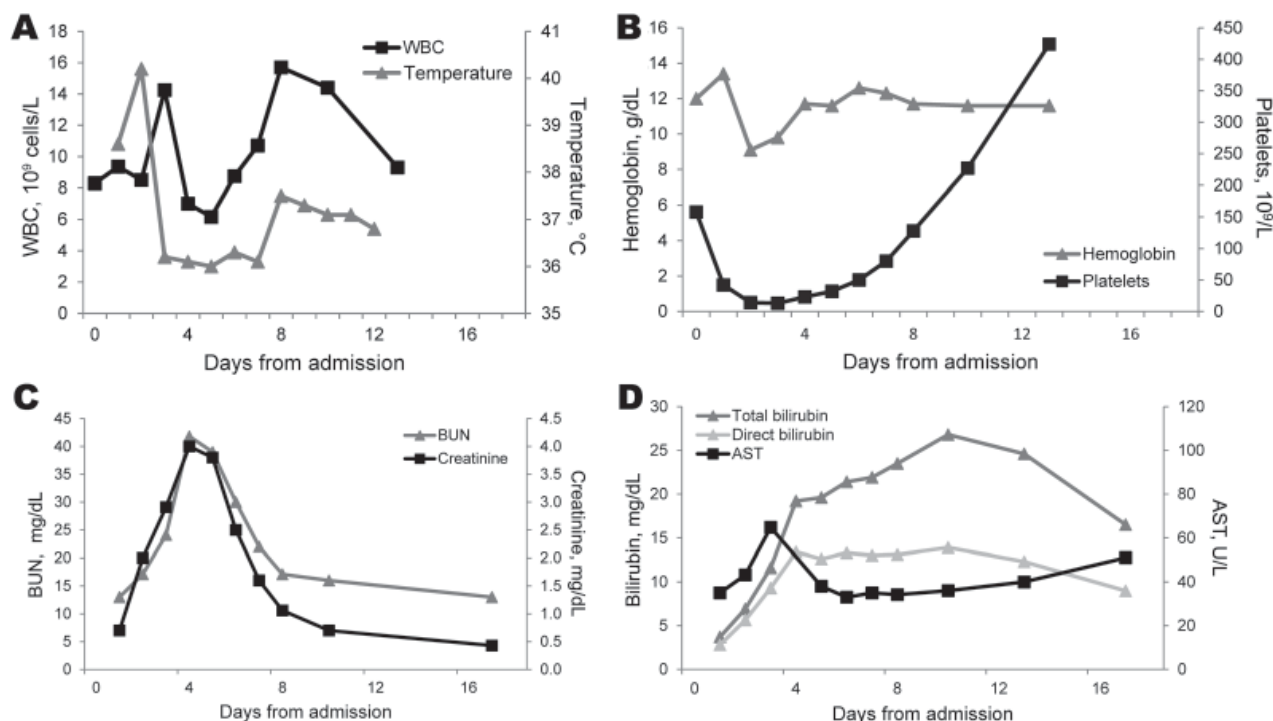


Figure. Clinical course of temperature and selected laboratory results in a patient with severe leptospirosis in American Samoa. A) Temperature and leukocyte (WBC) counts (reference range  $5.0\text{--}9.1 \times 10^9$  cells/L). B) Hemoglobin (reference range  $14.0\text{--}16.3$  g/dL) and platelet counts (reference range  $150\text{--}450 \times 10^9$  platelets/L). C) Blood urea nitrogen (BUN) (reference range  $5\text{--}18$  mg/dL) and creatinine (reference range  $0.5\text{--}1.0$  mg/dL) levels. D) Total bilirubin (reference range  $0.3\text{--}1.2$  mg/dL), direct bilirubin (reference range  $0\text{--}0.2$  mg/dL), and aspartate aminotransferase (AST) (reference range  $15\text{--}45$  U/L) levels.

population/year), possibly related to the late September 2009 tsunami (10).

Flooding increases risk for dengue infection (by providing mosquito breeding sites) and leptospirosis (by disseminating leptospires in the environment and increasing human-animal contact). Concurrent outbreaks and co-infections are not uncommon and can complicate diagnosis. Incidence rates for both infections will probably increase with climate change in the Pacific region (4). Cocirculation of dengue serotypes increases incidence of dengue hemorrhagic fever and dengue shock syndrome, which are difficult to clinically distinguish from severe leptospirosis. Jarisch-Herxheimer reactions in leptospirosis patients treated with antimicrobial drugs can further complicate diagnosis (7). To reduce leptospirosis in the Pacific Islands, awareness of the disease,

understanding of limitations of rapid diagnostic tests, and more regional laboratory capacity are needed.

#### Acknowledgments

We thank Maria Matijasevic for caring for the patient in the intensive care unit, James Marrone and Michael Favazza for providing incidence data on leptospirosis and dengue in children in American Samoa, Lee Smythe and Michael Dohnt for performing the leptospirosis serologic testing, and John Aaskov and the Australian Army Malaria Institute, Brisbane, Australia for performing the dengue serologic testing.

**Colleen L. Lau  
and John M. DePasquale**

Author affiliations: The University of Queensland, Herston, Queensland, Australia (C.L. Lau); and Lyndon Baines Johnson Tropical Medical Center, Pago Pago, American Samoa (J.M. DePasquale)

DOI: <http://dx.doi.org/10.3201/eid1812.120429>

#### References

- World Health Organization. Report of the second meeting of the Leptospirosis Burden Epidemiology Reference Group. Geneva: The Organization; 2011 [cited 2012 Mar 8]. [http://whqlibdoc.who.int/publications/2011/9789241501521\\_eng.pdf](http://whqlibdoc.who.int/publications/2011/9789241501521_eng.pdf)
- Bharti AR, Nally JE, Ricaldi JN, Matthias MA, Diaz MM, Lovett MA, et al. Leptospirosis: a zoonotic disease of global importance. *Lancet Infect Dis*. 2003;3:757-71. [http://dx.doi.org/10.1016/S1473-3099\(03\)00830-2](http://dx.doi.org/10.1016/S1473-3099(03)00830-2)
- Lau C, Smythe L, Weinstein P. Leptospirosis: an emerging disease in travellers. *Travel Med Infect Dis*. 2010;8:33-9. <http://dx.doi.org/10.1016/j.tmaid.2009.12.002>
- Lau CL, Smythe LD, Craig SB, Weinstein P. Climate change, flooding, urbanisation and leptospirosis: fuelling the fire? *Trans R Soc Trop Med Hyg*. 2010;104:631-8. <http://dx.doi.org/10.1016/j.trstmh.2010.07.002>

5. Lau CL, Dobson A, Smythe L, Fearnley E, Skelly C, Clements A, et al. Leptospirosis in American Samoa 2010—epidemiology, environmental drivers, and the management of emergence. *Am J Trop Med Hyg.* 2012;86:309–19. <http://dx.doi.org/10.4269/ajtmh.2012.11-0398>
6. Berlioz-Arthaud A, Kiedrzyński T, Singh N, Yvon JF, Roualen G, Coudert C, et al. Multicentre survey of incidence and public health impact of leptospirosis in the western Pacific. *Trans R Soc Trop Med Hyg.* 2007;101:714–21. <http://dx.doi.org/10.1016/j.trstmh.2007.02.022>
7. Friedland JS, Warrell DA. The Jarisch-Herxheimer reaction in leptospirosis: possible pathogenesis and review. *Rev Infect Dis.* 1991;13:207–10. <http://dx.doi.org/10.1093/clinids/13.2.207>
8. Blacksell SD, Newton PN, Bell D, Kelley J, Mammen MP Jr, Vaughn DW, et al. The comparative accuracy of 8 commercial rapid immunochromatographic assays for the diagnosis of acute dengue virus infection. *Clin Infect Dis.* 2006;42:1127–34. <http://dx.doi.org/10.1086/501358>
9. McBride WJ, Mullner H, LaBrooy JT, Wronski I. The 1993 dengue 2 epidemic in North Queensland: a serosurvey and comparison of hemagglutination inhibition with an ELISA. *Am J Trop Med Hyg.* 1998;59:457–61.
10. Dudley WC, Whitney R, Faasisila J, Fonolua S, Jowitt A, Chan-Kau M. Learning from the victims: new physical and social science information about tsunamis from victims of the September 29, 2009 event in Samoa and American Samoa. *Earth-Science Reviews.* 2011;107:201–6. <http://dx.doi.org/10.1016/j.earscirev.2011.03.005>

Address for correspondence: Colleen L. Lau, PO Box 12426, George St, Brisbane, Queensland 4003, Australia; email: [colleen.lau@uqconnect.edu.au](mailto:colleen.lau@uqconnect.edu.au)

**EID**  
online  
[wwwnc.cdc.gov/eid](http://wwwnc.cdc.gov/eid)

## African Swine Fever Virus, Tanzania, 2010–2012

**To the Editor:** African swine fever (ASF) is a highly contagious and deadly hemorrhagic disease of domestic pigs caused by African swine fever virus (ASFV), a double-strand DNA virus of the family *Asfarviridae* and genus *Asfivirus* (1). Twenty-two ASFV genotypes (I–XXII) have been identified on the basis of nucleotide sequencing of the variable 3′-end of the *B646L* gene encoding the major capsid protein p72 (2,3).

Historically, all ASFV p72 genotypes have been circulating in eastern and southern Africa, and genotype I has been circulating in Europe, South America, the Caribbean, and western Africa (2,3). Spread of ASFV beyond traditional geographic boundaries occurred with incursion of p72 genotype II into the Republic of Georgia and its subsequent spread into Armenia, Azerbaijan, and Russia (4,5) and incursion of genotype IX into western Africa (6). ASFV circulating in Tanzania has p72 genotypes X, XV, and XVI (7–10). We describe incursion and persistent circulation in Tanzania of a highly virulent p72 genotype II ASFV that is identical to the Georgia 2007/1 isolate in the 3′-end of the *B646L* gene.

An outbreak of ASF in domestic pigs occurred in November 2010 in the Kyela District of the Mbeya region in southwestern Tanzania, which coincided with another outbreak in a neighboring district of Karonga in northern Malawi (Figure, panel A). ASF continued to spread from Mbeya and ultimately reached the neighboring region of Iringa (Ludewa District) in February 2011 through feeding of pigs with swill from Mbeya. By March 2011, ASF had spread to Chunya, Ileje, Mbarali, Rungwe, and Tukuyu districts within Mbeya. The disease

spread within the region because of the lack of zoosanitary measures and illegal movement of animals despite the quarantine in place. An outbreak on 1 farm in the Temeke District of the Dar es Salaam region in eastern Tanzania occurred in March 2011 after a farmer obtained pig stock from Mbeya. No further spread of the disease in Dar es Salaam was observed after early diagnosis, removal of affected pigs, and zoosanitary measures.

In October 2011, the disease spread to the Sumbawanga District of the Rukwa region through feeding of swill and illegal movement of animals. ASF was reported in February 2012 in Ifakara in the Kilombero District in the Morogoro region, and in July 2012 in the Kilosa District within this region. The disease spread into Kilombero District after 1 farmer purchased pigs for stock from the Iringa region. As of July 2012, ASF was reported again in the Mbeya and Iringa regions, from which it had been eliminated. This unique ASF outbreak in Tanzania persistently circulated for more than a year; previous outbreaks have been sporadic and resolved after shorter durations (8–10).

Mortality rates of 100% caused by ASF were recorded in domestic pigs of all ages in all outbreak areas. Affected pigs showed pyrexia and anorexia, dragged their hind legs, and then showed recumbence. In addition, affected animals had severe cutaneous hemorrhages, especially on medial and lateral sides of the pinna, forelimbs above the carpal joint, facial region, scrotum, and mammary glands (Figure, panels B and C). Postmortem lesions included darkening and enlargement of the spleen, severe hemorrhages of mesenteric and gastrohepatic lymph nodes, and hemorrhagic enteritis (Figure, panels D–G).

DNA was extracted from spleens of animals that either died of the disease or were killed at slaughterhouses during 2010–2012. The variable 3′-