

Review article

# The Smith-Lemli-Opitz syndrome

Richard I Kelley, Raoul C M Hennekam

**Abstract**

**The Smith-Lemli-Opitz syndrome (SLOS) is one of the archetypical multiple congenital malformation syndromes. The recent discovery of the biochemical cause of SLOS and the subsequent redefinition of SLOS as an inborn error of cholesterol metabolism have led to important new treatment possibilities for affected patients. Moreover, the recent recognition of the important role of cholesterol in vertebrate embryogenesis, especially with regard to the hedgehog embryonic signalling pathway and its effects on the expression of homeobox genes, has provided an explanation for the abnormal morphogenesis in the syndrome. The well known role of cholesterol in the formation of steroid hormones has also provided a possible explanation for the abnormal behavioural characteristics of SLOS.**

(J Med Genet 2000;37:321-335)

Keywords: Smith-Lemli-Opitz syndrome; cholesterol metabolism; 7-dehydrocholesterol reductase; clinical history; management

**History**

The Smith-Lemli-Opitz syndrome was first described in 1964 by the late David Smith, the Belgian paediatrician Luc Lemli, and John Opitz<sup>1</sup> in a report of three patients who had in common a distinctive facial appearance, microcephaly, broad alveolar ridges, hypospadias, a characteristic dermatoglyphic pattern, severe feeding disorder, and global developmental delay. A more complete delineation of SLOS was presented in 1969 as the “RSH syndrome”, a non-descriptive acronym of the first letters of the original patients’ surnames.<sup>2</sup> The description of many new cases of SLOS over the next 20 years expanded the known characteristics of the syndrome, especially in the recognition of multiple internal anomalies (table 1).<sup>2-11</sup> Many affected children died in the first year from failure to thrive and infections, but many others survived to adulthood. Somewhat later, several authors described patients with a lethal syndrome that resembled SLOS, and which they designated “type II SLOS”.<sup>12-16</sup> These children had many of the anomalies found in SLOS, but died in the newborn period from internal malformations. Moreover, most 46,XY “males” with so called type II SLOS had severe hypogenitalism or female appearing external

genitalia. In all informative families, segregation of either form of SLOS was consistent with autosomal recessive inheritance.<sup>2,12</sup> The genetic cause of the disorder was not suspected for many years, although by the mid 1980s a number of abnormalities of steroid metabolism in SLOS had been reported, including enlarged, lipid depleted adrenal glands<sup>17</sup> and aberrant patterns of steroid sulphates in plasma and urine.<sup>12,17,18</sup> Nevertheless the primary defect remained unknown until Natowicz and Evans<sup>19</sup> found that a patient with SLOS had essentially undetectable levels of normal urinary bile acids. An analysis of that patient’s plasma sterols led to the discovery<sup>20</sup> that the patient had a more than 1000-fold increase in the level of 7-dehydrocholesterol (cholesta-5,7-dien-3beta-ol; 7DHC), suggesting a deficiency of 7-dehydrocholesterol reductase (DHCR7), the final step in the Kandutsch-Russell cholesterol biosynthetic pathway.<sup>21</sup> The same sterol pattern has subsequently been found in most patients with either type of SLOS, as well as in patients with variant syndromes that could not be assigned the diagnosis of SLOS on clinical grounds alone.<sup>22,23</sup> Although initial evidence suggested that the human gene for SLOS was located at 7q32.1, the human *DHCR7* gene was later cloned and localised to chromosome 11q12-13 by Moebius *et al.*<sup>24</sup> Shortly afterwards, three groups independently reported apparently disabling mutations of *DHCR7* in patients with SLOS.<sup>24-26</sup>

Table 1 Findings in 167 clinically diagnosed cases of Smith-Lemli-Opitz syndrome compared with 164 biochemically confirmed cases

| Finding                      | Clinically diagnosed (%) | Biochemically confirmed (%) |
|------------------------------|--------------------------|-----------------------------|
| Mental retardation           | 97                       | 95                          |
| Postnatal growth retardation | 85                       | 82                          |
| Microcephaly                 | 80                       | 84                          |
| Structural brain anomalies   | 60                       | 37                          |
| Ptosis                       | 69                       | 70                          |
| Cataract                     | 23                       | 22                          |
| Anteverted nares             | 90                       | 78                          |
| Cleft palate*                | 51                       | 47                          |
| Congenital heart defect      | 50                       | 54                          |
| Abnormal lung lobation       | 40                       | 45                          |
| Pyloric stenosis             | 15                       | 14                          |
| Colonic aganglionosis        | 12                       | 16                          |
| Renal anomalies              | 40                       | 43                          |
| Genital anomalies            | 74                       | 65                          |
| 2/3 toe syndactyly           | 85                       | 97                          |
| Polydactyly†                 | 52                       | 48                          |

\*Includes cleft soft palate, submucous cleft, and cleft uvula.  
 †Includes postaxial polydactyly of hand(s)/foot.

The Johns Hopkins University, Kennedy Krieger Institute, 707 North Broadway, Baltimore, Maryland 21205, USA  
 R I Kelley

Institute for Human Genetics and Department of Paediatrics, Academic Medical Centre, University of Amsterdam, Meibergreef 15, 1105 AZ Amsterdam, The Netherlands  
 R C M Hennekam

Correspondence to: Dr Hennekam, r.c.hennekam@amc.uva.nl

## Clinical overview

### GENERAL

Although most published reports of SLOS describe only a single patient or a small number of patients, there are a few exceptions in which 10 or more cases are described.<sup>2 9 12 23 27-29</sup> Furthermore, several excellent older reviews exist.<sup>10 15 30</sup> A tabulation of the major clinical features of patients described in sufficient detail is provided in table 1. A comparison of the most common characteristics of patients ascertained by clinical *v* biochemical diagnosis shows similar frequencies of the physical anomalies. Only structural brain anomalies and anomalies of the genitalia are somewhat more common in the clinically diagnosed group. Before the recognition of the biochemical cause of SLOS, several authors suggested division of SLOS into the relatively less expressed type I form and the more severe type II form.<sup>12 13 31</sup> Curry *et al*<sup>12</sup> cautiously suggested that type I and type II might differ genetically, whereas others thought the subdivision was not justified.<sup>32</sup> To address this question, Bialer *et al*<sup>15</sup> devised a scoring system to evaluate the clinical severity of SLOS. Upon scoring 122 published cases, they found a unimodal frequency distribution of the scores for various anomalies, which was interpreted as evidence for a continuum of severity in SLOS and against a genetic distinction between types I and II SLOS. However, because length of survival was part of the original scoring in addition to separate scores for individual visceral anomalies, the original scoring system of Bialer *et al*<sup>15</sup> was overweighted for internal anomalies. Therefore, we (Kelley and Hennekam, unpublished data) modified the Bialer score, to weight embryologically separate organ systems equally. The revised scoring system (table 2) has been used in two series of biochemically confirmed cases<sup>23 27</sup> and showed a continuum of severity and strong correlations with various biochemical parameters. Subsequent molecu-

lar genetic studies confirmed that the differences in severity between types I and II SLOS are explained by the severity of the mutations responsible. However, these results do not preclude the existence of genetic heterogeneity in SLOS; recently two mildly affected sibs were found to have probably a related but biochemically different disorder of sterol metabolism.<sup>33</sup>

### INCIDENCE

The earliest estimate of the incidence of SLOS was made by Lowry and Yong,<sup>34</sup> who found an incidence in British Columbia of 1/40 000 births and a carrier frequency of 1%. The incidence in that survey increased to 1/20 000 births when suspected but less definite cases were included. The incidence in a completely ascertained newborn population in Middle Bohemia (Czech Republic) was estimated to be greater than 1 in 10 000.<sup>35</sup> However, in contrast to these relatively high incidences based exclusively on clinical diagnosis, the incidence of SLOS diagnosed biochemically in similar populations appears to be much lower. For example, between 1995 and 1998, when knowledge of the biochemical defect was widespread, the two laboratories that perform at least 80% of biochemical testing for SLOS in the United States identified only about 40 new cases per year, or an estimated incidence of less than 1 in 60 000 births (Kelley and Tint, unpublished data). Similarly, estimates of only 1 in 60 000 newborns in the United Kingdom,<sup>27</sup> 1 in 80 000-100 000 births in The Netherlands (Waterham *et al*, unpublished data), and an even lower incidence in Japan<sup>36</sup> have been reported. The number of cases with African,<sup>23 37</sup> Asian,<sup>38 39</sup> or South American<sup>40</sup> ancestry is also low. Although there remains some uncertainty about the absolute incidence of SLOS in some countries, there clearly are strikingly different incidences among various ethnic groups. Both heterozygote advantage and founder effect have been suggested to explain the relatively higher incidence of SLOS among those of European descent. The percentage of patients born to consanguineous parents is relatively low for an autosomal recessive entity,<sup>23 27 35</sup> which suggests persistence in the population of multiple mutant alleles through heterozygote advantage.

### CRANIOFACIAL CHARACTERISTICS

In the following listing of cases with various features, no indication is made of whether a case was biochemically confirmed or not. In general, cases published after 1994 will have been biochemically confirmed, but in cases from earlier papers this remains unknown. The "SLOS face" is highly characteristic of the syndrome and easily recognised in most patients, but may be very subtle in some.<sup>27 41</sup> The most salient features are microcephaly, bitemporal narrowing, ptosis, a short nasal root, anteverted nares, and a small chin (fig 1).

Congenital microcephaly is very common (for exact percentages of this and other symptoms see table 1). Although a prominent ridge along the metopic suture can often be palpated, true craniosynostosis is uncommon.<sup>2 12</sup> More

Table 2 Adapted (from ref 15) severity score for anatomical abnormalities in Smith-Lemli-Opitz syndrome

| Organ     | Score | Criteria   |
|-----------|-------|--|
| Brain     | 1     | Seizures; qualitative MRI abnormality  |
|           | 2     | Major CNS malformations; gyral defects   |
| Oral      | 1     | Bifid uvula or submucous cleft   |
|           | 2     | Cleft hard palate or median cleft lip  |
| Acral     | 0     | Non-Y shaped minimal toe syndactyly  |
|           | 1     | Y shaped 2/3 toe syndactyly; club foot; upper or lower polydactyly; other syndactyly |
|           | 2     | Any two of the above   |
| Eye       | 2     | Cataract; frank microphthalmia   |
| Heart     | 0     | Functional defects   |
|           | 1     | Single chamber or vessel defect  |
|           | 2     | Complex cardiac malformation   |
| Kidney    | 0     | Functional defect  |
|           | 1     | Simple cystic kidney disease   |
|           | 2     | Renal agenesis; clinically important cystic disease                                  |
| Liver     | 0     | Induced hepatic abnormality  |
|           | 1     | Simple structural abnormality  |
|           | 2     | Progressive liver disease  |
| Lung      | 0     | Functional pulmonary disease   |
|           | 1     | Abnormal lobation; hypoplasia  |
|           | 2     | Pulmonary cysts; other major malformations   |
| Bowel     | 0     | Functional GI disease  |
|           | 1     | Pyloric stenosis   |
|           | 2     | Hirschsprung disease   |
| Genitalia | 1     | Simple hypospadias   |
|           | 2     | Ambiguous or female genitalia in 46,XY; frank genital malformation in 46,XX          |

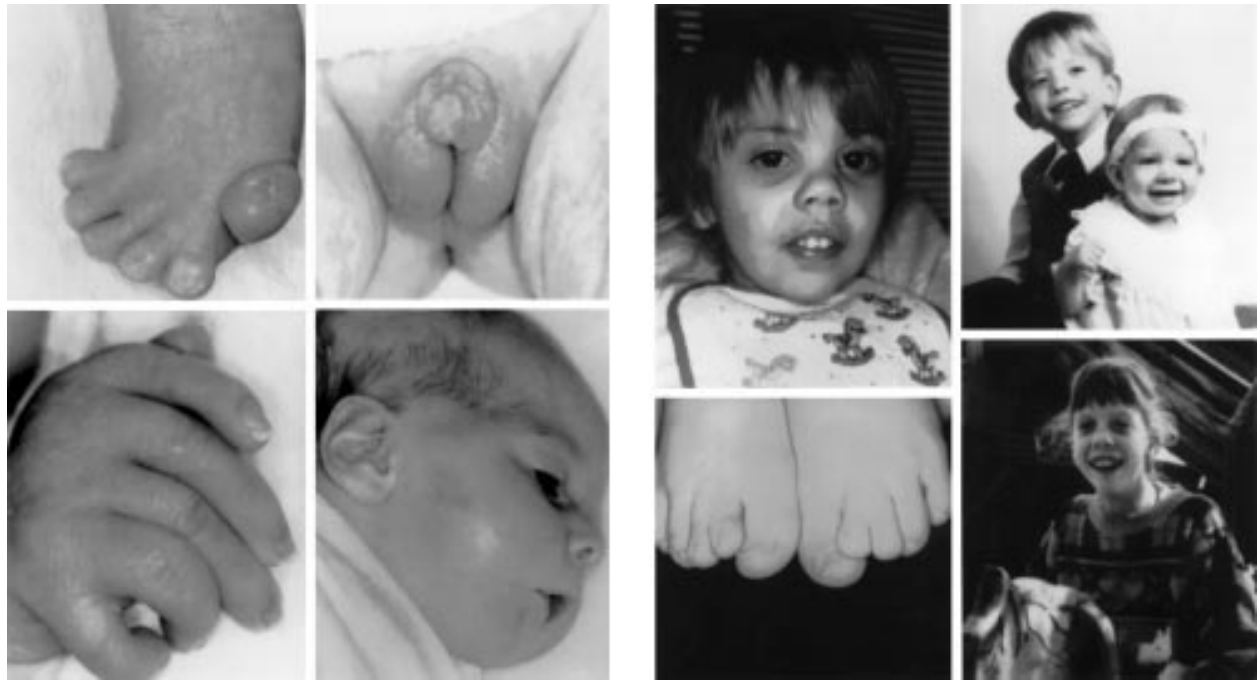

Figure 1 Patients with Smith-Lemli-Opitz syndrome.

than half of the patients have ptosis, often asymmetrical or unilateral. The palpebral fissures are usually straight, but both upward and downward slanting occurs. Other less frequent external eye anomalies include hypertelorism, epicanthic folds, absence of lacrimal puncta,<sup>42</sup> and unusually long cilia.<sup>43</sup> Mild exophthalmos has not been reported often,<sup>2</sup> but is relatively commonly seen in figures in publications. Ocular defects include mainly congenital and occasionally postnatal cataracts, strabismus, and nystagmus.<sup>11 44-46</sup> Vision is usually normal. Less common symptoms are sclerocornea,<sup>13 43 47</sup> heterochromia iridis,<sup>48</sup> coloboma of the iris,<sup>16 42</sup> posterior synechiae,<sup>6 45 49</sup> glaucoma,<sup>2 12</sup> retinal hyperpigmentation,<sup>2</sup> optic atrophy,<sup>2 12 45</sup> optic pits,<sup>42</sup> microphthalmia,<sup>5 23</sup> and abnormalities of eye movements.<sup>44</sup> Aniridia was reported by Gracia *et al.*<sup>50</sup> but the diagnosis in this mentally normal child with bilateral gonadoblastoma may be questioned.

A hallmark of the syndrome is the shape of the nose; usually the nasal bridge and base are broad, the nasal root short, and the nares anteverted. The nasal bridge can be flat or high, often with a striking capillary haemangioma extending across the glabella. The degree of anteversion of the nares decreases with age, but remains distinct in many adults.<sup>27 48 59</sup> Narrow or atretic choanae may occur.<sup>51</sup>

The ears often appear low set and posteriorly rotated, but are otherwise unremarkable. Rarely, the ear canals have been reported to be very small.<sup>8 52</sup> Congenital sensorineural hearing deficits may affect as many as 10% of patients, but many more severely affected children are not tested. Anomalies of the inner ear shown by radiography or found at necropsy have been described.<sup>53 54</sup> The philtrum is long, as can be expected in shortening of the nose. Although cleft lip has been reported in SLOS,<sup>13 55-57</sup> only the "midline" type of cleft associated with the

holoprosencephaly sequence has been found in patients with abnormal cholesterol metabolism.<sup>58</sup> In some patients, the mouth is large, which, combined with frequent micrognathia, gives a distinctive appearance.<sup>59</sup> More severe micrognathia, including the classical Pierre Robin sequence, is not rare in SLOS.

The intraoral anomalies of SLOS are diagnostically important. The palate is usually highly arched, often with a midline cleft of the uvula, soft palate, or hard palate. In addition, the alveolar ridges typically are abnormally broad and conspicuously ridged. The tongue can be small with redundant sublingual tissue<sup>12</sup> or sublingual cysts<sup>13 31</sup> in the more severely affected children. More rarely, the tongue is bifid.<sup>27</sup> Crowded teeth and widely spaced incisors are not uncommon,<sup>27 44 52</sup> and oligodontia or polydontia,<sup>44</sup> unusually large central upper incisors,<sup>27 59</sup> enamel hypoplasia,<sup>10</sup> and premature tooth eruption<sup>60</sup> have been reported. A detailed dental study in SLOS, however, has not been published. Pharyngeal abnormalities have included a small larynx<sup>13</sup> and small vocal cords with a subglottal shelf of excess fibrocartilaginous tissue.<sup>12</sup>

The neck can appear short and excessive skin folds or nuchal oedema are common, especially prenatally.<sup>61</sup>

#### CENTRAL NERVOUS SYSTEM

The structural brain abnormalities of SLOS have been reviewed by Garcia *et al.*,<sup>62</sup> Cherstvoy *et al.*,<sup>63</sup> and Marion *et al.*<sup>64</sup> In addition to microcephaly, which is almost universal in SLOS, common abnormalities include enlarged ventricles,<sup>2 12 52 63 65 66</sup> hypoplastic or absent corpus callosum,<sup>12 27 57 63 66 67</sup> hypoplastic frontal lobes,<sup>3 9</sup> and pituitary lipoma.<sup>68</sup> Cerebellar hypoplasia, sometimes with severe hypoplasia or aplasia of the vermis, is also not uncommon.<sup>2 5 9 27 44 52 53 62 64 67</sup> Various forms of

the holoprosencephaly sequence occur in about 5% of patients.<sup>5 13 17 23 58</sup> On histological examination of the brain, the most important findings are disturbed cerebral neuronal migration,<sup>12 27 64 67 69 72 73</sup> extensive gliosis,<sup>12</sup> dysplasia of the medial olivary nuclei, and ectopic Purkinje cells.<sup>9 44</sup> Several authors<sup>27 44 62 67 70-72 74</sup> have reported maturational abnormalities of the white matter; however, most cranial MRI studies do not show white matter abnormalities. Although seizures are not uncommonly reported in SLOS, including infantile spasms,<sup>32 75</sup> they are uncommon in biochemically proven cases of SLOS and may not be substantially more frequent than in children without SLOS.<sup>2 3 7 27 48 52 62 69 76</sup> The same reservation must be applied to a number of central nervous system malformations reported in older SLOS publications before biochemical confirmation was available.

#### SKELETAL ANOMALIES

The skeletal anomalies have been reviewed in detail.<sup>10 15 23 27 63</sup> Bilateral or unilateral postaxial polydactyly can be present in the hands or, less commonly, the feet, or both. Preaxial polydactyly has not been reported in a biochemically proven case. The thumb is generally short and proximally placed and the first metacarpals and thenar eminences are typically hypoplastic.<sup>2 12 77-79</sup> Other unusual digital abnormalities include ectrodactyly,<sup>56 70 80</sup> monodactyly,<sup>80</sup> oligodactyly,<sup>56 81 82</sup> radial agenesis,<sup>80</sup> brachydactyly, absent middle phalanx of the second finger, radial or ulnar deviation of the fingers, clinodactyly, camptodactyly, and various syndactylies.<sup>2 10 12 27 56 70 80</sup> Rhizomelic and mesomelic limb shortness and, more rarely, "chondrodysplasia punctata" occur in SLOS, but a true chondrodystrophy is not found.<sup>12 13 16 23 27 29 63 70</sup> Dermatoglyphics in SLOS have been reported to be distinctive with an increased proportion of whorls and decreased proportion of ulnar loops on the finger tips in most series,<sup>2 10 12 52</sup> but not all.<sup>83</sup> The presence of whorls may point to a pathogenesis through puffy finger tip pads or oedema during early fetal development. There is no study as yet of dermatoglyphic findings in a group of biochemically proven cases, but whorls appear to predominate as commonly reported in the early case reports.

One of the most consistently present anomalies in SLOS is the distinctive "Y shaped" cutaneous syndactyly of the second and third toes, which has been reported in up to 99% of biochemically proven cases.<sup>23 27</sup> Postaxial polydactyly of the feet is common in severe SLOS, and sometimes takes the form of polysyndactyly with a "windswept" foot deformity.<sup>12 13 15 16 27 45 48 63 72 84</sup> Other lower limb abnormalities include club foot, varus or valgus foot deformities, short first toes, and hip dislocations.<sup>9 12 27 31</sup> Occasionally reported skeletal abnormalities include dense base of the skull,<sup>31</sup> scoliosis,<sup>34 52 69 78</sup> kyphosis,<sup>35 71 78</sup> ovoid vertebrae,<sup>68</sup> cervical ribs,<sup>54 78 82</sup> thin ribs,<sup>37 68 85</sup> and missing ribs.<sup>71</sup> Although epiphyseal stippling ("chondrodysplasia punctata") has been reported in a few cases,<sup>1 32 57 68 86</sup> such stippling

has been found in only one biochemically confirmed patient,<sup>87</sup> who also had a de novo balanced chromosome translocation.

#### GENTIL ANOMALIES

The genitalia in male SLOS patients range from normal to the appearance of complete sex reversal.<sup>12-15 60 65</sup> Classically, hypospadias varies from coronal to perineoscrotal hypospadias, although the latter is uncommon except in the biochemically most severely affected cases. Malescent of the testes is common, but, even with severely malformed genitalia, the testes are often easily palpated in the scrotum, which is sometimes bifid.<sup>72 88</sup> Mullerian duct derivatives are usually absent in 46,XY males, as expected, but blind ending vagina, rudimentary or bicornuate uterus, and persistent cloaca have been described.<sup>12 13 15 31 51 89</sup> The gonads vary from normal testes to ovotestes to normal ovaries, or may be missing.<sup>5</sup> In females, the external genitalia may appear normal or there may be distinct hypoplasia of the labia majora and minora. There are also single reports of premature thelarche and high serum prolactin levels in a 15 month old girl with SLOS,<sup>90</sup> and a malignant germ cell tumour with a contralateral streak gonad in another female.<sup>91</sup> Menstrual function is often irregular but otherwise normal in most SLOS adolescent females and adults, although menarche is often delayed. One adolescent girl with (biochemically unproven) SLOS and borderline intelligence gave birth to an apparently normal daughter.<sup>34</sup>

#### CARDIOVASCULAR ANOMALIES

The cardiac anomalies of SLOS have been reviewed by Robinson *et al.*,<sup>7</sup> Johnson,<sup>10</sup> and, most extensively, by Lin *et al.*<sup>92</sup> Almost half of SLOS patients have a congenital heart defect, although if only biochemically confirmed patients are taken into consideration, this percentage is somewhat lower.<sup>23 27 92</sup> There is a strong predominance of endocardial cushion defects and the hypoplastic left heart sequence, whereas conotruncal defects are uncommon. Almost every known cardiac defect has been described at least once. The five most prevalent defects found in a study of 95 biochemically confirmed cases of SLOS were atrioventricular canal (25%), primum atrial septal defect (20%), patent ductus arteriosus at term (18%), and membranous ventricular septal defect (10%).<sup>92</sup> Lin *et al.*<sup>92</sup> hypothesised that the abnormal development of the extracellular matrix may be the cause of both the cardiac defects and the absence of ganglion cells in the bowel (Hirschsprung disease) because of altered cell membranes and cell to cell interactions. However, abnormal migration or proliferation of neural crest derived cells, which contributes substantially to the endocardial cushions, could also explain both the cardiac defects and abnormal intestinal ganglion cells. In addition to structural heart defects, there is a substantially increased frequency of pulmonary hypertension in the newborn period and persistent hypertension postnatally, but limited largely to patients with especially

low cholesterol levels, possibly related to the abnormal steroid metabolism of these patients.<sup>69 71 72 93</sup>

#### RENAL AND ADRENAL ANOMALIES

About one quarter of patients with biochemically confirmed SLOS have renal anomalies,<sup>13 27 94</sup> most commonly renal hypoplasia or aplasia,<sup>10 12 13 27 55 94 95</sup> renal cortical cysts,<sup>9 12 27 44 57</sup> hydronephrosis,<sup>9 10 27 44 60 67 72</sup> renal ectopia,<sup>1 9-31 44 57 67 72 79</sup> ureteral duplication,<sup>31 60</sup> and persistent fetal lobation.<sup>15 27 31 79</sup> A number of cases with the oligohydramnios sequence caused by bilateral renal aplasia or other renal causes of severely diminished urinary output have been described.<sup>12 13 55 82 95</sup> The bladder and ureters may be hypoplastic, probably secondary to renal hypoplasia or aplasia.

Both adrenal hyperplasia<sup>12 17</sup> and adrenal hypoplasia<sup>13</sup> have been reported in SLOS, but the growth and shape of the adrenals appear to be normal in most.<sup>13 29</sup> Histological studies of hyperplastic SLOS adrenal glands<sup>17</sup> typically show deficient cortical lipid, where normally fetal adrenals contain much cholesterol. Post-natal studies of adrenal function in children with SLOS have shown either normal function<sup>73</sup> or, in several biochemically severely affected children, decreased steroid synthesis.<sup>96</sup>

#### PULMONARY ANOMALIES

Abnormal pulmonary lobation and pulmonary hypoplasia are common in the more severely affected cases of SLOS.<sup>9 12 13 31 51 53 82</sup> As expected, pulmonary hypoplasia is also common in SLOS patients with the oligohydramnios sequence secondary to renal aplasia.<sup>12 13 55 82</sup> Accessory pulmonary arteries have also been described.<sup>45</sup> Anomalies of the laryngeal and tracheal cartilages are common even among patients with mild forms of SLOS and may cause obstructive sleep apnoea. Serious complications have resulted from difficulties with emergent and even elective intubation because of marked tracheal narrowing and other abnormalities of the laryngeal and tracheal structures.<sup>69</sup>

#### GASTROINTESTINAL ANOMALIES

Pyloric stenosis is a prominent clinical problem noted in the original description of SLOS and in many subsequent case reports.<sup>1 2 7 97</sup> Pyloric stenosis in SLOS has the same clinical and anatomical characteristics as in otherwise normal children, but vomiting and other feeding problems commonly persist after surgical repair, in part because of apparent intrinsic abnormalities of intestinal motility. In the more severe cases, intestinal aganglionosis occurs, both short segment and more extensive involvement of the upper and lower intestinal tract.<sup>12 87 98 99</sup> Even among SLOS patients lacking histological evidence of intestinal aganglionosis, intestinal dysmotility is common, especially in the first year. However, whereas pyloric stenosis historically has been reported in at least 10% of SLOS patients, it is now uncommon in SLOS patients treated with supplementary cholesterol starting shortly after birth (Kelley, unpublished data).

A small number of SLOS patients have had the unusual finding of dysplasia or aplasia of the gall bladder,<sup>12 27</sup> or gallstones in infancy or later childhood.<sup>12 69</sup> More common, however, is transient or, more rarely, lethal cholestatic liver disease.<sup>12 27 67 100</sup> Histologically, iron pigment in liver cells has been found to be increased,<sup>51 67</sup> as is also seen in peroxisomal disorders. Although lipidosis is not commonly associated with SLOS, diffuse lipid storage was reported by Parnes *et al*,<sup>74</sup> and Porter *et al*<sup>101</sup> recently described impaired intracellular trafficking of LDL in SLOS fibroblasts.

Pancreatic islet cell hyperplasia has been reported frequently in severe SLOS.<sup>9 12 17 31 65</sup> The histology in these cases features nesidioblastosis and reduced quantities of somatostatin.<sup>17 102</sup> Other abdominal malformations less frequently reported include intestinal malrotations,<sup>9 12 27 45 84</sup> absence of the diaphragm or diaphragmatic hernia,<sup>9 55</sup> polysplenia and asplenia,<sup>9</sup> anal stenosis or atresia,<sup>9 13 52 65 103</sup> and Meckel's diverticulum.<sup>2 7</sup>

#### OTHER ANOMALIES AND CLINICAL PROBLEMS

Involuted<sup>67</sup> and hypoplastic<sup>99</sup> thymus and absent parathyroids<sup>12</sup> have been found. Among the more common dermatological and hair abnormalities are hypopigmented hair,<sup>2 78</sup> mild to extreme skin photosensitivity in more than half of patients,<sup>27</sup> hyperhidrosis of the palms,<sup>104</sup> marked cutis marmorata,<sup>99</sup> and eczema.<sup>27</sup> After infancy, many children have mild to marked acrocyanosis that appears to be autonomic in nature and often resolves after cholesterol therapy. Widely spaced nipples are mentioned repeatedly, but measurements are rarely provided. There are two reports of excessive muscle rigidity after halothane anaesthesia, but diagnostically raised creatine kinase levels were not found.<sup>105 106</sup>

#### Natural history

The neonatal period and infancy of SLOS patients are almost invariably disturbed by feeding problems, including poor or abnormal suck, swallowing difficulties, vomiting, and lack of interest in feeds. Oral tactile defensiveness and failure of progression to textured foods in later months is also characteristic of the SLOS infant. As a result, more than 50% of patients require nasogastric tube feedings, often progressing to gastrostomy feeding for several years. As expected, patients with a cleft palate and a small mandible (Pierre Robin sequence) have the most severe feeding problems. Although gastro-oesophageal reflux is a common problem in patients with SLOS, such reflux is often caused by a failure to recognise that the children have congenitally small stomachs and intestinal dysmotility. In addition, gastro-oesophageal reflux secondary to milk or soy protein allergy seems to be unusually common in children with SLOS. Pyloric stenosis is also frequent in SLOS as shown by Lin *et al*,<sup>92</sup> who found that pyloric stenosis occurred in at least 7% of their biochemically confirmed cases and 11% of published cases. With early recognition of these causes of gastro-oesophageal reflux

and vomiting in SLOS, funduplications and other surgical interventions can be minimised.

Severe hypotonia is almost universal in SLOS during infancy. Although the hypotonia is partly central in origin, congenital muscle hypoplasia also contributes to the hypotonia. However, during the second year, muscle mass and tone often improve, and muscle strength and tone are typically normal in older children with SLOS. In later childhood, increased muscle tone may occur and can lead to joint and skeletal problems in non-ambulatory children. Such hypertonia appears to be extrapyramidal rather than spastic.

“Failure to thrive” is also almost universally diagnosed in children with SLOS, but the diagnosis more often than not is incorrect. Infants with SLOS are small for gestational age and most continue to grow below the 3rd centile despite adequate caloric intake, indicating a fundamental, genetic hypotrophy as the basis of the growth retardation. Weight gain can be even poorer in the first two years because of feeding and GI motility problems. Although even well nourished infants will experience a fall off from their birth centiles over the first year, most children with SLOS have normal growth velocities for length and weight in later years. Similarly, although head circumference is proportionately the smallest measurement at birth and postnatally, head circumference also usually remains proportionate with other measurements. Most measurements for classical SLOS fall between  $-1$  and  $-5$  SD below normal, but measurements as low as  $-8$  to  $-10$  SD occur in the more severely affected patients. With a few exceptions at both extremes, final adult height and head circumference are between 2 and 5 SD below normal.<sup>12 13 27 107</sup> In several published series, final height in adults with “type I” SLOS was between 143 and 170 cm.<sup>27 48 59</sup> Size at birth and growth of the biochemically more severely affected patients is substantially less.

During both infancy and childhood, children with SLOS appear to have an increased number of infections. Although many of the infections are otitis media, skin infections and pneumonias also seem to occur more often. Despite the frequency of reflux and hypotonia in children with SLOS, aspiration pneumonia is surprisingly uncommon, most probably because of the children’s exaggerated gag reflex. Except for a single report of abnormal monocyte oxidative metabolism,<sup>108</sup> no specific primary immune disturbances have been described in SLOS. However, death from sudden overwhelming infections is not rare in SLOS and suggests a fundamental abnormality in immune defenses or, possibly, adrenal function.<sup>96</sup> Apart from the high frequency of milk and soya protein allergy<sup>71</sup> and, possibly, an increased frequency of reactive airway disease, other primary immunological diseases do not seem to be common in SLOS.

#### MENTAL DEVELOPMENT AND BEHAVIOUR

With rare exceptions, global psychomotor retardation is characteristic of SLOS. Although, historically, most patients have been

described as severely mentally retarded (IQ 20 to 40), such apparently poor development in part reflected difficulties in testing. In general, SLOS children are very sociable, have much better receptive than expressive language, and may be surprisingly mechanically adept for their apparent degree of cognitive impairment. Because of their poor expressive language and hyperactivity, routine developmental testing often underestimates their cognitive abilities. Gross motor development is typically more severely delayed than fine motor development, but most children with classical SLOS learn to walk between 2 and 4 years. With the availability of biochemical testing and the more frequent recognition of more mildly affected SLOS children, the known developmental spectrum of SLOS has widened substantially. Approximately 10% of children with biochemically diagnosed SLOS have development in the mildly retarded range (IQ 50 to 70). A few patients with normal or borderline normal development have been described,<sup>27 34</sup> and it is likely that the proportion of recognised patients with borderline and normal intelligence will increase.

In the newborn period, excessive sleeping and poor responsiveness are common. However, hours of shrill screeching or inconsolable screaming, especially at night and in the early morning hours, is a major behavioural characteristic of untreated SLOS later in infancy.<sup>10 27</sup> Others appear hypersensitive to all visual and auditory stimuli and must be kept in quiet, dark rooms. Ryan *et al.*<sup>27</sup> drew attention to the strikingly diminished amount of sleep in early childhood, which they found in 70% of their patients, some of whom slept for only two or three hours at night. Although this abnormal sleeping pattern may improve with age, adult SLOS patients with similar sleep problems are known. Many patients, even those with very mild clinical disease, may show self-injurious and aggressive behaviour. Most characteristic among these behaviours over the age of 3 years are forceful hyperarching (what we have called “opisthokinesis”), with or without head banging, and arm and hand biting. Marked tactile hypersensitivity of the hands and feet is also seen in more than 50% of patients. Behavioural characteristics of autism, such as hand flapping, abnormal obsessions, insistence on routine, and poor visual contact, are common in children with SLOS. Despite these many behavioural problems, most parents describe their children often as loving, affectionate, and happy.<sup>2 27</sup>

#### LIFE EXPECTANCY

Some investigators have suggested that there is an increased rate of spontaneous abortion in families with SLOS, but Ryan *et al.*<sup>27</sup> in the only systematic study of prenatal losses, found 39 probands, 51 healthy sibs, 16 spontaneous abortions, and seven elective terminations among 43 sibships with 113 known conceptions. Furthermore, Kratz and Kelley<sup>95</sup> found no increased recognised miscarriage rate and an expected segregation ratio of 25% in a cohort of prospectively monitored pregnancies.

Although these data do not support the hypothesis of an increased miscarriage rate,<sup>10 109 110</sup> it may still occur in families with more severely affected children, since severe cardiac or renal abnormalities have been known to lead to mid-trimester intrauterine death of SLOS fetuses. As supported by the data of Cunniff *et al*, the low 17% segregation ratio found in one large series<sup>10</sup> could be explained by the inclusion of a proportion of genetically different disorders at a time when biochemical confirmation of the diagnosis was not possible.

There are no recent figures for life expectancy in SLOS. Johnson<sup>10</sup> found that 27% of cases in her series died before 2 years of age. However, an analysis of the causes of death was not provided. As ascertainment of SLOS, even in the era of biochemical diagnosis, has been incomplete, the exact percentage of cases with early lethality remains uncertain. Clearly, however, life expectancy in SLOS is determined largely by the severity of the internal malformations and the quality of general supportive care and not by an intrinsic degenerative process or biochemical toxicity per se.

#### Differential diagnosis

Many papers describe patients with a clinical phenotype resembling SLOS, especially before the era of biochemical diagnosis. In German publications the designations "Ullrich-Feichtiger syndrome"<sup>111</sup> or "Typus Rostockien-sis",<sup>112</sup> a multiple congenital anomalies syndrome with facial anomalies, polydactyly, and hypospadias, probably describe severe forms of SLOS.<sup>113</sup> Among clinical diagnoses that have been proven or suspected to be cases of SLOS are the acrodysgenital syndrome,<sup>31 85 114</sup> Gardner-Silengo-Wachtel syndrome (OMIM 231060),<sup>115 116</sup> and holoprosencephaly-polydactyly ("pseudotrisonomy 13") syndrome (OMIM 264480).<sup>117 118</sup> However, the predominance in the Gardner-Silengo-Wachtel syndrome of conotruncal malformations and in holoprosencephaly-polydactyly syndrome of gonadal dysgenesis, both uncommon abnormalities in SLOS, suggests that some of these biochemically untested patients do not have SLOS. Among diagnoses that have been incorrectly assigned to patients with SLOS are Noonan syndrome (OMIM 163950), Opitz syndrome (OMIM 145410, 300000), and Zellweger syndrome (OMIM 214100). Conversely, several patients with  $\alpha$  thalassaemia-mental retardation syndrome (OMIM 301040) have been given the diagnosis of SLOS. Other disorders that resemble SLOS, but less so, are Meckel syndrome (OMIM 249000), hydroletharus syndrome (OMIM 236680), Pallister-Hall syndrome (OMIM 146510), orofaciocigital syndrome type VI (OMIM 277170),<sup>12 15 112 118 119</sup> and a number of individual case reports.<sup>74 120-124</sup>

#### Sterol biosynthesis

Cholesterol is a 27-carbon, mono-unsaturated sterol, synthesised from lanosterol by a series of oxidations, reductions, and demethylations, mostly limited to the endoplasmic reticulum

(fig 2). The markedly increased levels of 7DHC with almost no 7-dehydrodesmosterol in patients with SLOS suggests that the principal route of cholesterol biosynthesis in man may be the Kandutsch-Russell pathway.<sup>21</sup> Nevertheless, the relative abundance of desmosterol in neuronal tissues, the testes, and breast milk<sup>125-127</sup> suggests that desmosterol may be the penultimate sterol in some tissues, or have specific functions in the tissue where it is abundant.

Before discovery as the marker metabolite of SLOS, 7DHC was known as a minor constituent of plasma and solid tissues. It was found to be increased up to three-fold in conditions associated with increased loss of bile acids, for example, ileal resection, and, therefore, increased cholesterol synthesis. 7DHC has special physiological importance as the precursor of vitamin D<sub>3</sub> via photic conversion of 7DHC to pre-vitamin D<sub>3</sub> in skin.

Whereas most of the early steps of cholesterol biosynthesis are well characterised at the DNA, RNA, and protein levels, the individual enzymes, cofactors, carrier proteins, and intracellular transport steps involved in the conversion of lanosterol to cholesterol are less well understood, as is the complex intracellular trafficking of cholesterol. A genetic disruption of one of these transport pathways appears to be the cause of the lipid storage in type C Niemann-Pick disease.<sup>128</sup> Understanding intracellular trafficking and regulation of cholesterol uptake as well as de novo cholesterol synthesis will be important to understanding the cellular pathology of SLOS.

In contrast to many other small metabolites, very little cholesterol is transported after the first trimester from the mother to the fetus. Instead, most cholesterol must be synthesised by the fetus.<sup>129 130</sup> Both in later fetal life and after birth, most if not all cholesterol in the brain is synthesised locally, not transported from blood lipoproteins.<sup>130-133</sup> However, recent molecular biological studies have delineated a system for the delivery of maternal LDL to LDL receptors in the embryonic neuroepithelium in the first trimester.<sup>134 135</sup> The fundamental importance of this system is supported by the discovery<sup>135</sup> that transgenic mice lacking megalin, the LDL receptor in the embryonic neuroepithelium, develop holoprosencephaly, which has been linked to abnormal cholesterol metabolism at several levels.<sup>58 136 137</sup> Thus, whereas delivery of cholesterol to the fetus after development of the placenta may be minimal, critical aspects of embryonic tissue differentiation may be sensitive to maternal blood cholesterol and LDL levels.

Although most cholesterol in tissues serves as a major structural lipid of membranes, some cholesterol also enters pathways for bile acid metabolism and the synthesis of steroid hormones. Another unexpected and recently discovered role of cholesterol is as a covalently bound element of active hedgehog proteins, a family of embryonic signalling proteins.<sup>58 137 138</sup>

Already in 1966, Roux and Aubry<sup>139</sup> had shown that inhibitors of enzymes of the distal cholesterol biosynthetic pathway caused

holoprosencephaly, microcephaly, pituitary agenesis, limb defects, and genital anomalies in the pups of exposed pregnant rats or mice. The same group also showed that feeding cholesterol to the pregnant, treated rats substantially limited or blocked the teratogenic effects of AY-9944, an inhibitor of DHCR7.<sup>140</sup> Before 1993, holoprosencephaly had been reported in only one SLOS patient.<sup>17</sup> However, using an increased 7DHC level as a diagnostic marker for SLOS, holoprosencephaly of variable severity has been found to occur in about 5% of patients with SLOS, most of whom have also been found to have mutations in *DHCR7*.<sup>23 58</sup> This association was soon complemented by the discovery at about the same time<sup>138</sup> that targeted disruption in mice of Sonic hedgehog (*Shh*) causes not only holoprosencephaly, but also distal limb defects and other skeletal anomalies. The same group showed that covalent addition of cholesterol to the equivalent hedgehog protein in *Drosophila*, *hh*, was an essential part of the “autoprocessing” of *hh*,<sup>137 141</sup> wherein precursor *Shh* protein in the

presence of cholesterol cleaves itself into a non-signalling COOH-terminal half and a mature, cholesterol substituted, N-terminal half, “hh-N”. The processed amino half appeared to possess all *hh* signalling activity, which in vertebrates includes patterning of development in the ventral forebrain and limb buds. The hh-N fragment appears to have a role in the attachment and localisation of hh-N to cell membranes.<sup>137</sup> The proteins in vertebrates homologous to *Shh*, Desert hedgehog and Indian hedgehog, appear to have similar roles in, respectively, genital and skeletal development, both important aspects of malformation in SLOS.<sup>142 143</sup> Another link between these malformations and hedgehog proteins was made by Roessler *et al*,<sup>136</sup> who found that heterozygosity for mutations in *SHH*, the 7q36 linked gene encoding SHH in humans, causes autosomal dominant holoprosencephaly.

This convergence of holoprosencephaly, SLOS, *Shh*, and cholesterol metabolism focused attention on the possibility that the covalent attachment of cholesterol to *Shh*-N

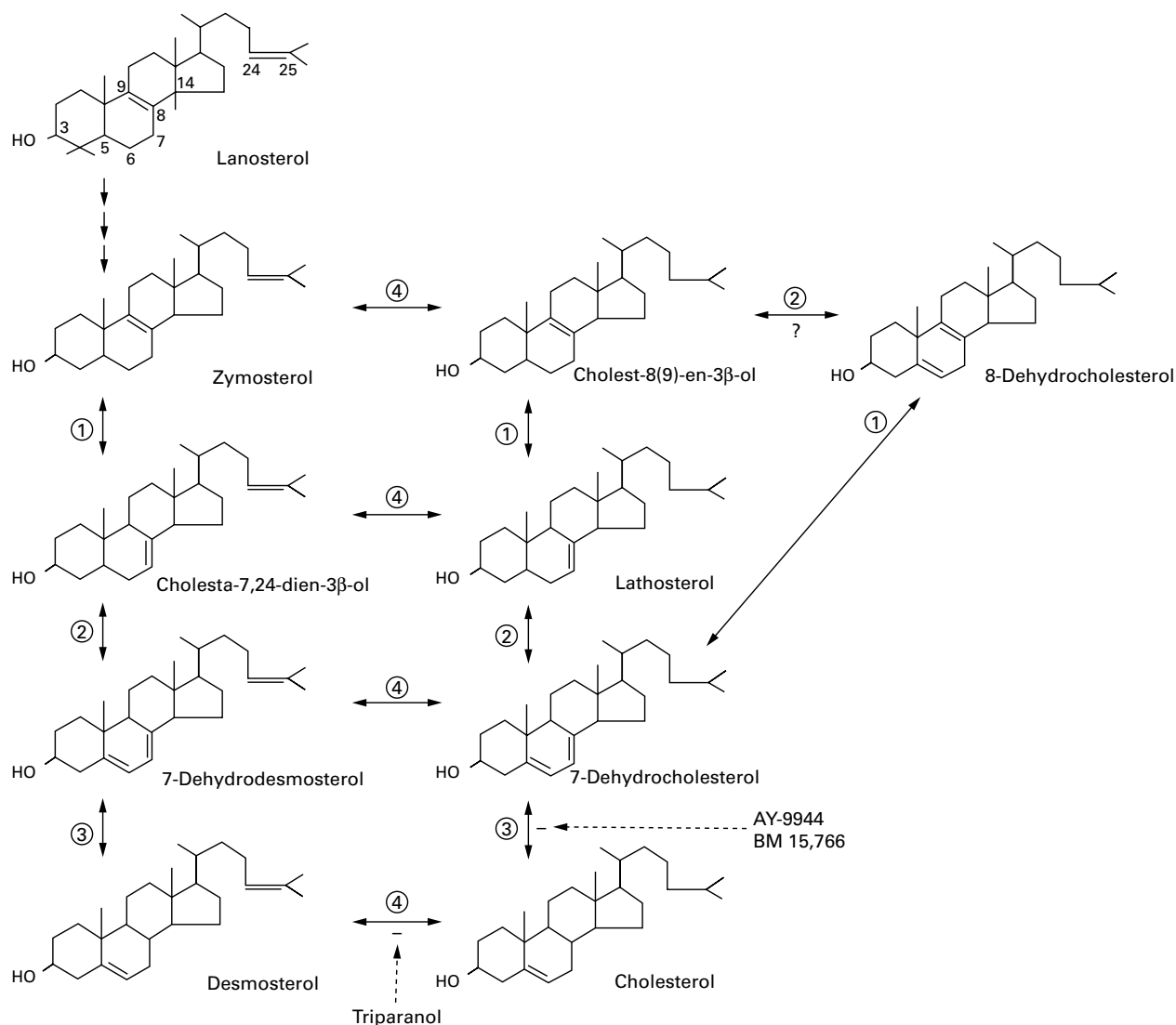


Figure 2 Enzymatic steps and major sterol intermediates comprising the pathway of cholesterol from the first sterol, lanosterol. The denoted enzymatic steps are (1) 3β-hydroxysteroid-Δ8,Δ7-isomerase (EC 5.3.3.5); (2) 3β-hydroxysteroid-Δ5-desaturase (lathosterol dehydrogenase, EC 1.3.3.2); (3) 3β-hydroxysteroid-Δ7-reductase (DHCR7, EC 1.3.1.21); and (4) 3β-hydroxysteroid-Δ24-reductase (desmosterol reductase).



and related hedgehog proteins is the link between the abnormal cholesterol metabolism of SLOS and abnormal morphogenesis in SLOS. However, Cooper *et al.*<sup>144</sup> showed that autoproducting of hedgehog is not impaired when cholesterol in the reaction medium is replaced with 7DHC or any of many other 27-carbon sterols. In vitro studies with AY-9944 and other teratogens that cause SLOS-like malformations in rats strongly suggested that the defect in Shh signalling resides in sterol mediated changes in the target tissue and not an abnormality of the Shh-N signal itself.<sup>144</sup> There are other possible levels at which the sterol defect of SLOS may cause impaired signalling of Shh, such as the sterol sensing domain in Patched,<sup>145</sup> and the lamin B receptor, which has both sterol-14-reductase and a binding site structure similar to that of DHCR7.<sup>24 146</sup> Shh is just one of several similarly functioning hedgehog proteins, all of which may interact with Patched in a sterol sensitive manner. Thus, it is possible that impaired signalling activities of Desert hedgehog<sup>142</sup> and Indian hedgehog<sup>143</sup> also play a role in SLOS in the abnormal morphogenesis of tissues that are not special targets of Shh signalling.

Other less specific disturbances may also contribute to the abnormal morphogenesis of SLOS. Cholesterol is severely deficient in all tissues, and such a severe disturbance in membrane sterol composition may affect developmental processes that involve cell-cell interactions, as suggested by DeHart *et al.*<sup>147</sup> Interestingly, in recent studies with the SLOS mimicking teratogen BM 15 766, Lanoue *et al.*<sup>148</sup> showed that more severe and more characteristic SLOS malformations were produced when BM 15 766 was given to mice with a genetic deficiency of LDL receptors, suggesting that, in embryonic tissue, a deficiency of cholesterol itself does indeed have a contributory role in the abnormal embryologic signalling of SLOS.

Despite the apparent negligible transfer of cholesterol from the mother to the human fetus, the most severely affected SLOS patients have measurable cholesterol levels at birth, typically 5 to 20 mg/dl.<sup>23 131</sup> Moreover, initial rates of cholesterol synthesis in cultured fibroblasts from patients predicted on the basis of their mutations to have no DHCR7 activity may be as high as 50% of all sterols (Kelley, unpublished observations). Thus, there may be another genetic source of DHCR7 activity or a pathway of cholesterol synthesis not requiring DHCR7. The most likely source of such activity is the peroxisome, which has been shown to have an essential role in the early steps of cholesterol biosynthesis.<sup>149-151</sup>

Clinical severity correlates best with the level of cholesterol (inversely) or with 7DHC (or the sum of all dehydrosterols) expressed as a fraction of total sterols.<sup>23</sup> The dehydrosterol fraction better expresses the systemic sterol abnormality than absolute blood sterol levels, which are subject to wide physiological variations independent of the rate of sterol synthesis. SLOS patients with multiple internal anomalies and early death have had, in general,

much lower total sterol levels and higher 7DHC/sterol ratios than surviving SLOS patients.<sup>23 152</sup> Although it was suggested<sup>153</sup> that essentially all SLOS patients with cholesterol levels lower than 10 mg/dl die at birth or in the first few months,<sup>152</sup> death in SLOS is caused largely by specific visceral malformations rather than some biochemical consequences of the abnormal sterol levels. Patients with levels less than 10 mg/dl at diagnosis who are long survivors are not rare and are usually distinguished by a lack of major internal anomalies. The genetic basis of the differences in biochemical and clinical severity is supported by the finding that sibs with SLOS usually have similar plasma levels of 7DHC and cholesterol and similar degrees of clinical severity.<sup>23</sup> Indeed, subsequent studies of *DHCR7* mutations have shown a strong correlation between the predicted enzymatic effect of a patient's particular mutations and the clinical phenotype.<sup>163</sup>

As expected for an autosomal recessive disorder, the parents of SLOS patients have no or minimal physiological signs of abnormal sterol metabolism. About half of the parents are found to have mildly increased plasma 7DHC levels, with a mean level for all parents that is slightly higher than normal.<sup>153</sup> However, more than 90% of SLOS parents have abnormally increased 7DHC to cholesterol ratios when their lymphoblasts are cultured in cholesterol depleted medium.<sup>33</sup> Although there are no obvious adverse clinical consequences of mildly abnormal 7DHC metabolism in heterozygotes, no systematic survey for associated minor anomalies has been performed.

Apart from occasional case studies reporting adrenal or gonadal steroid levels,<sup>17 72 95 154</sup> there have been few studies of steroid metabolism in SLOS. Reports of DHEA levels have shown both abnormally low and high levels, and testosterone levels were found to be either low or normal, with normal to mildly increased levels of FSH and LH in some. However, the anecdotal and usually uncontrolled nature of these studies precludes an informed understanding of sex steroid metabolism in SLOS. Moreover, the high frequency of hypogonadism in SLOS is not sufficient evidence to implicate inadequate steroid production in utero, as the persistence of Mullerian remnants in some SLOS patients<sup>15</sup> suggests defective genital morphogenesis unrelated to steroid hormone levels, possibly mediated through sterol related dysfunction of Desert hedgehog in genital tissues.<sup>155</sup>

### Molecular genetics

The finding of hypocholesterolaemia and markedly increased levels of 7DHC in patients with SLOS immediately focused attention on 7-dehydrocholesterol reductase (DHCR7, EC 1.3.1.21) as a candidate deficient enzyme causing the disorder. Additional evidence came from drugs that inhibit distal steps of cholesterol biosynthesis produced SLOS-like malformations in mice and rats, suggesting that the cholesterol lowering action of these drugs may rather be the principal teratogenic

factor.<sup>147-156-158</sup> Before the renewed interest in *DHCR7* caused by SLOS, *DHCR7* had been little studied at a structural or DNA level, and then mostly in lower organisms.<sup>159</sup> At the time of the discovery of apparent *DHCR7* deficiency in SLOS, the chromosomal location of *DHCR7* was unknown, but 7q32.1 was thought to be the best candidate, because two unrelated SLOS patients were known to have de novo balanced translocations at that position. Further genetic study of one of the biochemically confirmed translocation patients<sup>160</sup> showed that the 7q32.1 breakpoint interrupted not a gene involved in sterol metabolism but the human metabotropic glutamate receptor 8 (*GRM8*), which is not known to have a role in cholesterol biosynthesis. However, Moebius *et al*<sup>24</sup> shortly afterwards reported the cloning and mapping of a human microsomal *DHCR7* gene to chromosomal location 11q12-13. Interestingly, *DHCR7* was first cloned not as a gene for a sterol metabolising enzyme, but as a candidate gene for a “sigma type” drug binding protein.<sup>161</sup> Only after complete sequencing was the gene found to have strong homology with *DHCR7* from *Arabidopsis thaliana*. Within months, three groups identified disabling mutations in *DHCR7* in SLOS patients.<sup>25-26-162</sup>

The 2957 bp cDNA for the human *DHCR7* gene has an open reading frame of 1425 bp, which codes for a protein with 475 amino acid residues and a calculated mass of 54.5 kDa.<sup>24</sup> The gene, which spans 14 kb of genomic DNA, is organised into nine exons and, by hydropathy plot, between six and nine transmembrane alpha helices. In addition to having a high degree of homology with *DHCR7* of *Arabidopsis thaliana*, the human *DHCR7* has substantial homology with genes encoding sterol-delta14-reductases across phyla and with the gene encoding the human lamin B receptor, a nuclear inner membrane protein with intrinsic sterol-delta14-reductase activity but unknown nuclear function or physiological significance.<sup>24-146</sup> Among the 26 alleles studied by Fitzky *et al*,<sup>162</sup> only one example of IVS8-1G>C, a splice site mutation that creates a 134 bp insertion between exons 8 and 9, was found. However, study of a cohort of mostly North American patients with largely European and Hispanic ancestry showed that the

IVS8-1G>C mutation constituted 29% of *DHCR7* mutant alleles, and that several other alleles, R404C (11%), V326L (7%), W151X (8%), and T93M (8%), also occurred at relatively high frequencies.<sup>163</sup> Collectively, the five most common mutations from this study and the Dutch study group (Waterham *et al*, unpublished data) accounted for two-thirds of the mutant alleles (fig 3). Although these high frequencies may have evolved because of a special heterozygote advantage afforded by the particular mutations, more likely is a combination of founder effect and a heterozygote advantage that encouraged the persistence of these several mutations and of diverse missense mutations. As would be predicted in a model of heterozygote advantage, such as increased synthesis of vitamin D by heterozygotes, the most common mutations cause more severe enzymatic defects than the less common mutations. There is as yet no correlation between individual mutations and their effects on the sterol or vitamin D metabolism in heterozygotes. Such information, however, may provide evidence for increased vitamin D levels as a possible heterozygote advantage, since European palaeolithic studies have indicated that rickets was a common paediatric disease. As anticipated from biochemical studies, the most severely affected patients are either homozygotes or compound heterozygotes for mutations shown or predicted to have no or severely reduced *DHCR7* activity.<sup>163</sup> In contrast, most classical “type I” SLOS patients are compound heterozygotes for a severe, truncating mutation and a second missense mutation associated with residual enzyme activity. Most patients with very mild clinical and biochemical phenotypes are compound heterozygotes for two unique or uncommon missense mutations.<sup>163</sup>

### Biochemical diagnosis

#### DIAGNOSTIC METHODS

Because approximately 10% of patients with SLOS have normal serum cholesterol levels at any age, including at birth, a blood cholesterol level is not a reliable screening test for SLOS. Moreover, because 8DHC and 7DHC react as cholesterol in cholesterol oxidase assay methods, hospital laboratories may report a normal “cholesterol” level even when 7DHC and

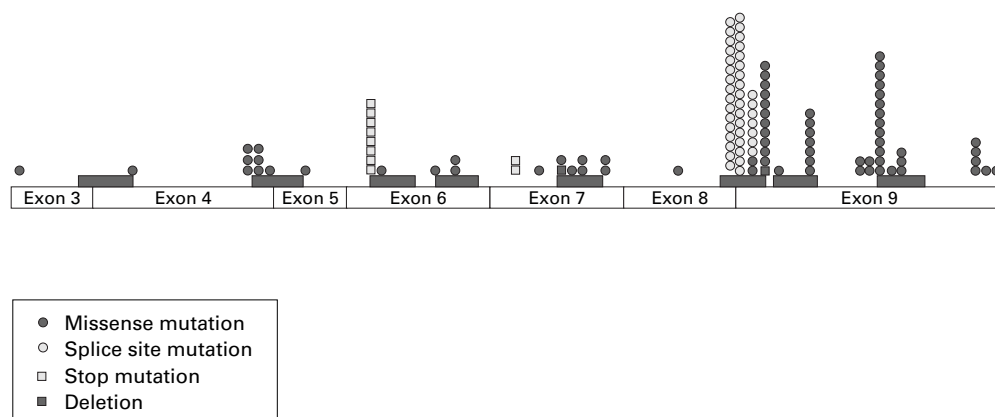


Figure 3 Distribution of 122 SLOS mutations of 3beta-hydroxysteroid-delta7-reductase (*DHCR7*) in 61 patients with Smith-Lemli-Opitz syndrome.

8DHC constitute more than half of the sterols measured. In a few affected children, the level of 7DHC may be normal or equivocally increased, but the 8DHC level is usually mildly but distinctly abnormal. In rare cases where the levels of 7DHC and 8DHC are normal or fall in the heterozygote range, either *DHCR7* mutational testing, *DHCR7* enzymatic assay, or analysis of sterol biosynthesis in cultured cells must be undertaken.<sup>153 164 165</sup> Under conditions of maximal growth stimulation in cholesterol depleted cultured medium, lymphoblasts from the mild biochemical variants of SLOS still develop markedly increased levels of 7DHC.

Not uncommonly, there is a need to make a retrospective biochemical diagnosis of SLOS in a child for whom there may be remaining stored tissue or laboratory samples. Samples commonly used for retrospective biochemical diagnosis of SLOS include archived plasma and serum samples, Guthrie newborn screening cards, frozen or formalin preserved necropsy tissues, and amniotic fluids. Recovering sufficient sterol for diagnosis from formalin preserved tissue stored more than a few months is not assured, but can still be successful. In a 130 year old case from an Anatomical Museum the lowered cholesterol level could be proven.<sup>166</sup> Because 7DHC and 8DHC are oxygen sensitive, diagnostic levels of 7DHC and 8DHC may be lost with storage, but diagnoses using refrigerated Guthrie cards as old as five years have been made.

**OTHER CAUSES OF INCREASED LEVELS OF 7DHC**  
7DHC exists in normal human tissues at a relatively constant ratio to cholesterol. Thus, in common forms of hypercholesterolaemia, such as familial hypercholesterolaemia resulting from abnormalities of LDL metabolism, the absolute level of 7DHC may be increased, but the ratio relative to cholesterol is usually normal. In some other conditions where there is marked upregulation of cholesterol biosynthesis, such as cerebrotendinous xanthomatosis, 7DHC may be increased 10 to 20-fold, but the presence of similarly increased levels of other sterol precursors and cholestanol clearly establish the correct diagnosis. Another cause of mildly increased levels of 7DHC is treatment with haloperidol (Kelley, unpublished observations), which has a high affinity for the *DHCR7* substrate binding site.<sup>24</sup> Because *DHCR7* is a member of the "sigma" class of drug binding proteins,<sup>24</sup> it is likely that other drugs of this class will cause increased levels of 7DHC through inhibition of *DHCR7*. More importantly, however, such drugs may have particularly adverse effects on patients with SLOS, who have already markedly diminished activities of *DHCR7*.

#### PRENATAL DIAGNOSIS

Prenatal diagnosis of SLOS has been accomplished in many pregnancies. As reported by several authors,<sup>13 95 154</sup> one of the early signs of an SLOS fetus is an abnormally low maternal serum level of unconjugated oestriol. Other elements of the triple screen (chorionic gona-

dotrophin and  $\alpha$ -fetoprotein) are also mildly depressed in some SLOS pregnancies. A number of affected fetuses have been identified by the discovery of suggestive fetal abnormalities, such as nuchal oedema, microcephaly, cleft palate, polydactyly, cystic kidneys, ambiguous genitalia, or a 46,XY karyotype in a phenotypically female fetus. Determination of the level of 7DHC in the amniotic fluid is possible, with typically a more than 500-fold increase in affected pregnancies.<sup>95</sup> In some pregnancies, the amniotic fluid level of cholesterol is abnormally low, whereas in others the level is surprisingly normal. Direct analysis of the sterol composition of chorionic villi at 10 weeks is also a reliable method for diagnosis of SLOS, although the relative increase in the 7DHC/cholesterol ratio is not as great as it is in amniotic fluid.<sup>95</sup> The initial experience with more than 100 pregnancies at risk for SLOS has yielded no false negatives and no false positives.<sup>95</sup> Despite the feasibility of prenatal diagnosis by molecular testing of villus tissue or amniocytes, the simplicity and accuracy of biochemical testing obviates the need for molecular analysis except, perhaps, in a rare case with equivocal biochemical results.

#### Management

Until recently, SLOS could only be treated supportively. However, with the recognition and treatment of the deficiency of cholesterol biosynthesis in SLOS, the care of patients has changed substantially. The estimated daily synthetic need for cholesterol during infancy is 30 to 40 mg/kg/day, which decreases to approximately 10 mg/kg/day in adults.<sup>167 168</sup> This daily requirement is usually met by a combination of dietary cholesterol and de novo synthesis, balanced in a highly regulated manner. If basic regulation of cholesterol biosynthesis is normal in SLOS children, children with SLOS may be able to absorb sufficient dietary cholesterol to downregulate endogenous sterol synthesis and therefore limit significantly the de novo production of 7DHC. For this reason, children with SLOS routinely have been supplemented with dietary cholesterol with the expectation that blood cholesterol levels will rise to normal at the same time that the abnormal accumulation of 7DHC is eliminated. A complete biochemical "cure" by such therapy would require that dietary cholesterol be distributed to all cellular and tissue compartments. This does not seem to occur, since cholesterol in the central nervous system appears to be synthesised locally and cannot be transported across the blood-brain barrier.<sup>133</sup> Even if cholesterol could reach brain cells and myelin, cognitive performance might not improve, since the mental retardation of SLOS appears to reflect more the embryological micrencephaly and other abnormalities of cerebral neuronal development than an existing deficit of cholesterol or toxic effect of 7DHC.

Initial experimental treatment protocols for SLOS provided 50 mg/kg/day cholesterol, and higher doses up to 300 mg/kg/day, either in natural form (eggs, cream, liver, meats, and

meat based formulas) or as purified food grade cholesterol, with or without supplementary bile acids.<sup>169-171</sup> For substantially growth retarded children, treatment with cholesterol is sometimes followed by striking increases in the rate of growth for several months until more appropriate weight and height centiles are reached. Paradoxically, when SLOS children enter a growth spurt from better nutrition, cholesterol levels typically fall and 7DHC levels rise substantially despite their marked clinical improvement. Although the changes in plasma sterol levels early in a treatment programme usually do not reflect the obvious clinical benefits of cholesterol supplementation, and normalisation of the cholesterol level should not be the ultimate goal in itself, over a period of years all but the most severely affected children usually show a substantial increase in the level of cholesterol and a corresponding fall in the levels of 8DHC and 7DHC. More striking and rapid changes in blood sterol levels were reported in a rat model of SLOS created by treating rats with BM 15 766, a relatively specific inhibitor of DHCR7.<sup>172</sup> The study examined the effects of cholic acid and lovastatin, an HMG-CoA reductase inhibitor, on the blood sterol levels and found that cholic acid had little effect. However, when the rats were given lovastatin plus cholesterol, the anticipated fall in 7DHC levels was prevented rather than enhanced. Thus, because of the lack of definitive evidence that 7DHC is "toxic", and because of the concern that HMG-CoA reductase inhibitors might limit the synthesis of other critical isoprenoid compounds, HMG-CoA reductase inhibitors are not currently used for routine treatment of SLOS. Bile acid supplements have not been included in more recent SLOS treatment protocols. Indeed, because certain bile acids may downregulate tissue levels of LDL receptors, the more rapid rise in plasma cholesterol levels and the persistently high levels of 7DHC in bile acid supplemented patients may reflect impaired tissue uptake of sterols rather than enhanced intestinal absorption of cholesterol.<sup>172</sup> When SLOS children are hospitalised for surgery or acute medical problems and cholesterol cannot be given enterally, cholesterol in the form of LDL containing fresh frozen plasma can have striking beneficial effects, especially for treatment of acute infections and poor wound healing.

In addition to the biochemical and physical changes that follow the initiation of cholesterol replacement therapy, there have also been a number of striking behavioural changes. Upon treatment, irritability and sleep disorders may improve in young children with SLOS within days or weeks, whereas tactile hypersensitivities, especially of the hands and feet, take longer to ameliorate. Typically, all of these behaviours return when cholesterol supplementation is stopped. The behavioural improvement does not appear to correlate with any specific change in the plasma sterol profile, and even children with normal or near normal plasma cholesterol levels may show substantial behavioural improvement when given chole-

sterol supplements. After infancy, many SLOS patients will develop behaviours such as rocking, finger flicking, object twirling, gaze avoidance, and various obsessions, which meet criteria for the diagnosis of autistic disorder and which typically improve or resolve with cholesterol treatment.

A large proportion of patients may require gavage or gastrostomy feeding for many months or years. Funduplications are frequently unsuccessful in treating gastro-oesophageal reflux. In most instances, the reflux is caused not by intrinsically abnormal gastro-oesophageal function, but by protein allergy or by simple overfeeding from ill advised attempts to make SLOS children with primordial dwarfism grow faster. The combination of gastrointestinal protein allergy, intrinsic intestinal dysmotility, and microgastria often make feeding management extremely difficult; feeding with elemental formulas may be required for many months.

An uncommon but sometimes severe nutritional problem in SLOS is idiopathic hypermetabolism, which most often occurs between the ages of 1 and 3 years. SLOS children who develop this unexplained hypermetabolism may require up to 200 kcal/kg/day to maintain body weight. Because of the complicating factors of microgastria and intestinal dysmotility, such children often do not gain weight for many months, but can otherwise remain healthy. Tests for endocrine abnormalities or intestinal malabsorption have been normal in such cases, but signs of hypermetabolism such as warm skin and tachycardia are often noted.

Although many SLOS patients have a severe deficiency of normal bile acids, fat malabsorption and deficiencies of fat soluble vitamins are not common in SLOS, and also clinical evidence of steroid hormone deficiency is surprisingly uncommon.<sup>96</sup> Among these children, the most common finding is a mild to moderate deficiency of aldosterone synthesis, usually manifest as hyponatraemia and hyperkalaemia during the added hormonal stress of an infection. Glucocorticoid response to infection or to administered ACTH can also be subnormal.<sup>96</sup> However, for most SLOS children glucocorticoid production appears to be normal and supplements during infections or perioperatively are probably not needed. Nevertheless, the potential for developing mineralocorticoid and glucocorticoid deficiency postoperatively or during an acute illness must be remembered.

In conclusion, SLOS may now be considered the example par excellence of metabolic dysmorphology. It is well defined biochemically, enzymatically, and molecularly. However, many parts of the pathogenesis, that is, the developmental pathways involved, still remain to be elucidated, and much work has to be done to reach optimal therapeutic regimens. SLOS was the first malformation syndrome in which a cholesterol metabolism disturbance was found. There are now a number of other entities with such a defect, including Conradi-Hunermann syndrome, CHILD syndrome, desmosterolosis, Greenberg dysplasia,

and mevalonic aciduria. Together, these entities constitute a group of metabolic disorders which might be called cholesterolopathies.

- 1 Smith DW, Lemli L, Opitz JM. A newly recognized syndrome of multiple congenital anomalies. *J Pediatr* 1964;64:210-17.
- 2 Opitz JM, Zellweger H, Shannon WR, Ptacek LJ. The RSH syndrome. *Birth Defects* 1969;V(2):43-52.
- 3 Fine RN, Gwinn JL, Young EF. Smith-Lemli-Opitz syndrome. Radiologic and postmortem findings. *Am J Dis Child* 1968;115:483-8.
- 4 Finley SC, Finley WH, Monsky DB. Cataracts in a girl with features of the Smith-Lemli-Opitz syndrome. *J Pediatr* 1969;75:706-7.
- 5 Kaufman R, Alcalá H, Sly H, Hartmann A. Brain malformations in Smith-Lemli-Opitz syndrome. *Am J Hum Genet* 1974;26:47A.
- 6 Cotlier E, Rice P. Cataracts in the Smith-Lemli-Opitz syndrome. *Am J Ophthalmol* 1971;72:955-9.
- 7 Robinson CD, Perry LW, Barlee A, Mella GW. Smith-Lemli-Opitz syndrome with cardiovascular abnormality. *Pediatrics* 1971;47:844-7.
- 8 Dallaire L. Syndrome of retardation with urogenital and skeletal anomalies (Smith-Lemli-Opitz syndrome): clinical features and mode of inheritance. *J Med Genet* 1969;6:113-20.
- 9 Cherstvoy ED, Lazjuk GI, Lurie IW, Nedzved MK, Usoev SS. The pathological anatomy of the Smith-Lemli-Opitz syndrome. *Clin Genet* 1975;7:382-7.
- 10 Johnson VP. Smith-Lemli-Opitz syndrome: review and report of two affected siblings. *Z Kinderheilkd* 1975;119:221-34.
- 11 Gold JD, Pfaffenbach DD. Ocular abnormalities in the Smith-Lemli-Opitz syndrome. *J Pediatr Ophthalmol* 1975;12:228-34.
- 12 Curry CJ, Carey JC, Holland JS, et al. Smith-Lemli-Opitz syndrome-type II: multiple congenital anomalies with male pseudohermaphroditism and frequent early lethality. *Am J Med Genet* 1987;26:45-57.
- 13 Donnai D, Young ID, Owen WG, Clark SA, Miller PF, Knox WF. The lethal multiple congenital anomaly syndrome of polydactyly, sex reversal, renal hypoplasia, and unilobular lungs. *J Med Genet* 1986;23:64-71.
- 14 Scarbrough PR, Huddleston K, Finley SC. An additional case of Smith-Lemli-Opitz syndrome in a 46,XY infant with female external genitalia. *J Med Genet* 1986;23:174-5.
- 15 Bialer MG, Penchaszadeh VB, Kahn E, Libes R, Krigsman G, Lesser ML. Female external genitalia and müllerian duct derivatives in a 46,XY infant with the Smith-Lemli-Opitz syndrome. *Am J Med Genet* 1987;28:723-31.
- 16 Belmont JW, Hawkins E, Hejtmancik JF, Greenberg F. Two cases of severe lethal Smith-Lemli-Opitz syndrome. *Am J Med Genet* 1987;26:65-7.
- 17 McKeever PA, Young ID. Smith-Lemli-Opitz syndrome II: a disorder of the fetal adrenals? *J Med Genet* 1990;27:465-6.
- 18 Chasalow FI, Blethen SL, Taysi K. Possible abnormalities of steroid secretion in children with Smith-Lemli-Opitz syndrome and their parents. *Steroids* 1985;46:827-43.
- 19 Natowicz MR, Evans JE. Abnormal bile acids in the Smith-Lemli-Opitz syndrome. *Am J Med Genet* 1994;50:364-7.
- 20 Irons M, Elias ER, Salen G, Tint GS, Batta AK. Defective cholesterol biosynthesis in Smith-Lemli-Opitz syndrome. *Lancet* 1993;341:1414.
- 21 Kandutsch AA, Russell AE. Preputial gland tumor sterols. III. A metabolic pathway from lanosterol to cholesterol. *J Biol Chem* 1960;235:2256-61.
- 22 Tint GS, Irons M, Elias ER, et al. Defective cholesterol biosynthesis associated with the Smith-Lemli-Opitz syndrome. *N Engl J Med* 1994;330:107-13.
- 23 Cunniff C, Kratz LE, Moser A, Natowicz MR, Kelley RI. Clinical and biochemical spectrum of patients with RSH/Smith-Lemli-Opitz syndrome and abnormal cholesterol metabolism. *Am J Med Genet* 1997;68:263-9.
- 24 Moebius FF, Fitzky BU, Lee JN, Paik YK, Glossmann H. Molecular cloning and expression of the human delta7-sterol reductase. *Proc Natl Acad Sci USA* 1998;95:1899-902.
- 25 Wassif CA, Maslen C, Kachilele-Linjewile S, et al. Mutations in the human sterol delta7-reductase gene at 11q12-13 cause Smith-Lemli-Opitz syndrome. *Am J Hum Genet* 1998;63:55-9.
- 26 Waterham HR, Wijburg FA, Hennekam RCM, et al. Smith-Lemli-Opitz syndrome is caused by mutations in the 7-dehydrocholesterol reductase gene. *Am J Hum Genet* 1998;63:329-38.
- 27 Ryan AK, Bartlett K, Clayton P, et al. Smith-Lemli-Opitz syndrome: a variable clinical and biochemical phenotype. *J Med Genet* 1998;35:558-65.
- 28 Bene M, Duca D, Ioan D, Maximilian C. The Smith-Lemli-Opitz syndrome: ten new observations. *Acta Med Auxol* 1980;12:5-15.
- 29 Krajewska-Walasek M, Gradowska W, Ryzko J, et al. Further delineation of the classical Smith-Lemli-Opitz syndrome phenotype at different patient ages: clinical and biochemical studies. *Clin Dysmorphol* 1999;8:29-40.
- 30 Cruveiller J, Msika S, Lafourcade J. Nanisme de Smith-Lemli-Opitz: a propos de quatre observations. Revue de la littérature. *Sem Hop (France)* 1977;53:843-51.
- 31 Le Merrer M, Briard ML, Girard S, Mulliez N, Moraine C, Inibert MC. Lethal acro dysgenital dwarfism: a severe lethal condition resembling Smith-Lemli-Opitz syndrome. *J Med Genet* 1988;25:88-95.
- 32 Meinecke P, Blunck W, Rodewald A. Smith-Lemli-Opitz syndrome. *Am J Med Genet* 1987;28:735-9.
- 33 Anderson AJ, Stephan MJ, Walker WO, Kelley RI. Variant RSH/Smith-Lemli-Opitz syndrome with atypical sterol metabolism. *Am J Med Genet* 1998;78:413-18.
- 34 Lowry RB, Yong SL. Borderline normal intelligence in the Smith-Lemli-Opitz (RSH) syndrome. *Am J Med Genet* 1980;5:137-43.
- 35 Kelley RI. Editorial. A new face for an old syndrome. *Am J Med Genet* 1997;68:251-6.
- 36 Tsukahara M, Fujisawa K, Yamamoto K, et al. Smith-Lemli-Opitz syndrome in Japan. *Am J Med Genet* 1998;75:118-19.
- 37 Hanissian AS, Summitt RL. Smith-Lemli-Opitz syndrome in a negro child. *J Pediatr* 1969;74:303-5.
- 38 Verma IC, Ghai OP. Smith-Lemli-Opitz syndrome in an Indian child. *Indian J Pediatr* 1971;8:221-2.
- 39 Tomaraei SN, Sarkar B, Bansali A, Marwaha RK. Smith-Lemli-Opitz syndrome. *Indian J Pediatr* 1993;60:143-5.
- 40 Iros JE, Sanchez GH. Smith-Lemli-Opitz syndrome. *Arch Arg Pediatr* 1970;68:23-8.
- 41 Nowaczyk MJ, Whelan DT, Hill RE. Smith-Lemli-Opitz syndrome: phenotypic extreme with minimal clinical findings. *Am J Med Genet* 1998;78:419-23.
- 42 Gold JD, Pfaffenbach DD. Ocular abnormalities in the Smith-Lemli-Opitz syndrome. *J Pediatr Ophthalmol* 1975;12:228-34.
- 43 Harbin RL, Katz JI, Frias JL, Rabinowicz IM, Kaufman HE. Sclerocornea associated with the Smith-Lemli-Opitz syndrome. *Am J Ophthalmol* 1977;84:72-3.
- 44 Fierro M, Martinez AJ, Harbison JW, Hay SH. Smith-Lemli-Opitz syndrome: neuropathological and ophthalmological observations. *Dev Med Child Neurol* 1977;19:57-62.
- 45 Kretzer FL, Hittner HM, Mehta RS. Ocular manifestations of the Smith-Lemli-Opitz syndrome. *Arch Ophthalmol* 1981;99:2000-6.
- 46 Bardelli AM, Lasorella G, Barberi L, Vanni M. Ocular manifestations in Knies syndrome, Smith-Lemli-Opitz syndrome, Hallermann-Streif-Francois syndrome, Rubinstein-Taybi syndrome and median cleft face syndrome. *Ophthalmol Paediatr Genet* 1985;6:343-7.
- 47 Fagerstrom CL, Chitayat D, Kalousek DK, Rootman J, Taylor GP, Hall JG. Unique eye anomaly and features of Smith-Lemli-Opitz (SLO) syndrome in de novo t(1;2)(p22;q23). *Am J Hum Genet Suppl* 1987;39:A57.
- 48 Pauli RM, Williams MS, Josephson KD, Tint GS. Smith-Lemli-Opitz syndrome: thirty-year follow-up of "S" of "RSH" syndrome. *Am J Med Genet* 1997;68:260-2.
- 49 Freedman RA, Baum JL. Postlenticular membrane associated with Smith-Lemli-Opitz syndrome. *Am J Ophthalmol* 1979;87:675-7.
- 50 Gracia R, Nieto JA, Nistal M, et al. Asociación de aniridia con tumor embrionario no renal (gonadoblastoma) en niño con síndrome de Smith-Lemli-Opitz. *An Esp Pediatr* 1976;9:19-24.
- 51 Kohler HG. Brief clinical report: familial neonatally lethal syndrome of hypoplastic left heart, absent pulmonary lobation, polydactyly, and talipes, probably Smith-Lemli-Opitz (RSH) syndrome. *Am J Med Genet* 1983;14:423-8.
- 52 Chakanovskis JE, Sutherland GR. The Smith-Lemli-Opitz syndrome in a profoundly retarded epileptic boy. *J Ment Defic* 1971;15:153-62.
- 53 Rutledge JC, Friedman JM, Harrod MJ, et al. A "new" lethal multiple congenital anomaly syndrome: joint contractures, cerebellar hypoplasia, renal hypoplasia, urogenital anomalies, tongue cysts, shortness of limbs, eye abnormalities, defects of the heart, gallbladder agenesis, and ear malformations. *Am J Med Genet* 1984;19:255-64.
- 54 Fried K, Fraser WI. Smith-Lemli-Opitz syndrome in an adult. *J Ment Defic Res* 1972;16:30-4.
- 55 Stewart FJ, Nevin NC, Dornan JC. Prenatal diagnosis of Smith-Lemli-Opitz syndrome. *Am J Med Genet* 1995;56:286-7.
- 56 Worthington S, Goldblatt J. Smith-Lemli-Opitz syndrome: further delineation of the phenotype. *Clin Dysmorphol* 1997;6:263-6.
- 57 Berry R, Wilson H, Robinson J, et al. Apparent Smith-Lemli-Opitz syndrome and Miller-Dieker syndrome in a family with segregating translocation t(7;17)(q34;p13.1). *Am J Med Genet* 1989;34:358-65.
- 58 Kelley RL, Roessler E, Hennekam RCM, et al. Holoprosencephaly in RSH/Smith-Lemli-Opitz syndrome: does abnormal cholesterol metabolism affect the function of Sonic Hedgehog? *Am J Med Genet* 1996;66:478-84.
- 59 de Die-Smulders C, Frys JP. Smith-Lemli-Opitz syndrome: the changing phenotype with age. *Genet Couns* 1992;3:77-82.
- 60 Joseph DB, Uehling DT, Gilbert E, Laxova R. Genitourinary abnormalities associated with the Smith-Lemli-Opitz syndrome. *J Urol* 1987;137:719-21.
- 61 Hyett JA, Clayton PT, Moscoso G, Nicolaidis KH. Increased first trimester nuchal translucency as a prenatal manifestation of Smith-Lemli-Opitz syndrome. *Am J Med Genet* 1995;58:374-6.
- 62 Garcia CA, McGarry PA, Voirol M, Duncan C. Neurological involvement in the Smith-Lemli-Opitz syndrome: clinical and neuropathological findings. *Dev Med Child Neurol* 1973;15:48-55.

- 63 Chervostoy ED, Lazjuk GI, Ostrowskaya TI, et al. The Smith-Lemli-Opitz syndrome. A detailed pathological study as a clue to an etiological heterogeneity. *Virchows Arch C Pathol Anat Histopathol* 1984;404:413-25.
- 64 Marion RW, Alvarez LA, Marans ZS, Lantos G, Chitayat D. Computed tomography of the brain in the Smith-Lemli-Opitz syndrome. *J Child Neurol* 1987;2:198-200.
- 65 Dallaire L, Fraser FC. The Smith-Lemli-Opitz syndrome of retardation, urogenital and skeletal anomalies in siblings. *Birth Defects* 1969;V(2):180-2.
- 66 Zucker JM, Job JC, Rossier A. A new variety of dystrophic intra-uterine nanism: Smith-Lemli-Opitz syndrome. *Ann Pediatr* 1967;14:2409-11.
- 67 Ness GC, Lopez D, Borrego O, Gilbert-Barnes E. Increased expression of low-density lipoprotein receptors in a Smith-Lemli-Opitz infant with elevated bilirubin levels. *Am J Med Genet* 1997;68:294-9.
- 68 Herman TE, Siegel MJ, Lee BC, Dowton SB. Smith-Lemli-Opitz syndrome type II: report of a case with additional radiographic findings. *Pediatr Radiol* 1993;23:37-40.
- 69 Nwokoro NA, Mulvihill JJ. Cholesterol and bile acid replacement therapy in children and adults with Smith-Lemli-Opitz (SLO/RSH) syndrome. *Am J Med Genet* 1997;68:315-21.
- 70 de Jong G, Kirby PA, Muller LM. RSH (Smith-Lemli-Opitz) syndrome: "severe" phenotype with ectrodactyly. *Am J Med Genet* 1998;75:283-7.
- 71 Irons M, Elias ER, Tint GS, et al. Abnormal cholesterol metabolism in the Smith-Lemli-Opitz syndrome: report of clinical and biochemical findings in four patients and treatment in one patient. *Am J Med Genet* 1994;50:347-52.
- 72 Rossiter JP, Hofman KJ, Kelley RI. Smith-Lemli-Opitz syndrome: prenatal diagnosis by quantification of cholesterol precursors in amniotic fluid. *Am J Med Genet* 1995;56:272-5.
- 73 Pankau R, Partsch CJ, Funda J, Sippell WG. Hypothalamic-pituitary-gonadal function in two infants with Smith-Lemli-Opitz syndrome. *Am J Med Genet* 1992;43:513-16.
- 74 Parnes S, Hunter AG, Jimenez C, Carpenter BF, MacDonald I. Apparent Smith-Lemli-Opitz syndrome in a child with a previously undescribed form of mucopolidiosis not involving the neurons. *Am J Med Genet* 1990;35:397-405.
- 75 Itokazu N, Ohba K, Sonoda T, Ohdo S. Infantile spasms in monozygotic twins with Smith-Lemli-Opitz syndrome type 1. *No to Hattatsu* 1992;24:485-90.
- 76 Deaton JG, Mendoza LO. Smith-Lemli-Opitz syndrome in a 23-year-old man. *Arch Intern Med* 1973;132:422-3.
- 77 Pinsky L, DiGeorge AM. A familial syndrome of facial and skeletal anomalies associated with genital abnormality in the male and normal genitals in the female. *J Pediatr* 1965;66:1049-54.
- 78 Kenis H, Hustinx TW. A familial syndrome of mental retardation in association with multiple congenital anomalies resembling the syndrome of Smith-Lemli-Opitz. *Maand-schr Kindergeneeskd* 1967;35:37-48.
- 79 Pierquin G, Peeters P, Roels F, et al. Severe Smith-Lemli-Opitz syndrome with prolonged survival and lipid abnormalities. *Am J Med Genet* 1995;56:276-80.
- 80 Singer LP, Marion RW, Li JK. Limb deficiency in an infant with Smith-Lemli-Opitz syndrome. *Am J Med Genet* 1989;32:380-3.
- 81 Ruvalcaba RHA, Reichert A, Smith DW. Smith-Lemli-Opitz syndrome. Case report. *Arch Dis Child* 1968;43:620-3.
- 82 Seller MJ, Russell J, Tint GS. Unusual case of Smith-Lemli-Opitz syndrome "type II". *Am J Med Genet* 1995;56:265-8.
- 83 Nevo S, Benderly A, Levy J, Katznelson MB. Smith-Lemli-Opitz syndrome in an inbred family. *Am J Dis Child* 1972;124:431-3.
- 84 McCaughran JM, Clayton PT, Mills KA, Rimmer S, Moore L, Donnai D. Prenatal diagnosis of Smith-Lemli-Opitz syndrome. *Am J Med Genet* 1995;56:269-71.
- 85 Le Merrer M. Acrodysgenital dwarfism or Smith-Lemli-Opitz type II syndrome. *Clin Genet* 1991;40:252.
- 86 Retbi JM, Limal JM, Boutignon H, Rosenstein-Retbi J, Dayras JC. Smith-Lemli-Opitz syndrome with male pseudohermaphroditism. A case report with endocrinological study. *Ann Pediatr* 1981;28:55-8.
- 87 Wallace M, Zori RT, Alley T, Whidden E, Gray BA, Williams CA. Smith-Lemli-Opitz syndrome in a female with a de novo, balanced translocation involving 7q32: probable disruption of an SLOS gene. *Am J Med Genet* 1994;50:368-74.
- 88 Joseph DB, Uehling DT, Gilbert E, Laxova R. Genitourinary abnormalities associated with the Smith-Lemli-Opitz syndrome. *J Urol* 1987;137:719-21.
- 89 Patterson K, Toomey KE, Chandra RS. Hirschsprung disease in a 46,XY phenotypic infant girl with Smith-Lemli-Opitz syndrome. *J Pediatr* 1983;103:425-7.
- 90 Calvani M, Tirasacchi V, Toscano V, Bellussi A, Fortuna C. Early thelarche and hyperprolactinemia in the Smith-Lemli-Opitz syndrome. *Minerva Pediatr* 1979;31:1721-32.
- 91 Patsner B, Mann WJ, Chumas J. Malignant mixed germ cell tumor of the ovary in a young woman with Smith-Lemli-Opitz syndrome. *Gynecol Oncol* 1989;33:386-8.
- 92 Lin AE, Ardinger HH, Ardinger RH Jr, Cunniff C, Kelley RI. Cardiovascular malformations in Smith-Lemli-Opitz syndrome. *Am J Med Genet* 1997;68:270-8.
- 93 Shackleton CHL, Roitman E, Kelley RI. Neonatal urinary steroids in Smith-Lemli-Opitz syndrome associated with 7-dehydrocholesterol reductase deficiency. *Steroids* 2000;64:481-90.
- 94 Akl KF, Khudr GS, De Kaloustian VM, Najjar SS. The Smith-Lemli-Opitz syndrome. Report of a consanguineous Arab infant with bilateral focal renal dysplasia. *Clin Pediatr* 1977;16:665-8.
- 95 Kratz LE, Kelley RI. Prenatal diagnosis of the RSH/Smith-Lemli-Opitz syndrome. *Am J Med Genet* 1999;82:376-81.
- 96 Andersson HC, Frenzt J, Martinez JE, Tuck-Muller CM, Bellizaire J. Adrenal insufficiency in Smith-Lemli-Opitz syndrome. *Am J Med Genet* 1999;82:382-4.
- 97 Schechter R, Torfs CP, Bateson TF. The epidemiology of infantile hypertrophic pyloric stenosis. *Paediatr Perinat Epidemiol* 1997;11:407-11.
- 98 Kim EH, Boutwell WC. Smith-Lemli-Opitz syndrome associated with Hirschsprung disease, 46,XY female karyotype, and total anomalous pulmonary venous drainage. *J Pediatr* 1985;106:861.
- 99 Zizka J, Maresova J, Kerekes Z, Nozicka Z, Jutnerova V, Balicek P. Intestinal aganglionosis in the Smith-Lemli-Opitz syndrome. *Acta Paediatr Scand* 1983;72:141-3.
- 100 Karsten J, Kosztołanyi G. Smith-Lemli-Opitz syndrome in siblings. *Acta Paediatr Hung* 1992;32:127-34.
- 101 Porter FD, Wassif CA, Tsokos M, Steiner RD. Impaired intracellular LDL cholesterol metabolism in Smith-Lemli-Opitz syndrome fibroblasts. In press.
- 102 Lachman MF, Wright Y, Whiteman DA, Herson V, Greenstein RM. Brief clinical report: a 46,XY phenotypic female with Smith-Lemli-Opitz syndrome. *Clin Genet* 1991;39:136-41.
- 103 Degenhardt F, Muhlhaus K. Delayed bone growth as a sonographic sign in the early detection of Smith-Lemli-Opitz syndrome. *Ztschr Geburtshilfe Perinat* 1988;192:169-72.
- 104 Tzouveleakis G, Antoniadis K, Batma A, Nanas C. Smith-Lemli-Opitz syndrome in female, monozygotic twins. *Clin Genet* 1991;40:229-32.
- 105 Mizushima A, Satoyoshi M. Unusual responses of muscular rigidity and hypothermia to halothane and succinylcholine; a case report of Smith-Lemli-Opitz (SLO) syndrome. *Masui* 1988;37:1118-23.
- 106 Petersen WC, Crouch ER Jr. Anesthesia-induced rigidity, unrelated to succinylcholine, associated with Smith-Lemli-Opitz syndrome and malignant hyperthermia. *Anesth Analg* 1995;80:606-8.
- 107 Nwokoro NA, Kelley RI. Clinical, biochemical, and developmental spectrum of adults with Smith-Lemli-Opitz syndrome. In preparation.
- 108 Zahle Ostergaard G, Nielsen H, Friis B. Defective monocyte oxidative metabolism in a child with Smith-Lemli-Opitz syndrome. *Eur J Pediatr* 1992;151:291-4.
- 109 Opitz JM. RSH/SLO ("Smith-Lemli-Opitz") syndrome: historical, genetic, and developmental considerations. *Am J Med Genet* 1994;50:344-6.
- 110 Opitz JM. The RSH syndrome: paradigmatic metabolic malformation syndrome? In: New MI, ed. *Diagnosis and treatment of the unborn child*. Reddick, FL: Idelson-Gnocchi, 1998:43-55.
- 111 Kunze J. Das Ullrich-Feichtiger-Syndrom. *Arch Kinderheilkd* 1969;179:182-94.
- 112 Hovels O, Mullereisert F. Der "Typhus Rostockiensis" als charakteristisches Kombinationsbild multipler Missbildungen (Polydaktylie, Hypospadie, Kryptorchismus, und Mikrogathie). *Zeitschr Kinderheilkd* 1955;77:454-9.
- 113 Lowry RB, Miller JR, MacLean JR. Micrognathia, polydaktyly, and cleft palate. *J Pediatr* 1968;72:859-61.
- 114 Cormier-Daire V, Wolf C, Munnich A, et al. Abnormal cholesterol biosynthesis in the Smith-Lemli-Opitz and the lethal acrodysgenital syndromes. *Eur J Pediatr* 1996;155:656-9.
- 115 Silengo M, Kaufman RL, Kissane J. A 46,XY infant with uterus, dysgenetic gonads and multiple anomalies. *Human-genetik* 1974;25:65-8.
- 116 Greenberg F, Gresik MV, Carpenter RJ, Law SW, Hoffman LP, Ledbetter DH. The Gardner-Silengo-Wachtel or genito-palato-cardiac syndrome: male pseudohermaphroditism with micrognathia, cleft palate, and conotruncal cardiac defect. *Am J Med Genet* 1987;26:59-64.
- 117 Verloes A, Ayme S, Gambarelli D, et al. Holoprosencephaly-polydaktyly ("pseudotrisomy 13") syndrome: a syndrome with features of hydrothalamus and Smith-Lemli-Opitz syndromes. A collaborative multicentre study. *J Med Genet* 1991;28:297-303.
- 118 Hennekam RCM, van Noort G, de la Fuente AA. Familial holoprosencephaly, heart defects, and polydaktyly. *Am J Med Genet* 1991;41:258-62.
- 119 Verloes A, Gillerot Y, Langhendries JP, Fryns JP, Koulischer L. Variability versus heterogeneity in syndromal hypothalamic hamartoblastoma and related disorders: review and delineation of the cerebro-acro-visceral early lethality (CAVE) multiplex syndrome. *Am J Med Genet* 1992;43:669-77.
- 120 Sanderson DM, Fraser FC. Proptosis, Robin association, clenched hands, and multiple abnormalities. *J Clin Dysmorphol* 1983;1:19-21.
- 121 Ades LC, Clapton WK, Morphett A, Morris LL, Haan EA. Polydaktyly, campomelia, ambiguous genitalia, cystic kidneys, and cerebral malformation in a fetus of consanguineous parents: a new multiple malformation syndrome or a severe form of oral-facial-digital syndrome type IV? *Am J Med Genet* 1984;49:211-17.
- 122 Casamassima AC, Mamunes P, Gladstone IM, Solomon S, Moncure C. A new syndrome with features of the Smith-Lemli-Opitz and Meckel-Gruber syndromes in a sibship with cerebellar defects. *Am J Med Genet* 1987;26:321-36.

- 123 Fraser FC, Jequier S, Chen MF. Chondrodysplasia, situs inversus totalis, cleft epiglottis and larynx, hexadactyly of hands and feet, pancreatic cystic dysplasia, renal dysplasia/absence, micropenis and ambiguous genitalia, imperforate anus. *Am J Med Genet* 1989;34:401-5.
- 124 Nivelon A, Nivelon JL, Mabile JP, et al. New autosomal recessive chondrodysplasia-pseudohermaphroditism syndrome. *Clin Dysmorphol* 1992;1:221-7.
- 125 Clark RM, Fey MB, Jensen RG, Hill DW. Desmosterol in human milk. *Lipids* 1983;18:264-6.
- 126 Bourre JM, Clement M, Gerard D, Chaudiere J. Alterations of cholesterol synthesis precursors (7-dehydrocholesterol, 7-dehydrodesmosterol, desmosterol) in dysmyelinating neurological mutant mouse (quaking, shiverer and trembler) in the PNS and the CNS. *Biochim Biophys Acta* 1989;1004:387-90.
- 127 Lin DS, Connor WE, Wolf DP, Neuringer M, Hachey DL. Unique lipids of primate spermatozoa: desmosterol and docosahexaenoic acid. *J Lipid Res* 1993;34:491-9.
- 128 Liscum L, Klansek JJ. Niemann-Pick disease type C. *Curr Opin Lipidol* 1998;9:131-5.
- 129 Carr BR, Simpson ER. Cholesterol synthesis in human fetal tissues. *J Clin Endocrinol Metab* 1982;55:447-52.
- 130 Bellknap WM, Dietschy JM. Sterol synthesis and low-density lipoprotein clearance in vivo in the pregnant rat, placenta, and fetus. *J Clin Invest* 1988;82:2077-84.
- 131 Tint GS, Sella M, Hughes-Benzie R, et al. Markedly increased tissue concentrations of 7-dehydrocholesterol combined with low levels of cholesterol are characteristic of the Smith-Lemli-Opitz syndrome. *J Lipid Res* 1995;36:89-95.
- 132 Pardridge WM, Mictus LJ. Palmitate and cholesterol transport through the blood-brain barrier. *J Neurochem* 1980;34:463-6.
- 133 Morell P, Jurevics H. Origin of cholesterol in myelin. *Neurochem Res* 1996;21:463-70.
- 134 Farese RV Jr, Ruland SL, Flynn LM, Stokowski RP, Young SG. Knockout of the mouse apolipoprotein B gene results in embryonic lethality in homozygotes and protection against diet-induced hypercholesterolemia in heterozygotes. *Proc Natl Acad Sci USA* 1995;92:1774-8.
- 135 Willnow TE, Hilpert J, Armstrong SA, et al. Defective forebrain development in mice lacking gp330/megalin. *Proc Natl Acad Sci USA* 1996;93:8460-4.
- 136 Roessler E, Belloni E, Gaudenz K, et al. Mutations in the human *Sonic Hedgehog* gene cause holoprosencephaly. *Nat Genet* 1996;14:357-60.
- 137 Porter JA, Young KE, Beachy PA. Cholesterol modification of Hedgehog signaling proteins in animal development. *Science* 1996;274:255-9.
- 138 Chiang C, Litingtung Y, Lee E, et al. Cyclopia and defective axial patterning in mice lacking Sonic hedgehog gene function. *Nature* 1996;383:407-13.
- 139 Roux C, Aubry MM. Action tératogène chez le rat d'un inhibiteur de la synthèse du cholestérol, le AY 9944. *C R Soc Biol* 1966;160:1353-7.
- 140 Barbu V, Roux C, Lambert D, et al. Cholesterol prevents the teratogenic action of AY 9944: importance of the timing of cholesterol supplementation to rats. *J Nutr* 1988;118:774-9.
- 141 Porter JA, von Kessler DP, Ekker SC, Young KE, Moses K, Beachy PA. The product of *hedgehog* autoproteolytic cleavage active in local and long-range signalling. *Nature* 1995;374:363-6.
- 142 Bitgood MJ, Shen L, McMahon AP. Sertoli cell signaling by Desert hedgehog regulates the male germline. *Curr Biol* 1996;6:298-304.
- 143 Iwasaki M, Le AX, Helms JA. Expression of indian hedgehog, bone morphogenetic protein 6 and gli during skeletal morphogenesis. *Mech Dev* 1997;69:197-202.
- 144 Cooper MK, Porter JA, Young KA, Beachy PA. Plant-derived and synthetic teratogens inhibit the ability of target tissues to respond to Sonic hedgehog signaling. *Science* 1998;280:1603-7.
- 145 Stone DM, Hynes M, Armanini M, et al. The tumour-suppressor gene patched encodes a candidate receptor for Sonic hedgehog. *Nature* 1996;384:129-34.
- 146 Silve S, Dupuy PH, Ferrara P, Loison G. Human lamin B receptor exhibits sterol C14-reductase activity in *Saccharomyces cerevisiae*. *Biochim Biophys Acta* 1998;1392:233-44.
- 147 DeHart DB, Lanoue L, Tint GS, Sulik KK. A rodent model of Smith-Lemli-Opitz syndrome; BM 15.766 induced teratogenesis. *Am J Med Genet* 1996;68:328-37.
- 148 Lanoue L, Dehart DB, Hinsdale ME, Maeda N, Tint GS, Sulik KK. Limb, genital, CNS, and facial malformations result from gene/environment-induced cholesterol deficiency: further evidence for a link to sonic hedgehog. *Am J Med Genet* 1997;73:24-31.
- 149 Stamellos KD, Shackelford JE, Tanaka RD, Krisans SK. Mevalonate kinase is localized in rat liver peroxisomes. *J Biol Chem* 1992;267:5560-8.
- 150 Biardi L, Krisans SK. Compartmentalization of cholesterol biosynthesis. Conversion of mevalonate to farnesyl diphosphate occurs in the peroxisomes. *J Biol Chem* 1996;271:1784-8.
- 151 Krisans SK. The role of peroxisomes in cholesterol metabolism. *Am J Resp Cell Mol Biol* 1992;7:358-64.
- 152 Tint GS, Salen G, Batta AK, et al. Correlation of severity and outcome with plasma sterol levels in variants of the Smith-Lemli-Opitz syndrome. *J Pediatr* 1995;127:82-7.
- 153 Kelley RI. Diagnosis of Smith-Lemli-Opitz syndrome by gas chromatography/mass spectrometry of 7-dehydrocholesterol in plasma, amniotic fluid and cultured skin fibroblasts. *Clin Chim Acta* 1995;236:45-58.
- 154 Abuelo DN, Tint GS, Kelley R, Batta AK, Shefer S, Salen G. Prenatal detection of the cholesterol biosynthetic defect in the Smith-Lemli-Opitz syndrome by the analysis of amniotic fluid sterols. *Am J Med Genet* 1995;56:281-5.
- 155 Kelley RI. RSH/Smith-Lemli-Opitz syndrome: mutations and metabolic morphogenesis. *Am J Hum Genet* 1998;63:322-6.
- 156 Roux C, Horvath C, Dupuis R. Teratogenic action and embryo lethality of AY 9944R. Prevention by a hypercholesterolemia-provoking diet. *Teratology* 1979;19:35-8.
- 157 Roux C, Dupuis R, Horvath C, Giroud A. Interpretation of isolated agenesis of the pituitary. *Teratology* 1979;19:39-43.
- 158 Kolf-Claw M, Chevy F, Siliati B, Wolf C, Mulliez N, Roux C. Cholesterol biosynthesis inhibited by BM15.766 induces holoprosencephaly in the rat. *Teratology* 1997;56:188-200.
- 159 Lecain E, Chenivess X, Spagnoli R, Pompon D. Cloning by metabolic interference in yeast and enzymatic characterization of Arabidopsis thaliana sterol delta 7-reductase. *J Biol Chem* 1996;271:10866-73.
- 160 Alley TL, Scherer SW, Huizenga JJ, Tsui LC, Wallace MR. Physical mapping of the chromosome 7 breakpoint region in an SLOS patient with t(7;20)(q32.1;q13.2). *Am J Med Genet* 1997;68:279-81.
- 161 Moebs FF, Striessnig J, Glossmann H. The mysteries of sigma receptors: new family members reveal a role in cholesterol synthesis. *Trends Pharmacol Sci* 1997;18:67-70.
- 162 Fitzky BU, Witsch-Baumgartner M, Erdel M, et al. Mutations in the delta7-sterol reductase gene in patients with the Smith-Lemli-Opitz syndrome. *Proc Natl Acad Sci USA* 1998;95:8181-6.
- 163 Witsch-Baumgartner M, Ogorelkova M, Kraft HG, et al. Mutational spectrum and genotype-phenotype correlation in 84 patients with Smith-Lemli-Opitz syndrome. *Am J Hum Genet* 2000;66:402-412.
- 164 Honda A, Tint GS, Honda A, et al. Measurement of 3 beta-hydroxysteroid delta 7-reductase activity in cultured skin fibroblasts utilizing ergosterol as a substrate: a new method for the diagnosis of the Smith-Lemli-Opitz syndrome. *J Lipid Res* 1996;37:2433-8.
- 165 Honda A, Tint GS, Salen G, et al. Sterol concentrations in cultured Smith-Lemli-Opitz syndrome skin fibroblasts: diagnosis of a biochemically atypical case of the syndrome. *Am J Med Genet* 1997;68:282-7.
- 166 Oostra RJ, Baljet B, Schutgens RBH, Hennekam RCM. Smith-Lemli-Opitz syndrome diagnosed in a 130-year-old anatomical specimen. *Am J Med Genet* 1997;68:257-9.
- 167 Cruz MLA, Wong WW, Mimouni F, et al. Effects of infant nutrition on cholesterol synthesis rates. *Pediatr Res* 1994;35:135-40.
- 168 Jones JH. Regulation of cholesterol biosynthesis by diet in humans. *Am J Clin Nutr* 1997;66:438-46.
- 169 Elias ER, Irons MB, Hurley AD, Tint GS, Salen G. Clinical effects of cholesterol supplementation in six patients with the Smith-Lemli-Opitz syndrome (SLOS). *Am J Med Genet* 1997;68:305-10.
- 170 Irons M, Elias ER, Abuelo D, et al. Treatment of Smith-Lemli-Opitz syndrome: results of a multicenter trial. *Am J Med Genet* 1997;68:311-14.
- 171 Ullrich K, Koch HG, Meschede D, Flotmann U, Seedorf U. Smith-Lemli-Opitz syndrome: treatment with cholesterol and bile acids. *Neuropediatrics* 1996;27:111-12.
- 172 Xu G, Salen G, Shefer S, et al. Treatment of the cholesterol biosynthetic defect in Smith-Lemli-Opitz syndrome reproduced in rats by BM 15.766. *Gastroenterology* 1995;109:1301-7.