

Preliminary clinical observations on autologous cultured skin fibroblasts transplantation in the treatment of keloids: a case report

X. HAN¹, S.-D. HU¹, D.-S. JI¹, Y. LIU¹, Y.-M. ZHAO²

¹Department of Plastic and Cosmetic Surgery, Beijing Hospital of Integrated Traditional Chinese and Western Medicine, Beijing, China

²Zhaoyuming Medical Aesthetic Clinic, Beijing, China

Xing Han and Shouduo Hu contributed equally to this work

Abstract. – BACKGROUND: Keloids are benign skin lesions that gradually invade the surrounding normal tissue, and no treatment has proven curative. In our previous clinical practice of autologous cultured fibroblast transplantation, we found that fibroblast injection might have some effect on treating keloids, and we attempted to treat keloids by using fibroblast transplantation after obtaining the patient's approval.

CASE REPORT: 1 patient was treated from March 2017 to June 2018. Autologous skin fibroblasts were separated from postauricular skin biopsy or resected keloid. They were cultured and expanded with exclusive methods. Cells ($3 \times 10^7/\text{ml}$) within four or five passages were injected intradermally at the keloid at one-month intervals, 15 times in the patient. Shrink of the keloid on the patient was observed. The keloid became softer, flatter, and lighter in color after treatment. The elasticity of the keloid was also increased. The treatment effect was associated with the number of treatment sessions.

CONCLUSIONS: This is the first report in which autologous fibroblast transplantation was used to treat keloids. Despite being only a single case experience, it suggests that keloid formation is a complex process in which still unknown factors may play a role.

Key Words:

Fibroblasts, Cell culture techniques, Cell transplantation, Keloid.

Introduction

Keloids are benign skin lesions that expand beyond the boundaries of the original wounds¹⁻³. They invade the surrounding normal tissue gradually and are characterized by unbalancing of the extracellular matrix (ECM), which is a result of

continuous formation and excessive accumulation of collagens. Although there are various kinds of treatments, no single one has proven curative.

In our previous clinical practice of autologous cultured fibroblast transplantation⁴⁻⁸, we noticed that except being augmented, hard depressed dermal scars also became softer and more flexible after cell injection. Patients who had hypertrophic scars among the depressed acne scars sometimes reported improvement of hypertrophic scars after fibroblast injection, including one with a hypertrophic scar on their lower jaw. This phenomenon was enlightening. Both keloids and hypertrophic scars are fibroproliferative skin disorders; even senior clinicians sometimes have difficulty in differentiating the two conditions, particularly with atypical cases. From that case, we assume that fibroblast injection might have some effect on treating keloids. After obtaining the patient's approval, we attempted to treat the keloid by using fibroblast transplantation on one patient to evaluate if autologous fibroblast transplantation could improve the symptom, elasticity, and shape of the keloid.

Case Presentation

Patient

A 25-year-old male suffered from chest keloid for more than 5 years with severe pruritus and pain. He could not remember the cause of the lesion. The keloid was surgically removed, followed by superficial radiotherapy in 2018 but it recurred 6 months later. From March 2017 to June 2018, we treated him with autologous cultured fibroblast transplantation. Besides the above-mentioned methods, he received no other treatments.

Cell Culture

The skin sample was harvested by a 3-mm circular punch biopsy instrument from the postauricular area for fibroblast culture. Preparation of the specimens and primary cultivation of autologous fibroblasts were performed using a proprietary process in DMEM/F12 medium (Hyclone) containing 10% fetal calf serum at 37°C and 5% CO₂. Cells at passage 4 or 5 were used for transplantation. One week before the first injection, a supernatant of one randomly chosen flask was aspirated for fungus, bacterial, and mycoplasma tests. Before transplantation, cells were digested and centrifuged at 1,500 rpm (r16 cm) for 8 minutes. The cell pellet was then suspended in a special medium to yield a final cell concentration of 3x10⁷/ml for transplantation. All digestive fluid and transfer mediums are specially made and protein-free. Residual bovine serum albumin (BSA) was analyzed using the ELISA method (BSA kit, Bosheng, Wuxi, China) to ensure BSA concentration was ≤5 ng/ml. If all the results came back negative, cell transplantation could be performed. The remaining cell suspension was cryopreserved for later treatments.

Cell Transplantation

Skin test was performed on the inner volar aspect of the forearm using 10,000-time diluted medium DMEM/F12 medium (containing 10% fetal calf serum) before cell transplantation.

Fibroblast transplantation was performed after applying topical anesthetic cream for 30 minutes. Cells were injected into the keloid using a 30G insulin syringe until the color of the keloid became pale. The average injection volume was about

0.25 ml cell suspension per square centimeter keloid. The treatment was performed once a month for 15 consecutive treatments.

Evaluation

Photographs were taken before each injection and in each follow-up using Nikon D90 under the same condition. A 50-cent coin was used as a control to compare the size and thickness of the keloid. The hardness of the keloid was evaluated using an LX-A durometer (HANDPI) before each treatment. Side effects were followed up one week after each injection by telephone to see if the patient had any red, swollen, or pruritus over the injection point.

Results

After 15 treatments, scar-related symptoms were significantly relieved. He felt no pain or tenderness under normal situations except a little itch when it was very hot or after excessive drinking. The keloid became lower and softer. He felt no pain when pinching the keloid. Clinical examination showed the color of the keloid was lighter and the flush around was disappeared. The hardness of the keloid decreased from 26.2 HA to 11 HA. The height of the keloid clearly decreased. But the size of the lesion increased a little. The length increased from 5.56 cm to 6.50 cm, and the width increased from 6 cm to 6.60 cm (Figure 1). No pain, bruise, allergic reaction, or infection was reported. No skin atrophy or telangiectasia was found. The last follow-up was 4 years after the last treatment. There was no

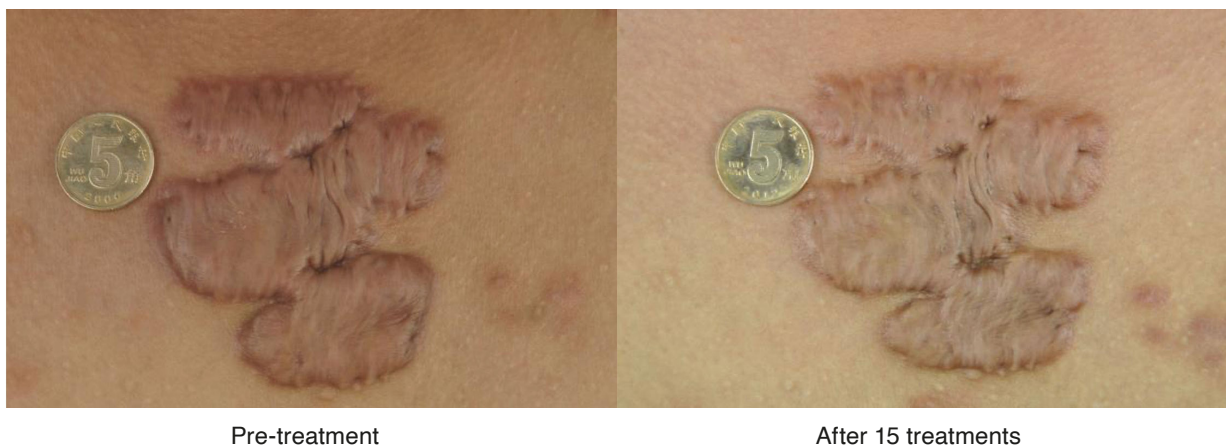


Figure 1. A-25-year-old patient's chest keloid receptor fibroblast transplantation. Left: Pre-treatment, Right: After 15 treatments, scar-related symptoms were significantly relieved, and the keloid became softer, flatter, and lighter in color after treatment.

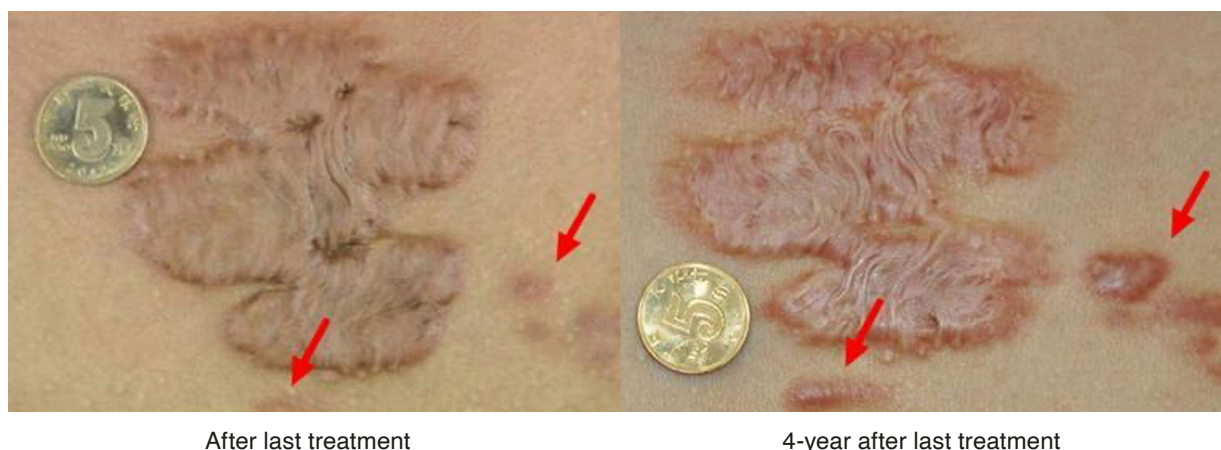

Figure 2. Last follow-up was 4 years after the last treatment. The color of the keloid became even lighter, and the height of the keloid continued to decrease. The border of the keloid became shallower and smoother. Untreated lesion (red arrow) next to the big one enlarged gradually during the four years, with obvious red and pruritus.

evidence for recurrence. While subjective complaints remained the same, objective parameters kept on improving. The color of the keloid became even lighter, and the height of the keloid continued to decrease. The border of the keloid became shallower and smoother. The hardness of the keloid continued to decrease from 11 HA to 5 HA, with a significant improvement in keloid pliability. The length of the keloid remained the same, but the width of the keloid continued to increase from 6.60 cm to 7.12 cm. More importantly, we noticed a small untreated lesion next to the big one, enlarged gradually in time, with red and pruritus (Figure 2).

Discussion

Keloids are benign dermal fibroproliferative tumors that occur in areas of cutaneous injury and extend beyond the original margins of the scar^{9,10}. Very little is known about keloid pathogenesis; it is commonly accepted that keloids are mainly related to abnormal fibroblasts, which express increased growth factors and receptors of these factors and synthesize excessive collagen products and other extracellular matrix components¹¹. Although numerous therapeutic approaches have been described¹²⁻²², alone or combined for keloids, none are curative. Physical removal of the lesion alone using either a scalpel or laser has consistently shown poor results^{12,13}, with recurrence rates of 40 to 100 percent¹⁴. Except for silicone gel^{15,16}, which enhanced the keloid skin hydration, other commonly accepted

treatment options are mainly aimed at inhibiting the activity of the keloid fibroblasts, such as intralesional steroid injections¹⁷, Botulinum toxin injections¹⁸, fat graft¹⁹, pressure therapy^{20,21} and superficial radiotherapy²².

In our previous clinical practice of autologous cultured fibroblast transplantation, we noticed hypertrophic scars and atypical keloid on the lower jaw also improved after cell transplantation. This phenomenon was enlightening. Based on that, we assume that fibroblast injection might have some effect on treating keloids, and we attempted to treat keloids by using fibroblast transplantation after obtaining the patient's approval.

Though the result did not completely erase the keloid, both keloids showed a reduction of height, an increase of pliability, and significant alleviation of subjective symptoms after treatment. Most importantly, keloid continued to improve after treatment stopped. The hardness of the keloid decreased from 11 HA to 5 HA during 4 years after treatment, gradually approaching normal skin hardness of 2-3 HA. We noticed that during the whole process, though the size of the keloid increased a little, its tension and height kept on reducing, with a continuous improvement of its stretchability and elasticity. This suggested that the size enlargement was not caused by growing of the keloid but by the gradual spreading of the keloid after cell transplantation. On the contrary, while the treated one gradually shrank, an untreated small lesion gradually enlarged with aggravated symptoms of erythema and pain, which confirmed the effectiveness of our treatment from another point of view.

In our laboratory research on autologous cultured fibroblast transplantation, we discovered that after fibroblast transplantation, new fibroblasts mainly secreted type III collagen^{6,7}. We think the improvement of the keloid might be caused by the increase of collagen III content and reduction of collagen I/III ratio, and then gradually reach a balance mechanics equilibrium condition.

Cutaneous wound healing in the postnatal organism is a balance between rapid wound closure to reestablish the protective barrier of the skin and over-exuberant wound healing resulting in excessive scar formation. Extracellular matrix (ECM) plays an essential and complex role in tissue repair, regeneration, and maintenance²³. Collagens are the main structural element of the ECM, forming a relaxed network of cross-linked fibers throughout the dermis to maintain tissue integrity. In adults, type I collagen constitutes approximately 80% of dermal collagen. In contrast, type III collagen is abundant in fast-growing tissue, particularly at the early stages of wound repair, and then replaced by type I collagen as the wound repair process slows down. Keloid is formed by excessive type I collagen accumulation and unbalancing of ECM components. In normal adult skin and hypertrophic scar, the ratio between type I and III collagen is 6:1 and 7:1, respectively. However, in keloid, this ratio abnormally increased to 17:1²⁴⁻²⁷. Volk²⁸ proved that diminished type III collagen increased scar deposition in cutaneous wound healing, which suggested that type III collagen was a key mediator of tissue regeneration and might provide a target for therapeutic intervention for impaired wound healing.

Unlike all the existing therapeutic modalities, which inhibit or destroy the keloids, our method focused on adjusting the environment of ECM, reducing the keloid gradually from the inside. We hypothesized that injected fibroblasts would secrete new type III collagen and increase type III collagen levels in keloid, gradually turning a keloid into a hypertrophic scar in terms of collagen proportion. The difference between keloids and hypertrophic scars was that hypertrophic scars would atrophy spontaneously³. Increasing type III collagen level would then trigger the remodeling process similar to that of hypertrophic scar until it reached a mechanics equilibrium condition. Based on this hypothesis, we also planned another experiment to treat keloids using freeze-drying type III collagen.

Conclusions

This is the first report of autologous fibroblasts transplantation to treat keloids. However, only one case experience does not allow us to assess the effectiveness of this treatment. Moreover, our evaluation was only based on clinical manifestation; more profound studies on histology, molecular, and gene level are needed to verify our therapeutical hypothesis.

Conflict of Interest

The authors declare no potential conflicts of interest with respect to the authorship and/or publication of this article.

Ethics Approval

Not applicable to a case report.

Funding

This study received no financial support.

Authors' Contributions

Yuming Zhao contributed to the conception and design, data analysis and interpretation; Xing Han and Shouduo Hu contributed to the manuscript writing and final revision; Dongshuo Ji and Ying Liu contributed to the collection and assembly of data; and all authors have read and approved the final manuscript.

Informed Consent

A signed informed consent agreement form was obtained from the patient.

References

- 1) Xu J, Yang E, Yu NZ, Long X. Radiation Therapy in Keloids Treatment: History, Strategy, Effectiveness, and Complication. *Chin Med J (Engl)* 2017; 130: 1715-1721.
- 2) Hsu CK, Lin HH, Harn HI, Hughes MW, Tang MJ, Yang CC. Mechanical forces in skin disorders. *J Dermatol Sci* 2018; 90: 232-240.
- 3) Ogawa R. Keloid and Hypertrophic Scars Are the Result of Chronic Inflammation in the Reticular Dermis. *Int J Mol Sci* 2017; 18: 606.
- 4) Zhao YM, Wang JQ, Yan XM, Zhang HM, Cao R, Wang CM. Influence of extracts from normal human dermis on proliferation and collagen production of fibroblasts. *Chin J Med Aesth Cosmet* 2008; 14: 393-396.
- 5) Zhao YM, Ding JS, Zuo J, Fang FD, Wang JQ. Observation on proliferation and collagen secre-

- tion of the transplanted human fibroblasts in nude mice. *Basic and Clinical Medicine* 2007; 27: 1140-1145.
- 6) Zeng W, Zhang S, Liu D, Chai M, Wang J, Zhao Y. Preclinical safety studies on autologous cultured human skin fibroblast transplantation. *Cell Transplant* 2014; 23: 39-49.
 - 7) Zhao Y, Wang J, Yan X, Li D, Xu J. Preliminary survival studies on autologous cultured skin fibroblasts transplantation by injection. *Cell Transplant* 2008; 17: 775-783.
 - 8) Wang Z, Fong KD, Phan TT, Lim IJ, Longaker MT, Yang GP. Increased transcriptional response to mechanical strain in keloid fibroblasts due to increased focal adhesion complex formation. *J Cell Physiol* 2006; 206: 510-517.
 - 9) Mari W, Alsabri SG, Tabal N, Younes S, Sherif A, Simman R. Novel insights on understanding of keloid scar: Article review. *J Am Coll Clin Wound Spec* 2016; 7: 1-7.
 - 10) Chodon T, Sugihara T, Igawa HH, Funayama E, Furukawa H. Keloid-derived fibroblasts are refractory to Fas-mediated apoptosis and neutralization of autocrine transforming growth factor-beta1 can abrogate this resistance. *Am J Pathol* 2000; 157: 1661-1669.
 - 11) Lee HJ and Jang YJ. Recent Understandings of Biology, Prophylaxis and Treatment Strategies for Hypertrophic Scars and Keloids. *Int J Mol Sci* 2018; 19: E711.
 - 12) Gonzalez AC, Costa TF, Andrade ZA, Medrado AR. Wound healing - A literature review. *An Bras Dermatol* 2016; 91: 614-620.
 - 13) Gauglitz GG. Management of keloids and hypertrophic scars: current and emerging options. *Clin Cosmet Investig Dermatol* 2013; 6: 103-114.
 - 14) McGoldrick RB, Theodorakopoulou E, Azzopardi EA, Murison M. Lasers and ancillary treatments for scar management Part 2: Keloid, hypertrophic, pigmented and acne scars. *Scars Burn Heal* 2017; 3: 2059513116689805.
 - 15) Kim JS, Hong JP, Choi JW, Seo DK, Lee ES, Lee HS. The Efficacy of a Silicone Sheet in Postoperative Scar Management. *Adv Skin Wound Care* 2016; 29: 414-420.
 - 16) Puri N, Talwar A. The efficacy of silicone gel for the treatment of hypertrophic scars and keloids. *J Cutan Aesthet Surg* 2009; 2: 104-106.
 - 17) Cho MY, Song A, Chung KY, Roh MR. A Novel Method of Steroid Delivery to Improve the Efficacy of Intralesional Injection in Keloid Treatment. *Dermatol Surg* 2022; 48: 631-635.
 - 18) Sohrabi C, Goutos I. The use of botulinum toxin in keloid scar management: a literature review. *Scars Burn Heal* 2020; 6: 2059513120926628.
 - 19) Zhou J, Shen JY, Tao LE, Chen H. The Potential Molecular Mechanism of Autologous Adipose Tissue Grafting in Treating Keloid Patients: a Case-control Study. *Research Square*, 2021; <https://doi.org/10.21203/rs.3.rs-149077/v1>.
 - 20) Tanaydin V, Beugels J, Piatkowski A, Colla C, van den Kerckhove E, Hugenholtz GC, van der Hulst RR. Efficacy of custom-made pressure clips for ear keloid treatment after surgical excision. *J Plast Reconstr Aesthet Surg* 2016; 69: 115-121.
 - 21) Bran GM, Brom J, Hormann K, Stuck BA. Auricular keloids: combined therapy with a new pressure device. *Arch Facial Plast Surg* 2012; 14: 20-26.
 - 22) Ji J, Tian Y, Zhu YQ, Zhang LY, Ji SJ, Huan J, Zhou XZ, Cao JP. Ionizing irradiation inhibits keloid fibroblast cell proliferation and induces premature cellular senescence. *J Dermatol* 2015; 42: 56-63.
 - 23) Xue M, Jackson CJ. Extracellular Matrix Reorganization During Wound Healing and Its Impact on Abnormal Scarring. *Adv Wound Care (New Rochelle)* 2015; 4: 119-136.
 - 24) Meenakshi L, Vidyameenakshi S, Ananthram D, Ramakrishnan KM, Jayaraman V, Babu M. Low decorin expression along with inherent activation of ERK1, 2 in ear lobe keloids. *Burns* 2009; 35: 519-526.
 - 25) Verhaegen PD, van Zuijlen PP, Pennings NM, van Marle J, Niessen FB, van der Horst CM, Middelkoop E. Differences in collagen architecture between keloid, hypertrophic scar, normotrophic scar, and normal skin: an objective histopathological analysis. *Wound Repair Regen* 2009; 17: 649-656.
 - 26) Friedman DW, Boyd CD, Mackenzie JW, Norton P, Olson RM, Deak SB. Regulation of collagen gene expression in keloids and hypertrophic scars. *J Surg Res* 1993; 55: 214-222.
 - 27) Sidgwick GP, Bayat A. Extracellular matrix molecules implicated in hypertrophic and keloid scarring. *J Eur Acad Dermatol Venereol* 2012; 26: 141-152.
 - 28) Volk SW, Shah SR, Cohen AJ, Wang Y, Brisson BK, Vogel LK, Hankenson KD, Adams SL. Type III collagen regulates osteoblastogenesis and the quantity of trabecular bone. *Calcif Tissue Int* 2014; 94: 621-631.