

ROTATOR CUFF REPAIR JUST IN LOCAL ANESTHESIA IS POSSIBLE

M. TINAZZI¹, B. ROSATO¹, M. BARCA²

• • •

¹Department of Pharmaceutical and Pharmacological Sciences, University of Padua, Padua, Italy

²H.U. Traumatology and Orthopedics, Sant'Anna Hospital Cona-Ferrara, Ferrara, Italy

CORRESPONDING AUTHOR

Mattia Tinazzi, MD; e-mail: mattia.tinazzi@studenti.unipd.it

ABSTRACT – Objective: Rotator cuff repair consists of surgical tendon re-fix to the bone. Once the lesion has been identified, loco-regional anesthesia and general anesthesia are the anesthesiologic techniques preferentially used in the intervention for the resolution of the injury, but their use involves several side effects, such as hemidiaphragmatic paralysis, laryngeal nerve block, and pneumothorax. In literature, only one case report presents an arthroscopic repair of massive rotator cuff tears performed under local anesthesia and sedation: in this case, local anesthesia was preferred because of the failure of the locoregional block.

Case presentation: In our work, we performed a mini-open rotator cuff repair on a 56-year-old woman with the use of simple local anesthesia, which allowed us to obtain a satisfactory result bypassing side effects deriving from other anesthetic techniques usually used. The patient recovered optimal abduction and good internal rotation of the limb, with a significant reduction in pain mobility.

Conclusions: The prospect of performing surgical repair of the rotator cuff under local anesthesia is very interesting, allowing to avoid problems that can occur with general anesthesia administration or regional interscalene block.

KEYWORDS: Rotator cuff repair, Interscalene block, Hemidiaphragmatic paralysis, Local anesthesia.

LIST OF ABBREVIATIONS: GA (general anesthesia); LA (local anesthesia); LRA (loco-regional anesthesia); NSAIDs (nonsteroidal anti-inflammatory drugs); LHBT (long head brachial biceps tendon); MRI (magnetic resonance imaging); NRS (Numerical Rating Scale); VAS (Visual Analogue Scale); ADL (Activities of Daily Living); IADL (Instrumental Activities of Daily Living); ROM (range of motion).

INTRODUCTION

The joint movement of the shoulder in the space is allowed by a complex of muscles and tendons called “rotator cuff”, which permits abduction, flexion, and rotation motions. In particular, muscles involved in this complex are *M. Subscapularis*, implied in internal humeral rotation movements, *M. Teres Minor* which stabilizes the glenoid cavity and humerus’ head (high arm external rotation), *M. Infraspinatus* implied in the lateral humeral rotation, and *M. supraspinatus*, that together with deltoid contribute to the humeral abduction and extra rotation movements¹. The depression of the humeral head, the external rotation of the shoulder joint, the lateral joint lifting and abduction movements as well as the humeral



stabilization in the joint itself, are allowed by rotator cuff complex. About the shoulder's anatomical area innervation, the suprascapular nerve innervates the glenohumeral joint, acromioclavicular joint supraspinatus, infraspinatus muscle, part of the deltoid muscle, and part of the cutaneous areas of the shoulder. Axillary nerve innervates teres minor muscle, part of the deltoid muscle and the superior lateral brachial cutaneous skin area. On the other hand, subscapular nerve, divided into superior, middle, and inferior subscapular nerve, innervates the subscapularis muscle, the latissimus dorsi, and teres minor muscle, respectively². Injuries to rotator cuff complex affect the joint movements of the shoulder and increase in frequency with advancing age³. In general, the main cause of the damage is represented by degeneration of tendon tissue, and the severity of the damage is related to the number of tendons involved. There are partial lesions that don't compromise the total joint function and are often treated by avoiding surgery, complete lesions where the damage extends along with the entire tendon thickness, and massive lesions involving more tendons of the cuff⁴. Massive lesions are those characterized by the highest rate of therapeutic failure, due to the adverse effects deriving from arthroscopic methods applied in the intervention, performed predominantly through brachial plexus block at interscalenic muscles level or use of general anesthesia (GA)⁵. The most worrying side effect in this type of intervention is hemidiaphragmatic paralysis derived from phrenic nerve block, but there are other different complications such as laryngeal nerve block, pneumothorax, and convulsions⁶. Therefore, arthroscopy shows numerous advantages such as faster return to normal joint function and resistance to post-operative pain compared to other types of more invasive surgery techniques, but side effects should not be underestimated⁷. GA or interscalene block are effective methods that allow good pain control, but they cannot be considered elective for patients with complications in the upper respiratory tract, as the risks would exceed the benefits. In these cases, the best strategy would be to switch to local anesthesia (LA) to accompany the arthroscopic procedure, in order to provide adequate pain control without the risk of compromising respiratory function resulting from phrenic nerve block, as a consequence of interscalenic block⁸. The aim is obtaining results comparable to surgery with interscalene block, and therefore an adequate joint restoration avoiding complications of cardiorespiratory nature. To overcome these problems, a strategy reported in literature could be to replace the interscalene block with the block of the infraclavicular brachial plexus, the suprascapular nerve, and the superficial cervical plexus, in combination. This strategy would allow intervention with adequate operative analgesia and without the need for opioids for sedation, offering an attractive alternative to the gold standard of GA. However, the risk of phrenic nerve palsy, which could derive from an anesthetic infiltration into the interscalenic sulcus through the paravertebral fascia, persists. Furthermore, the number of anesthetic injections is considerable and directly proportional to the risks⁹. As regards mini-open treatment methods, the executions are as follows: loco-regional anesthesia (LRA) such as an interscalene brachial plexus block alone; GA alone or with LRA, or sedation with LRA. In these cases, problems seen above are not solved: with GA the main critical issues are airways management, opioids drawbacks, post-op sedation, and prolonged hospitalization; LRA, on the other hand, can cause perineural injection risks, intravascular injection hazard, high spinal anesthesia complications, diaphragm paralysis due to the interscalene block, recurrent laryngeal nerve block and rare cranial nerve paresis failure of the blocks. The topic of this clinical case focuses on outlining a new anesthesiological strategy in mini-open rotator cuff repair surgery, aimed at minimizing the risks deriving from the frequently used anesthetic modalities, proposing an innovative and safer approach.

CASE REPORT

The patient undergoing this new approach of mini-open rotator cuff repair surgery was 59 years old, weighed 52 kg and was 165 cm tall. She worked as a health assistant in a hospital ward, and she hadn't referred any trauma or sport activities. She smoked 15 cigarettes per day and suffered from hypercholesterolemia and osteopenia, reason why she was in treatment with Vitamin D per OS: in particular, patient took 1 capsule of 0.266 mg of calcifediol (Neodidro, Bruno Farmaceutici S.p.A., Rome, Italy) per month to maintain serological average level of 25-OH-cholecalciferol between 25 and 40 ng/mL. Excluding the intake of cholecalciferol, the patient has never taken other drugs, except nonsteroidal anti-inflammatory drugs (NSAIDs) as needed. Patient complained of shoulder pain starting four months earlier: more in detail, she suffered from pain due to overhead activities that occurred when the limb was elevated above the shoulder. Moreover, patient presented very limited mobility of the limb, represented by the impossibility of raising the arm above the head and internal rotation. Ethics Committee Approval was obtained by our hospital and the patient signed the informed consent.

Pre-operative functional analysis

Magnetic resonance performed showed several anatomical aspects, such as arrowing of subacromial space, supraspinous tendon impingement in the critical point, and subchondral degeneration on the postero-lateral outline of the humeral head, with subchondral suffering. It is also highlighted periinsertional full-thickness supraspinous tear, Long Head Brachial Biceps Tendon (periLHBT) edema (intertubercular sulcus), and periinsertional subspinous tendon tear (**Figure 1**). The MRI (Magnetic resonance imaging) still revealed acromio-clavear osteoarthritis. A physical test was performed subsequently, giving the following results: Job test: positive +++; abduction and elevation of the right arm up to 70-80°; Napoleon test: negative --; apprehension test: negative; palm up test: positive; Numerical Rating Scale (NRS): 10/10. Patient also recorded a pain perception score of 8 on the Visual Analogue Scale (VAS), complaining difficulties in both Activities of Daily Living (ADL) and Instrumental Activities of Daily Living (IADL) (**Table 1**).

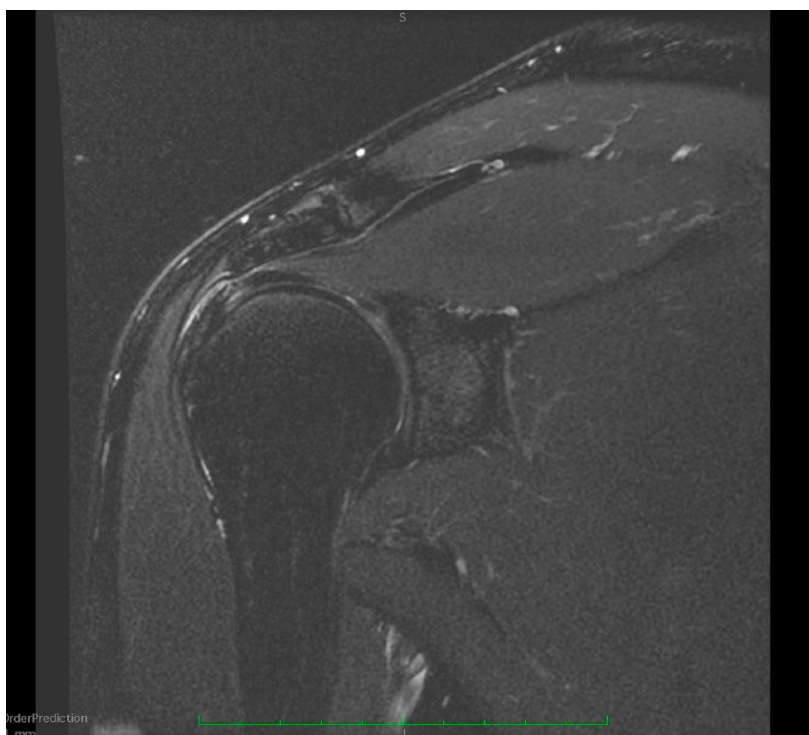


Figure 1. Detection of lesions through magnetic resonance imaging.

Table 1. Clinical conditions of the patient.

PHYSICAL TEST	RESULTS
Job test	Positive +++
Abduction and elevation of right arm	70-80°
Napoleon test	Negative --
Apprehension test	Negative
Palm up test	Positive
Numerical Rating Scale (NRS)	10
Visual Analogue Scale (VAS)	8
Activities of Daily Living (ADL)	Complaining difficulties
Instrumental Activities of Daily Living (IADL)	Complaining difficulties

Pre-surgical intervention: anesthesia

The anesthetic method used involves suprascapular nerve block, LA and light sedation. For the nerve block 1% Lidocaine (Monico S.p.A., Venezia, Italy) 10 mL was injected around the suprascapular nerve. A sterile mixture of Lidocaine 1% 20 mL and Carbocaine (AstraZeneca S.p.A., Milan, Italy) 1% 20 mL was used to provide local anesthesia. 10 mL was injected subcutaneously around the surgical site, 10 mL sub-acromially, and another 10 mL into the glenohumeral joint intraarticularly. If necessary, the remaining solution can be used during surgery. To provide the state of sedation, a propofol and ketamine (L. Molteni & C. dei f.lli Alitti Società di Esercizio S.p.A., Florence, Italy) intravenous syringe pump is prepared and connected to the patient's intravenous catheter. Regarding the specific intervention of this clinical case, midazolam (Siegfried Hameln GmbH, Hameln, Germany) 0.025 mg/kg with ketamine 0.1 mg/kg i.v. were injected as a bolus. During surgery, a continuous perfusion of 1% propofol (35 mg/kg/min) and ketamine (20 mg/kg/min) was planned under standard monitoring and oxygen supplementation; it was intended to be administered by the anesthetist to achieve muscle relaxation and patient comfort, but it wasn't realized because the patient preferred to be fully awake and refused any other medication.

Surgical intervention: mini-open rotator cuff repair

The patient was positioned on the "beach chair" (Tenet Tmax Beach Chair; Tenet Medical Engineering, Calgary, Canada). A sterile field was prepared, and the incision area marked, so the response to skin puncture was tested (**Figure 2**). A bra strap incision of two inches cranio distally at the acromion anterior angle was performed (**Figure 3**). The anterolateral acromion deltoid area was exposed, and through an L incision with a detachment of the deltoid muscle from the acromion the subacromial area was exposed too (**Figure 4**), so part of the subacromial deltoid bursa could be removed exposing the rotator cuff (**Figure 5**). The tendon of the long head of the biceps bachi muscle was isolated, so tenotomy (**Figure 6**) and tenodesis (**Figure 7**) of it could be done. The edges of the massive cuff tear were subsequently exposed. The cuff was sutured seamlessly with two anchors of two points each (**Figure 8,9**). A light acromioplasty was performed too. The edges of the deltoid muscle were then attached to the acromion through two non-resorbable transosseous sutures (**Figure 10**). Finally, the subcutaneous tissue was sutured through single stitches, and the skin area was sutured with a continuous resorbable suture (**Figure 11,12**).

After surgery, the patient kept her upper arm in an arm pocket at 30 degrees; she was discharged in the evening and her pain was controlled with NSAIDs plus paracetamol. She started physiotherapy after 4 weeks and for six months. Initially, the program submitted to her after the removal of the tutor included exercises aimed at increasing range of motion (ROM) progressively and gradually performed, both passively and actively. After 8 weeks, exercises to strengthen the shoulder girdle and the stabilizing/depressor muscles of the shoulder were performed.

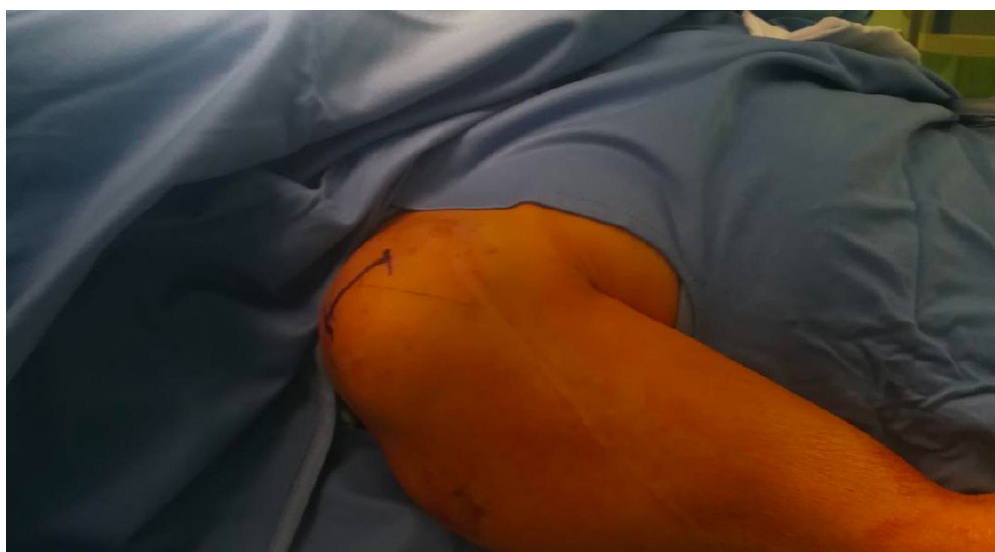

Figure 2. Incision area marking.

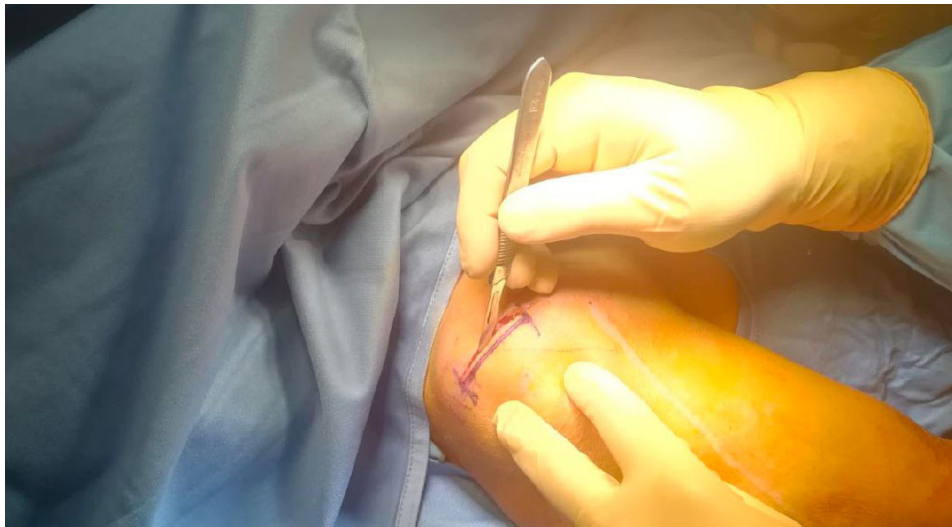


Figure 3. Incision.

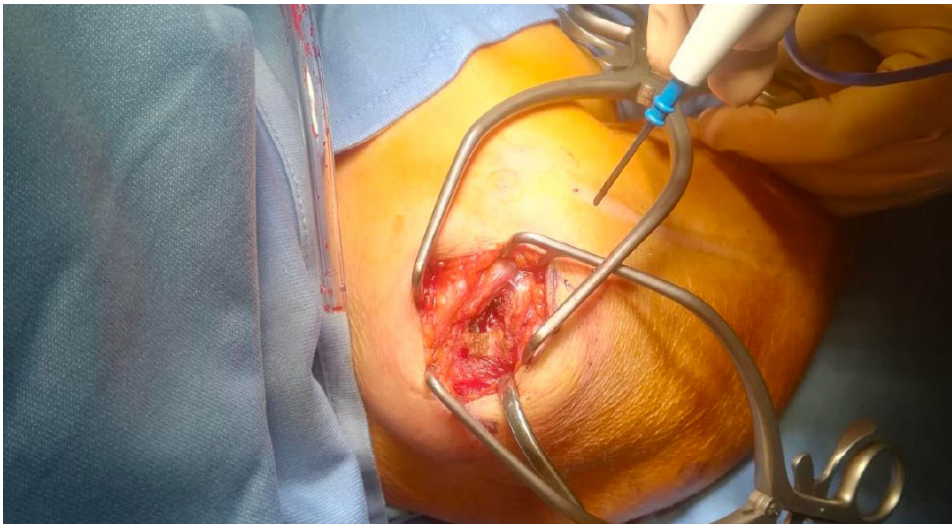


Figure 4. Deltoid flap eversion.

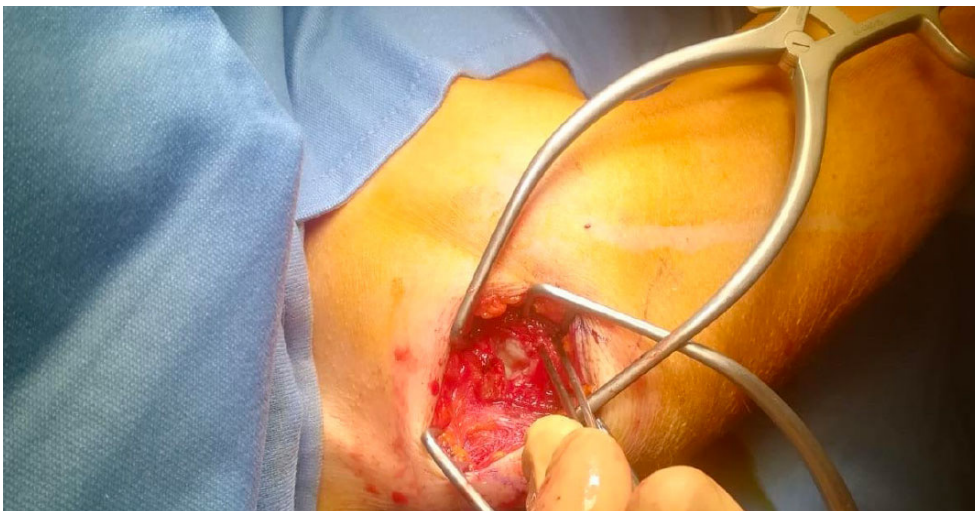

Figure 5. Rotator cuff lesion show-up.

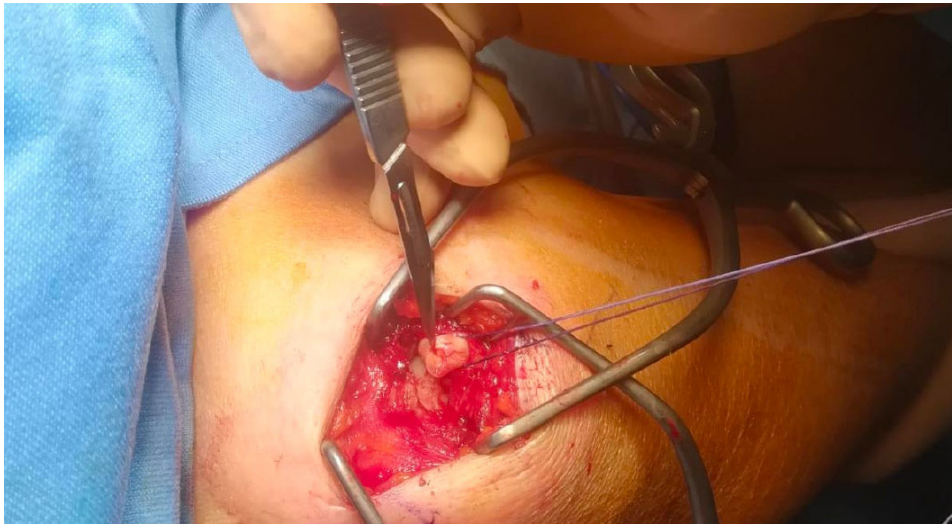


Figure 6. Tenotomy of long head brachial biceps tendon.

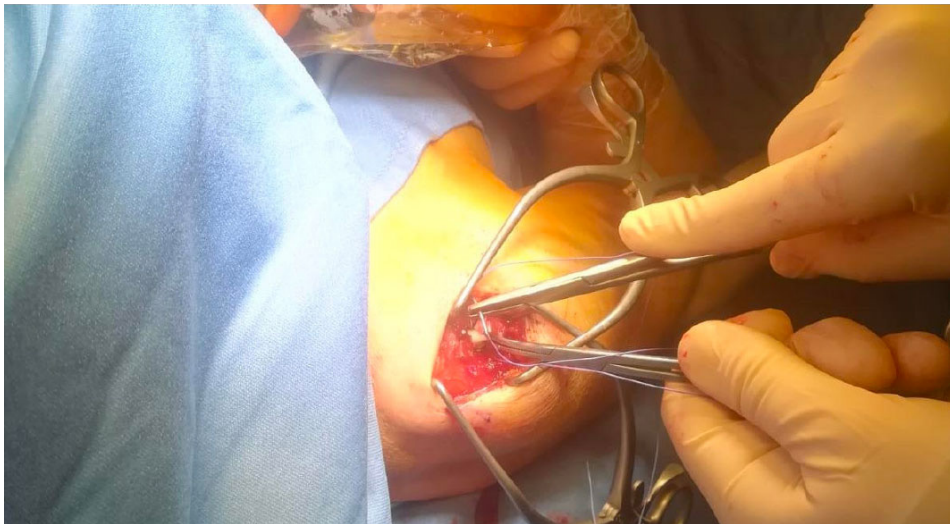


Figure 7. Long head brachial biceps tenodesis.

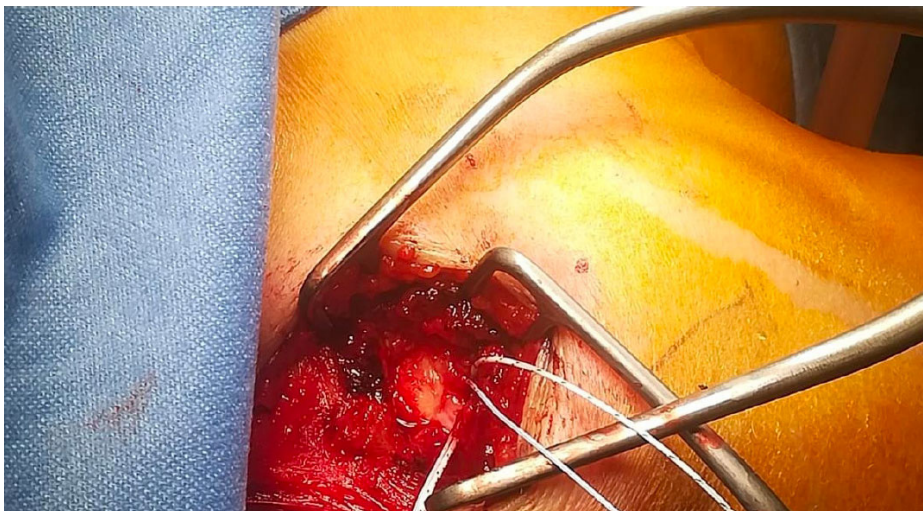

Figure 8. First anchor placement.

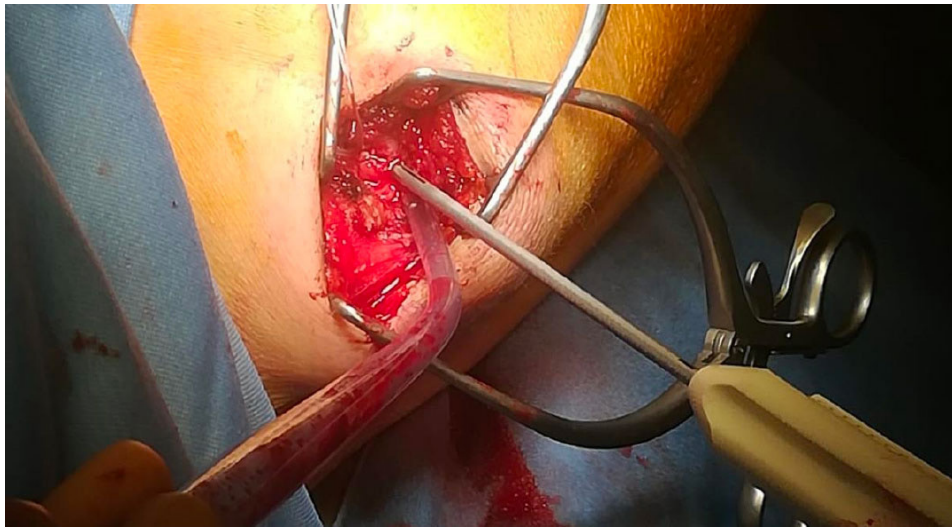


Figure 9. Second anchor placement.

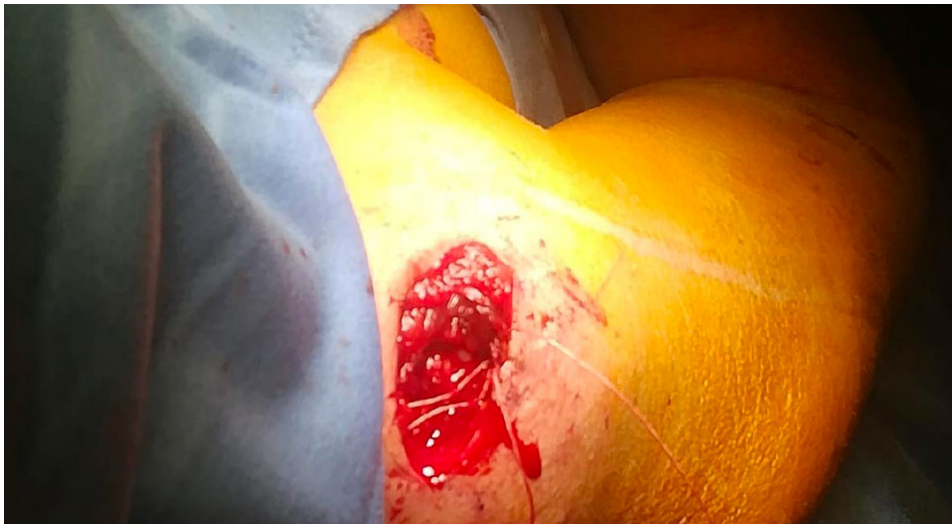

Figure 10. Deltoid flap closure.

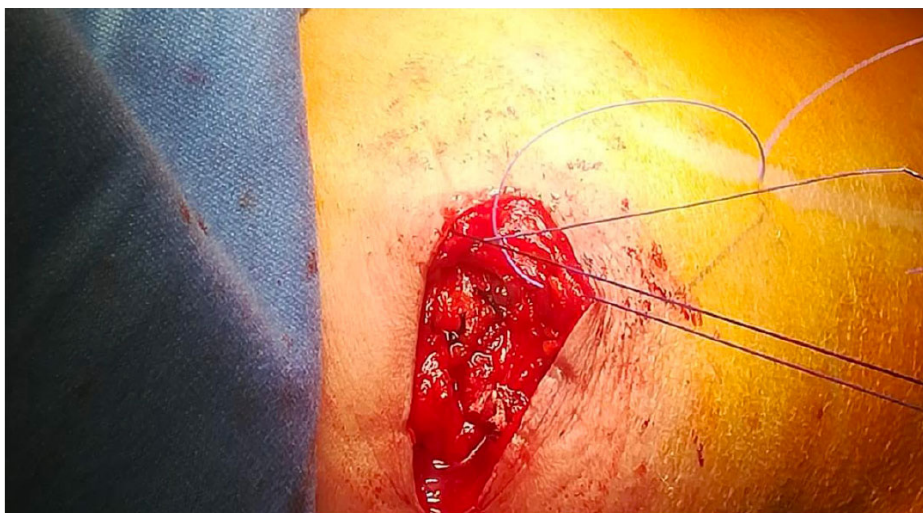

Figure 11. Skin suture.

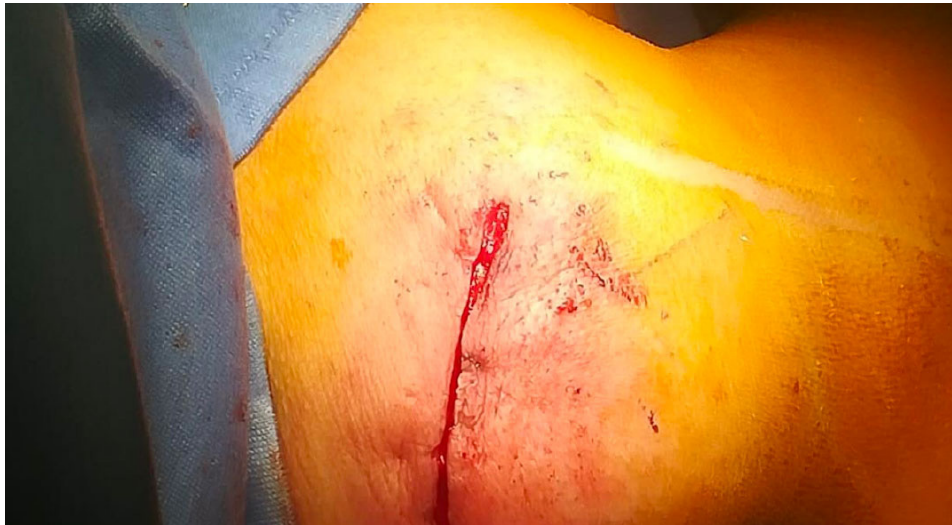

Figure 12. Skin closure.

At the four-month follow-up, the patient had NRS 2/10, optimal abduction and external rotation, but some rigidity persists, so she performed successive stretching exercises with benefits. In the end, the elevation of the limb extends well beyond the head without any pain perception, in addition to good internal rotation and excellent mobility beyond the sacrum. Patient finally reported being optimally satisfied with this procedure (**Table 2**).

Table 2. Comparison baseline/post-surgery.

BEFORE SURGERY	AFTER SURGERY (four-month follow-up)
NRS: 10	NRS: 2
Very limited mobility of the limb	Good mobility (with some rigidity)
Pain due to overhead activities when the limb was elevated above the shoulder	Elevation of the limb well beyond the head without any pain perception; excellent mobility beyond the sacrum
Impossibility of raising the arm above the head and internal rotation	Good internal rotation, optimal abduction and external rotation

DISCUSSION

The preferred surgical methods for rotator cuff repair are mini-open surgery and shoulder arthroscopy. Regardless of the method applied, it is essential to choose the most appropriate anesthetic technique through a pre-operative evaluation of the patient¹⁰. It is well known that most of the operations are performed through an interscalene block to the brachial plexus, associated with GA or LRA if the intervention results challenging in terms of duration and complexity. However, using these anesthetic strategies, there is a risk of running into severe problems such as pneumothorax, Horner's syndrome, Bezold-Jarish reflex bradycardia, and diaphragmatic hemiparesis from the ipsilateral phrenic nerve block, especially in that group of patients characterized by respiratory complications^{11,12}. The use of brachial plexus block with GA/LRA and the complications resulting from it constitute the main problem of traditional approaches. The surgical methodology applied to this clinical case consists of to replace brachial plexus block with suprascapular nerve anesthesia, allowing to overcome bias of the traditional technique and offering an interesting alternative in anesthetic terms. In fact, LA (with possible light sedation) allows sufficient pain control to perform a high-performance massive repair of the rotator cuff, limiting risks associated with regional and general anesthesia described before, such as opioids drawbacks, post-op sedation, prolonged hospi-

talization (in GA), and perineural injection risks, diaphragm paralysis, and laryngeal nerve block (in LRA). Furthermore, operating in LA allows the visual assessment of the muscle contractility, and therefore an instant diagnosis of the strength of the repair performed, offering a further advantage over other anesthesia techniques and traditional approaches lacking direct patient-operator contact and instant feedback¹³. The selection of the patient, the anesthetic dosage, and the mastery of injection techniques (in this case the correct anesthesia of the suprascapular nerve) are distinctive elements to perform the intervention with the proposed procedure unlike the previous ones. The aim is obtaining maximum comfort for the patient as well as a good safety profile of intervention: patient's degree of collaboration and responsiveness are essential because necessary for having continuous feedback in real-time, increasing the positive outcome of intervention carried out in precision and safety.

CONCLUSIONS

The prospect of performing surgical repair of the rotator cuff under local anesthesia is very interesting, especially for those patients who have a cardiorespiratory pathology that contraindicates the administration of GA or regional interscalene block. This new technique, which to our knowledge has not been published before, expands the possibilities of surgical intervention for patients with medical conditions at high risk for classic anesthesia methods. Additionally, its safety and simplicity, plus the ability to provide direct visualization of rotator cuff function, make local anesthesia a potential alternative to other elective anesthetic techniques.

FUNDING

No funding is declared for this article.

ETHICS COMMITTEE APPROVAL:

Ethics Committee Approval was obtained by the hospital.

INFORMED CONSENT:

Consent for case publication was obtained by the patient.

AVAILABILITY OF DATA AND MATERIALS:

All data and materials are available upon request.

CONFLICT OF INTEREST:

There is no conflict of interest to disclose.

AUTHORS CONTRIBUTIONS:

Mattia Tinazzi and Maurizio Barca were involved in the conception of the manuscript.

Mattia Tinazzi, Benedetta Rosato, and Maurizio Barca were involved in the writing of the manuscript.

Maurizio Barca was involved in the conception of the surgical intervention and performed it.

REFERENCES

1. Aguirre K, Mudreac A, Kiel J. Anatomy, Shoulder and Upper Limb, Subscapularis Muscle. In StatPearls; StatPearls Publishing: Treasure Island (FL), 2023.
2. Okwumabua E, Thompson JH. Anatomy, Shoulder and Upper Limb, Axilla. *Nerv* 2022.
3. Tempelhof S, Rupp S, Seil R. Age-Related Prevalence of Rotator Cuff Tears in Asymptomatic Shoulders. *J Shoulder Elbow Surg* 1999; 8: 296-299.
4. Rousseau T, Roussignol X, Bertiaux S, Duparc F, Dujardin F, Courage O. Arthroscopic Repair of Large and Massive Rotator Cuff Tears Using the Side-to-Side Suture Technique. Mid-Term Clinical and Anatomic Evaluation. *Orth Traumatol Surg Res* 2012; 98: S1-S8.
5. Bishop JY, Sprague M, Gelber J, Krol M, Rosenblatt MA, Gladstone J, Flatow EL. Interscalene Regional Anesthesia for Shoulder Surgery. *J Bone Joint Surg Am* 2005; 87: 974-979.
6. Chiaghana CO, Awoniyi CA. Delayed Onset and Long-Lasting Hemidiaphragmatic Paralysis and Cranial Nerve Deficit after Interscalene Nerve Block for Rotator Cuff Repair in Beach Chair Position. *J Clin Anesth* 2016; 34: 571-576.
7. Brislin KJ, Field LD, Savoie FH. Complications After Arthroscopic Rotator Cuff Repair. *J Arthrosc Rel Surg* 2007; 23: 124-128.
8. Beauchamp M, Roy JD. Local Anesthesia for Arthroscopic Rotator Cuff Surgery: Patient-Physician Relationship as the Origin of Technical Innovation. *J Med Pers* 2011; 9: 31-33.

9. Musso D, Flohr-Madsen S, Meknas K, Wilsgaard T, Ytrebø LM, Klaastad Ø. A Novel Combination of Peripheral Nerve Blocks for Arthroscopic Shoulder Surgery. *Acta Anaesthesiol Scand* 2017; 61: 1192–1202.
10. Beecroft CL, Coventry DM. Anaesthesia for Shoulder Surgery. *Cont Educ Anaesth Crit Care Pain* 2008; 8: 193-198.
11. D'Alessio JG, Weller RS, Rosenblum M. Activation of the Bezold-Jarisch Reflex in the Sitting Position for Shoulder Arthroscopy Using Interscalene Block. *Anesth Analg* 1995; 80: 1158-1162.
12. Urmei WF, Talts KH, Sharrock NE. One Hundred Percent Incidence of Hemidiaphragmatic Paresis Associated with Interscalene Brachial Plexus Anesthesia as Diagnosed by Ultrasonography. *Anesth Analg* 1991; 72: 498-503.
13. Borgeat A, Ekatodramis G, Kalberer F, Benz C. Acute and Nonacute Complications Associated with Interscalene Block and Shoulder Surgery: A Prospective Study. *Anesthesiology* 2001; 95: 875–880.