

## Review

# Fragile X-Associated Tremor Ataxia Syndrome: The Expanding Clinical Picture, Pathophysiology, Epidemiology, and Update on Treatment

Deborah A. Hall<sup>1\*</sup> & Joan A. O'Keefe<sup>2</sup><sup>1</sup> Department of Neurological Sciences, Rush University, Chicago, Illinois, United States of America, <sup>2</sup> Department of Anatomy & Cell Biology, Rush University, Chicago, Illinois, United States of America

## Abstract

Fragile X-associated tremor/ataxia syndrome (FXTAS) is a progressive degenerative movement disorder characterized by kinetic tremor, cerebellar gait ataxia, parkinsonism, and cognitive decline. This disorder occurs in both males and females, frequently in families with children who have fragile X syndrome. The clinical features of this disorder, both classic and newly described, are summarized in this paper. In screening studies, fragile X mental retardation 1 (*FMRI*) gene premutation (55–200 CGG) expansions are most frequently seen in men with ataxia who have tested negative for spinocerebellar ataxias. Since the original description, the classic FXTAS phenotype has now been reported in females and in carriers of smaller (45–54 CGG) and larger (>200 CGG) expansions in *FMRI*. Premutation carriers may present with a Parkinson disease phenotype or hypotension, rather than with tremor and/or ataxia. Parkinsonism and gait ataxia may also be seen in individuals with gray zone (41–54 CGG) expansions. Studies regarding medication to treat the symptoms in FXTAS are few in number and suggest that medications targeted to specific symptoms, such as kinetic tremor or gait ataxia, may be most beneficial. Great progress has been made in regards to FXTAS research, likely given the readily available gene test and the screening of multiple family members, including parents and grandparents, of fragile X syndrome children. Expansion of genotypes and phenotypes in the disorder may suggest that a broader disease definition might be necessary in the future.

**Keywords:** *FMRI*, FXTAS, genetics, ataxia, gray zone, premutation

**Citation:** Hall DA, O'Keefe JA. Fragile X-associated tremor ataxia syndrome: the expanding clinical picture, pathophysiology, epidemiology, and update on treatment. *Other Hyperkinet Mov* 2012;2: <http://tremorjournal.org/article/view/56>

\*To whom correspondence should be addressed. E-mail: Deborah\_A\_Hall@rush.edu

**Editor:** Elan D. Louis, Columbia University, United States of America

**Received:** August 8, 2011 **Accepted:** November 21, 2011 **Published:** May 11, 2012

**Copyright:** © 2012 Hall et al. This is an open-access article distributed under the terms of the Creative Commons Attribution–Noncommercial–No Derivatives License, which permits the user to copy, distribute, and transmit the work provided that the original author(s) and source are credited; that no commercial use is made of the work; and that the work is not altered or transformed.

**Funding:** This work was funded by NS052487 (D.H.), and a Parkinson Research Center grant from the Parkinson's Disease Foundation.

**Competing Interests:** The authors report no conflict of interest.

## Introduction

Fragile X-associated disorders cause significant morbidity and include inherited intellectual disability, infertility, early menopause, and a variety of neurodegenerative signs. Although pediatricians and pediatric specialists were initially most likely to encounter individuals with fragile X-associated disorders, the discovery of fragile X-associated tremor/ataxia syndrome (FXTAS) has led older adults with fragile X-associated movement disorders to adult neurologists for diagnosis and treatment. This review summarizes the history of FXTAS, the salient clinical features, epidemiology, pathophysiology, newer clinical research findings in the disease, and approaches to treatment.

## Discovery of FXTAS

FXTAS, pronounced “*fax-tas*”, was first discovered and reported in 2001 by Dr. Randi Hagerman, a developmental pediatrician, who

followed patients and their families in the Fragile X Clinic and Research Program at the Children's Hospital in Denver, Colorado. Fragile X syndrome (FXS) is a neurodevelopmental disorder and is the most common inherited cause of intellectual disability. It is caused by an expansion (>200) in the trinucleotide (CGG) repeat elements located in the promoter region of the fragile X mental retardation 1 (*FMRI*) gene. Dr. Hagerman received family reports of progressive tremors, balance problems, frequent falling, and cognitive decline in some grandfathers of children with FXS. After seeing tremor in several of these grandfathers who were bringing their grandsons into the clinic, she sent them to her colleague, Dr. Maureen Leehey (movement disorders neurologist), at the University of Colorado and they published the initial description of the disorder.<sup>1</sup> These individuals (and their daughters) have a fragile X “premutation”, defined as 55–200 CGG repeats in the 5'-untranslated region of the *FMRI* allele.<sup>2</sup> The premutation can expand in later generations to a full mutation

(>200 CGG repeats) and FXS. The name “fragile X- associated tremor/ataxia syndrome (FXTAS)” was given to this new movement disorder.<sup>2</sup>

### Overview of the classic features of FXTAS

The classic phenotype of FXTAS is kinetic tremor and cerebellar gait ataxia in male *FMRI* premutation carriers over the age of 50. Kinetic tremor is a common finding in persons with FXTAS but has variable severity.<sup>3</sup> In male carriers, at least 50% have mild tremor and 17% have moderate tremor, which can be similar in appearance to essential tremor. In FXTAS patients with parkinsonism resting tremor is uncommon, but 57% have mild bradykinesia and 71% have rigidity.<sup>3</sup> Clinical features also include peripheral neuropathy (60%), impotence (80%), bowel and bladder dysfunction (30–55%), erectile dysfunction, lower limb proximal muscle weakness, hearing loss, and dysphagia.<sup>1–4</sup> Progressive cognitive decline and neuropsychological problems are common, including memory loss, anxiety, mood lability, apathy, reclusive behavior/social phobias, and executive function deficits.<sup>5–7</sup> Significant dementia may occur as well.<sup>2</sup> The cognitive dysfunction in FXTAS is one of frontal-subcortical dementia that typically develops after the onset of the movement disorder.<sup>8,9</sup> Although kinetic tremor and cerebellar gait ataxia are the principle clinical features of FXTAS, some patients may initially present with other signs, such as peripheral neuropathy.<sup>10</sup>

Because of the variety of clinical symptoms in FXTAS and the fact that the disorder has been recognized for a relatively short time, patients with FXTAS are frequently initially diagnosed with other disorders such as Parkinson disease (PD), tremor, ataxia, dementia, and/or cerebrovascular disease.<sup>11</sup> Diagnostic testing for FXTAS is accomplished using polymerase chain reaction (PCR) to determine *FMRI* CGG repeat size. *FMRI* PCR is highly sensitive and available at many commercial and academic laboratories.

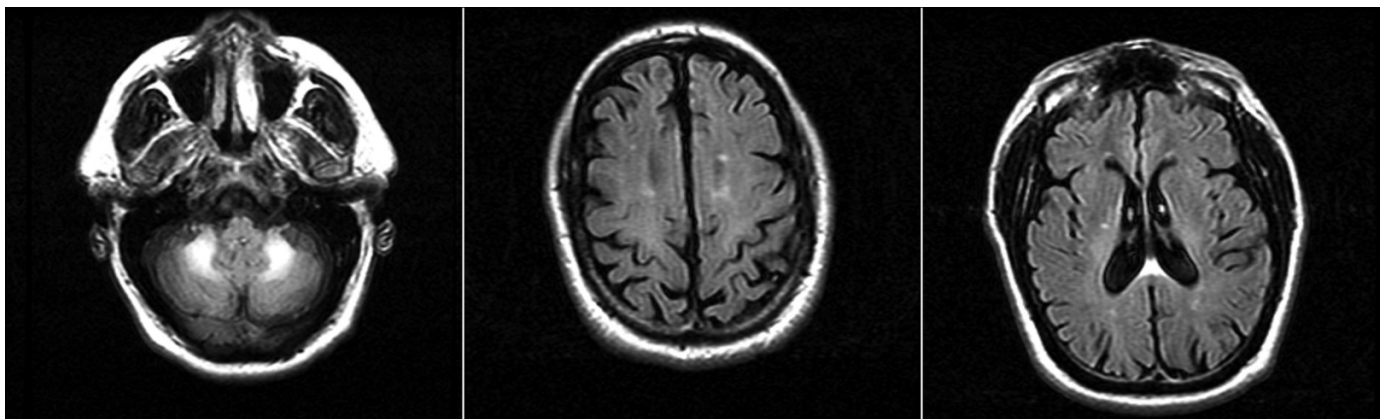
FXTAS tends to progress from mild ataxia and/or tremor to disabling motor and cognitive impairments significantly compromising the individual's ability to function independently in society.<sup>3</sup> FXTAS has age-dependent penetrance, with approximately 30% of male

premutation carriers over the age of 50 having the disorder and over 75% of male premutation carriers over the age of 75 manifesting symptoms.<sup>3,12</sup> Individuals with small premutation alleles (<70 CGG repeats) are much less likely to develop FXTAS.<sup>13</sup>

Individuals with FXTAS have distinct neuroimaging and neuropathological profiles. Patients with FXTAS demonstrate moderate to severe generalized brain atrophy with ventricular enlargement, specific cerebellar atrophy, and subcortical and/or pontocerebellar white matter lesions.<sup>2,14,15</sup> While further research is needed, approximately 60% of males with FXTAS have white matter lesions or hyperintensities on T2-weighted magnetic resonance imaging (MRI) in the middle cerebellar peduncles, termed the “MCP sign”(Figure 1).<sup>14</sup> The MCP sign is a major radiologic feature of FXTAS, but it has also been reported in multiple system atrophy,<sup>16,17</sup> recessive ataxia,<sup>17</sup> and acquired hepatocerebral degeneration.<sup>18</sup> Recently, patients with FXTAS have been shown to have significant pathology via diffusion tensor imaging in multiple white matter tracts, including the middle cerebellar peduncle, superior cerebellar peduncle, cerebral peduncles, the fornix, and stria terminalis.<sup>19</sup> After a study, including imaging, of 26 male premutation carriers with symptoms of FXTAS was performed, provisional diagnostic criteria for FXTAS were proposed based on clinical and radiological criteria (Table 1).<sup>2</sup>

### Pathophysiology of FXTAS

Intranuclear inclusions in both neurons and astrocytes throughout the cerebrum (most numerous in the hippocampus), in the thalamus, basal ganglia (including the substantia nigra), inferior olive and dentate nuclei are found via postmortem analysis in the brains of individuals with FXTAS (Figure 2).<sup>20</sup> The spinal cord, autonomic ganglia and cranial nerve nucleus XII also demonstrate intranuclear inclusions.<sup>21</sup> Although Purkinje cells rarely have inclusions, there is neurodegeneration in the cerebellum, with marked Purkinje cell loss, axonal swelling, and gliosis. Recent reports show widespread non-central nervous system organ pathology, including inclusions, in the endocrine organs, gastrointestinal tract, heart, and kidney.<sup>22</sup>



**Figure 1.** Axial Fluid Attenuated Inversion Recovery (FLAIR) Magnetic Resonance Imaging in a FXTAS Patient.(A) Hyperintensity in the middle cerebellar peduncle; (B,C) global volume loss with scattered white matter hyperintensities. FXTAS, Fragile X-associated tremor ataxia syndrome.

**Table 1.** Diagnostic Criteria for FXTAS

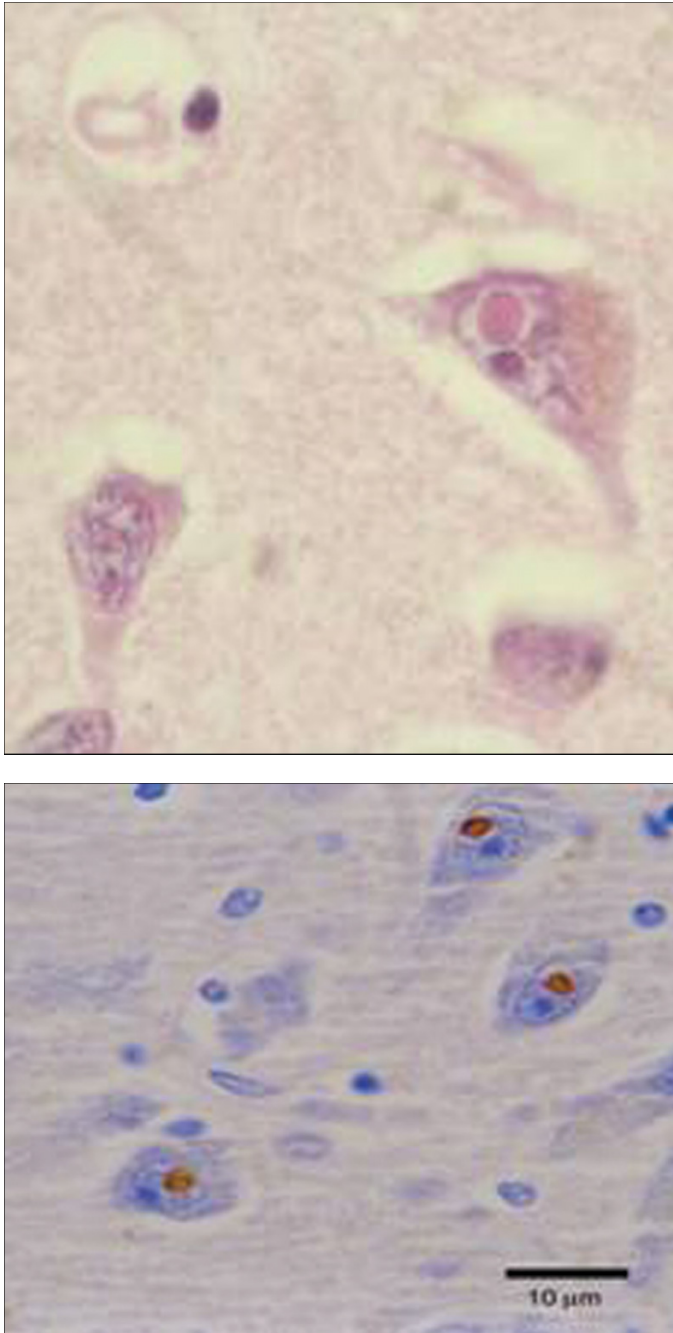
<b>Molecular</b>	<b>FMRI CGG Repeat Size 55–200</b>
<b>Clinical</b>	
Major signs	Intention tremor
	Gait ataxia
Minor signs	Parkinsonism
	Moderate to severe short term memory deficits
	Executive function deficits
<b>Radiological</b>	
Major signs	MRI white matter lesions in the middle cerebellar peduncle (MCP sign)
Minor signs	MRI white matter lesions in cerebral white matter
	Moderate to severe generalized atrophy
<b>Diagnostic Categories</b>	
<b>Definite</b>	Presence of one major radiological sign plus one major clinical symptom
<b>Probable</b>	Presence of either one major radiological sign plus one minor clinical symptom or has two major clinical symptoms
<b>Possible</b>	Presence of one minor radiological sign plus one major clinical symptom
Abbreviations: <i>FMRI</i> , fragile X mental retardation I; FXTAS, Fragile X-associated tremor/ataxia syndrome; MCP, middle cerebellar peduncles; MRI, magnetic resonance imaging	
Adapted from Jacquemont et al, 2003. <sup>2</sup>	

Research into the pathophysiological mechanisms causing FXTAS is progressing at a rapid pace. The full *FMRI* mutation (>200 CGG repeats) causes hypermethylation and transcriptional silencing of the *FMRI* gene and lack of its protein product, fragile X mental retardation protein (FMRP), an important modulator of neural development and synaptic plasticity. However, premutation carriers (55–200 repeats) have elevated *FMRI* mRNA levels and compelling evidence suggests that excess mRNA causes a neurotoxic gain of function effect, which is very different mechanistically than what occurs in full mutation carriers. Those with allele repeat sizes between 55 and 100 have a two- to fourfold increase in *FMRI* mRNA levels and low normal to normal levels of FMRP in blood lymphocytes, while those with longer CGG repeats (100–200) have 4–10 times elevated *FMRI* mRNA and mildly reduced FMRP levels.<sup>23</sup> Incidentally, female premutation carriers also have elevated mRNA levels even though FXTAS was originally thought to be found only in males.<sup>24,25</sup> The RNA toxic gain of function may dysregulate neuronal and astrocyte function and cause eventual cell death. This occurs in numerous places including the limbic system, cerebral cortex, cerebellum, brainstem, and peripheral autonomic ganglia.<sup>26</sup> Greater RNA toxic effects may be associated with molecular findings, as larger repeat sizes correlate

positively with degree of central nervous system neuropathology,<sup>27</sup> and higher repeat sizes and mRNA levels correlate positively with electrical measures of peripheral neuropathy.<sup>28</sup> *FMRI* mRNA has been detected in the ubiquitin-positive intranuclear inclusions found in neurons and astrocytes throughout the brain of FXTAS patients, adding credibility to the role of RNA toxicity in the disorder.<sup>29</sup>

### Epidemiology of FXTAS

The *FMRI* premutation occurs in approximately 1/250 females and 1/800 males, while the full mutation is much more rare (1/2500–4000).<sup>30–32</sup> Ongoing newborn screening studies may increase the prevalence as diagnostic methods have improved since some of these large population screening studies were conducted. Once FXTAS was described, many neurologists screened banked DNA or tested patients sequentially to identify premutation carriers in their clinic populations. Most of the studies focused on phenotypes that were reported in the original case series, such as tremor, ataxia, or parkinsonism. Twenty-nine studies have now reported the results of screening movement disorder patients for *FMRI* expansions.<sup>33–62</sup> These screening studies include patients with ataxia,<sup>33–34,46,48,52,56,61,62</sup> spinocerebellar ataxia (SCA),<sup>40–41,45–46,54–55,57–58</sup> multiple system atrophy,<sup>36,50,58,60</sup>



**Figure 2.** FXTAS Pathology. (A) Hematoxylin and eosin-stained sections of cerebrum with eosinophilic neuronal intranuclear inclusions ranging in size from 2 to 5 µm (original magnification 1000×). (B) Intranuclear inclusions stained with anti-ubiquitin antibodies (original magnification 1000×). FXTAS, Fragile X-associated tremor ataxia syndrome.

Friedreich's ataxia,<sup>40</sup> parkinsonism,<sup>37,41,44,47,49–51,56,62</sup> autonomic dysfunction,<sup>36</sup> essential tremor,<sup>35,51,58,62</sup> and Huntington disease-like phenotypes.<sup>42,43</sup>

The prevalence of premutation range expansions ranged from 0 to 4% in individuals with ataxia,<sup>33,40,42,46,48,52,55–59,61</sup> with the highest

proportions seen in adult onset ataxia (2.2%),<sup>34</sup> ataxia patients with negative SCA gene testing (4%),<sup>45</sup> and male ataxia patients with negative SCA testing (5%).<sup>54</sup> Premutation frequencies ranged from 0 to 4% in multiple system atrophy<sup>36,38,58,60</sup> and 0 to 1% in parkinsonism cohorts.<sup>37,39,41,44,47,49,53,56,62</sup> No premutation carriers were ascertained in essential tremor patients<sup>35,51,58,62</sup> or Friedreich's ataxia patients.<sup>40</sup>

These prevalence suggest that *FMRI* premutation expansions are not a significant cause of movement disorders in these populations. The reasons for this may be that these studies excluded individuals with the premutation phenotype. For example, many PD DNA repositories exclude individuals with cerebellar signs. Other reasons may include lack of insight of patients with FXTAS into their neurological symptoms and the fact that very few are referred to movement disorder specialists.<sup>11</sup>

### FXTAS in females and full mutation carriers

Since the original description of FXTAS, there have been case reports and studies that describe phenotypes that vary from the original diagnostic criteria (Table 1). Although FXTAS was originally described in males, females with FXTAS have now been reported. The first study described five female premutation carriers who had tremor and ataxia, but only one had a MCP sign on MRI.<sup>25</sup> Subsequent studies suggest that only 13% of females affected with FXTAS have the MCP sign.<sup>63</sup> Initial case-control studies did not show an association of tremor and ataxia in female premutation carriers,<sup>12,64</sup> likely because of lower manifestation of signs due to X-inactivation effects. However, the penetrance of FXTAS in female premutation carriers may be closer to 16.5% in families with other identified fragile X-associated disorders.<sup>65</sup> More recent case reports have described female carriers with typical FXTAS,<sup>66</sup> with FXTAS and spasmodic dysphonia<sup>67</sup> and with FXTAS and multiple sclerosis.<sup>68</sup> Interestingly, a 23-year-old female premutation carrier (CGG=100) was reported with autism, levodopa-responsive parkinsonism, ataxia, and hyperintensities on T2-weighted MRI images in the basis pontis and MCP.<sup>69</sup>

Other medical comorbidities may be more common in female premutation carriers with and without FXTAS, to include thyroid disease, hypertension, seizures, and fibromyalgia,<sup>70</sup> but a similar study done by another group did not show these associations.<sup>71</sup> Additionally, daughters of males with FXTAS are more likely to report balance problems and neurological symptoms than daughters of premutation carrier fathers without FXTAS,<sup>72</sup> suggesting that secondary gene effects, ascertainment, or other issues may be causing the conflicting results.

Evidence now suggests that full *FMRI* mutation carriers may also have signs or symptoms of FXTAS. The pathophysiology of FXTAS is thought to involve toxic *FMRI* mRNA and full mutation carriers have little or no *FMRI* mRNA, so they are not expected to develop FXTAS. However, individuals with the full mutation that have size mosaicism (cells that have different sizes of CGG expansions) or an unmethylated mutant allele (which is transcribed), would be at risk for FXTAS given the presence of toxic mRNA.

FXTAS was reported in a male carrier of an unmethylated full mutation in the *FMRI* gene.<sup>73</sup> The 65-year-old alcoholic *FMRI* mutation carrier (CGG 297–480) had a 10-year history of cerebellar gait ataxia, kinetic tremor, parkinsonism, and cognitive decline. In addition, he had the MCP sign and met criteria for FXTAS, with the exception of a CGG repeat size larger than the premutation range. Rare intranuclear inclusions have also been reported in the brains of three older adult males with FXS, one of whom had gait ataxia and parkinsonism.<sup>22</sup> This man had CGG repeat sizes of 339–1225, but without a MRI report, it is unclear if he met diagnostic criteria for FXTAS (Table 1).

### Other features seen in premutation carriers

Premutation carriers may have other clinical features or neurological symptoms but not meet criteria for FXTAS. Although individuals with FXTAS frequently have parkinsonism, many of them have features unusual for idiopathic PD, like the presence of cerebellar gait ataxia and prominent kinetic tremor. However, there have now been reported *FMRI* premutation carriers with a PD phenotype who lacked cerebellar gait ataxia, responded to dopaminergic medications, and even developed motor fluctuations.<sup>74</sup> Three *FMRI* expansion carriers with parkinsonism with normal 2 $\beta$ -carbomethoxy-3 $\beta$ -(4-iodophenyl) tropane single photon emission computed tomography ( $\beta$ -CIT SPECT) imaging suggest that the parkinsonism related to premutation carrier status may not be a presynaptic dopamine deficit, unlike typical PD.<sup>75</sup> White matter changes in the basis pontis, in addition to the MCP sign, have also been reported in two male premutation carriers: one with a PD phenotype and one with typical FXTAS.<sup>15</sup>

Several other case reports illustrate the heterogeneity of neurological phenotypes in adult *FMRI* premutation carriers. Two patients presenting with postprandial hypotension have been described: one with kinetic tremor and the MCP sign and the other having a PD diagnosis with falls and syncope.<sup>76,77</sup> The latter case had intraneuronal inclusions, characteristic of FXTAS on autopsy.<sup>78</sup> Another *FMRI* premutation carrier with prominent paraparesis, hyperreflexia, and flexor plantar responses was described,<sup>48</sup> but these signs have not been described in other premutation carriers.

Premutation carriers who do not have FXTAS can have other signs typically seen in FXS; including intellectual disability, autism, hyperactivity, perseverative behaviors, and tactile defensiveness.<sup>78</sup> Seizures were more common in premutation carriers than in controls in a family survey.<sup>79</sup> In addition, cognitive deficits can be seen across the life span in premutation carriers without FXTAS.<sup>6,7,80</sup> Specific executive function and memory deficits are observed, including poor inhibitory control, working memory deficits, and poor planning skills.<sup>6</sup> It has been proposed that these early cognitive impairments may be indicative of later onset of FXTAS.<sup>6</sup> However, other groups have not found this association.<sup>81</sup>

Some asymptomatic male premutation carriers have brain (including hippocampal) atrophy, reduced brainstem size, and ventricular enlargement that may be early predictors of FXTAS development.<sup>27,82</sup> In addition, reduced hippocampal volume correlates with anxiety in

female premutation carriers and with paranoia in carrier males, with and without FXTAS.<sup>63</sup> Brain imaging studies have shown that male premutation carriers with cognitive and psychiatric dysfunction (but not full FXTAS) demonstrate reduced amygdala activation when viewing fearful faces<sup>83</sup> and reduced hippocampal activation during recall tasks.<sup>84</sup>

### Gray zone controversies

Smaller expansions in the *FMRI* gene have been termed “gray zone” or intermediate alleles based on the lower likelihood of the CGG repeat increasing and causing FXS in later generations. Gray zone alleles have been reported to expand over two generations to a full mutation, but typically it takes at least three generations.<sup>85–87</sup> The American College of Medical Genetics practice guidelines define the intermediate zone or gray zone alleles as 41–60 CGG repeats.<sup>88</sup> However, 45–54 CGG repeats have been designated the intermediate or gray zone by the laboratory practice committee of the American College of Medical Genetics.<sup>89,90</sup> This discrepancy in the definition of the gray zone has become more important given that several studies are now reporting phenotypes associated with gray zone or intermediate allele sizes. The prevalence of repeat expansions is 0.3% in the 41–54 CGG range and 2.6% in the 40–59 range in the general population.<sup>30,32,91</sup> Gray zone carriers of 45–54 CGG repeats can have up to 1.5-fold increase in *FMRI* mRNA, with transcript levels of *FMRI* mRNA starting to increase at just 39 CGG repeats.<sup>92</sup>

Gray zone alleles have been associated with special educational needs in children and primary ovarian insufficiency, similar to phenotypes seen in larger repeat expansion carriers.<sup>93,94</sup> Gray zone expansions have also been reported in some movement disorder populations. The prevalence of gray zone expansion vary, with proportions of around 1% reported in studies screening individuals with a multiple system atrophy phenotype,<sup>36</sup> 1–7.5% in individuals with parkinsonism,<sup>44,49,53</sup> and 0–11% in idiopathic PD.<sup>47,50–51,62</sup> However, the studies were mixed in whether the proportions of gray zone expansions were elevated relative to control patients collected in the studies.<sup>50,53,62</sup> Gray zone expansions were reported in 5% of individuals with late onset cerebellar ataxia after the age 50 (with negative SCA testing),<sup>61</sup> 1.5% in those with essential tremor,<sup>51</sup> and 3% in a mixed cohort of males with ataxia, parkinsonism, and tremor.<sup>56</sup> A screen of 228 Australian males with PD showed a rate of 7.5% CGG gray zone alleles compared to 3% gray zone alleles in 578 consecutive newborns.<sup>53</sup> A second study showed 11% of 98 females with PD had gray zone alleles (41–54 repeats) compared to female controls at 4.4%, with an odds ratio of 3.23 (p=0.019).<sup>62</sup> In contrast, a similar screening study in southern Spain showed that 206 PD patients and 227 controls both had a rate of 6% gray zone alleles (45–54 CGG repeats).<sup>50</sup>

A study of a family of *FMRI* repeat expansion carriers with broad clinical involvement describes a gray zone carrier with 52 CGG repeats with subtle tremor and balance problems, but milder than what is seen in FXTAS.<sup>78</sup> Imaging was not reported. In addition, three gray zone carriers who meet criteria for FXTAS have been described.<sup>62</sup> Like the earlier studies, which may expand the phenotype

of FXTAS, better characterization of gray zone carriers with neurological signs and symptoms may show that these individuals also have a FXTAS-like phenotype or other fragile X-associated movement disorders.

The description of individuals with genotypes or phenotypes that do not fit into the original diagnostic criteria of FXTAS suggest that the definition of FXTAS may need to be broadened. Clinical and genetic heterogeneity frequently increases in newly described genetic disorders as additional cases are identified so this is not unexpected.

### Treatment

Currently, there are no specific disease-modifying medical treatments for patients with FXTAS. Theoretically, drugs that would prevent or counteract the excess of *FMRI* mRNA might be beneficial in preventing the neurotoxic cascade. Studies have shown that histone acetyltransferase inhibitors reduce *FMRI* mRNA to normal levels and suppress CGG repeat neurotoxicity in a *Drosophila* model of FXTAS.<sup>95</sup> This may lead to histone acetylation modulating drugs or other pharmaceuticals that normalize *FMRI* mRNA levels in future clinical trials for FXTAS.

The present medical management of patients with FXTAS is limited to medications employed to alleviate the symptoms of tremor, ataxia, mood changes, anxiety, cognitive decline and/or dementia, neuropathic pain and/or fibromyalgia. Some patients with FXTAS have shown improvement in gait ataxia with amantadine in anecdotal reports,<sup>96</sup> varenicline at 0.5–1 mg per day (n=1),<sup>97</sup> or with riluzole 100 mg daily (n=1).<sup>98</sup> However, anecdotal reports suggest that varenicline may exacerbate tremor and psychiatric symptoms in some patients.<sup>99</sup> The most comprehensive medication study conducted in FXTAS was a questionnaire study where 58 FXTAS patients rated improvement in various neurological symptoms.<sup>100</sup> Many patients (70%) with possible or probable FXTAS were not taking medications for their symptoms. However, some FXTAS patients with both ataxia and parkinsonism subjectively reported dopaminergic medications improved their balance.<sup>100</sup> Beta-blockers, primidone, and topiramate are used to treat essential tremor and these were found to subjectively improve kinetic tremor in other FXTAS patients.<sup>100</sup> Levetiracetam has also been reported to help kinetic tremor in a FXTAS patient in a case report.<sup>101</sup> Because anxiety and stress aggravate or worsen tremor, benzodiazepines might be beneficial in certain patients, especially those with anxiety disorders.<sup>3</sup>

A slowing of cognitive decline in individuals with FXTAS using acetylcholinesterase inhibitors has been reported by caregivers.<sup>100</sup> Combination therapies of donepezil and venlafaxine for a 2-year duration have been reported to improve and stabilize the dementia and mood alterations (depression, anxiety, agitation, hostility, and irritability) in a case report of a FXTAS patient who had multiple neurological symptoms.<sup>102</sup> Venlafaxine has been reported anecdotally to be useful for treating depression, anxiety, agitation, hostility, and irritability in a few patients with FXTAS.<sup>103</sup> Recently, a combination

of memantine and venlafaxine treatment was found to improve tremor, balance, neuropathy, depression, anxiety, and cognitive function (auditory recall, oral word association, and executive functions) in case report of a female with FXTAS.<sup>104</sup>

Neurological rehabilitative therapies have not been studied specifically in FXTAS but should be considered in treatment. Those with dysphagia have an increased risk of aspiration and in these cases routine monitoring of swallowing by a speech therapist, including barium swallowing tests, is indicated,<sup>105</sup> and appropriate feeding therapy should be provided. In patients who develop dysarthria, speech therapy may be beneficial, especially in finding means of augmentative or alternative communication. *FMRI* premutation carriers may be at higher risk to have hearing loss so those affected should be referred to audiology for testing and provision of hearing devices if appropriate.

Occupational and physical therapy may be beneficial for FXTAS patients with tremor, gait and balance deficits, poor mobility, and difficulty performing functional tasks. Assistive technology to aid feeding and computer use in patients with intention tremor is frequently employed by neurorehabilitation specialists.<sup>106,107</sup> Increasing the inertia or viscoelastic resistance of a limb will dampen kinetic tremors and gait ataxia due to cerebellar disease.<sup>108,109</sup> Interventions directed at this include trunk or extremity loading with weights<sup>109–112</sup> and use of trunk vests and Lycra garments to provide proximal limb and trunk stability.<sup>113–115</sup> Disability scores and quality of life stabilized and depression improved in patients with SCA3 after 15 sessions of occupational therapy using coordination exercise protocols and these effects lasted for at least 6 months after treatment.<sup>116</sup>

Significant improvements in balance, gait ataxia, and stable achievement of activities of daily living were found following a 4-week intensive physical therapy program in patients with degenerative cerebellar ataxias of varying causes.<sup>117</sup> Moreover, these changes persisted, albeit at a lower level, for 1 year during which time the patients performed a daily home exercise program, despite an increase in ataxia and gradual decline in motor performance over this same time period.<sup>118</sup> These researchers suggest that the improvements achieved by training were equivalent to gaining back functional performance of 2 years of neurodegenerative disease progression. Body weight supported treadmill training for gait deficits including ataxia<sup>119–125</sup> and specific balance protocols using computerized dynamic posturography (CDP) with biofeedback retraining devices based on altering visual, somatosensory, and vestibular feedback are relatively newer devices used in the treatment of patients with balance disorders<sup>126–131</sup> and may be helpful in FXTAS patients.

Many men with FXTAS report dizziness<sup>3</sup> as well as female premutation carriers without FXTAS.<sup>132</sup> It is not yet known whether this is due to orthostasis, vestibular dysfunction, or both.<sup>3</sup> Testing with CDP would help determine whether dizziness is related to vestibular function and could be treated with vestibular rehabilitation protocols by specialized balance therapists.

### Summary/Discussion

Given the discovery of FXTAS in 2001, the advancement of knowledge in this disorder has occurred very quickly. Extensive cascade genetic testing, where testing in families with FXS probands leads to the identification of obligate premutation carriers and at-risk individuals, has accelerated the research advances in this field. The willingness of premutation carriers to participate in research and the collaboration of fragile X experts has also been beneficial. There are currently several studies testing agents to normalize molecular pathways in FXS. Our hope is that studies with agents that target the premutation pathologies are not far behind.

### Acknowledgements

We would like to thank Elizabeth Berry-Kravis and Glenn Stebbins for providing images, Claudia Greco for the pathology, and Bernadette Gillard for assistance with manuscript preparation.

### References

- Hagerman RJ, Leehey M, Heinrichs W, et al. Intention tremor, parkinsonism, and generalized brain atrophy in male carriers of fragile X. *Neurology* 2001;57:127–130.
- Jacquemont S, Hagerman RJ, Leehey M, et al. Fragile X premutation tremor/ataxia syndrome: molecular, clinical, and neuroimaging correlates. *Am J Hum Genet* 2003;72:869, <http://dx.doi.org/10.1086/374321>.
- Leehey MA, Berry-Kravis E, Min SJ, et al. Progression of tremor and ataxia in male carriers of the FMR1 premutation. *Mov Disord* 2007;22:203–206, <http://dx.doi.org/10.1002/mds.21252>.
- Juncos JL, Lazarus JT, Graves-Allen E, et al. New clinical findings in the fragile X-associated tremor ataxia syndrome (FXTAS). *Neurogenetics* 2011;12:123–135, <http://dx.doi.org/10.1007/s10048-010-0270-5>.
- Bourgeois JA, Seritan AL, Casillas EM, et al. Lifetime prevalence of mood and anxiety disorders in fragile X premutation carriers. *J Clin Psychiatry* 2011;72:175–182, <http://dx.doi.org/10.4088/JCP.09m05407blu>.
- Cornish KM, Kogan CS, Li L, Turk J, Jacquemont S, Hagerman RJ. Lifespan changes in working memory in fragile X premutation males. *Brain Cogn* 2009;69:551–558, <http://dx.doi.org/10.1016/j.bandc.2008.11.006>.
- Grigsby J, Brega AG, Engle K, et al. Cognitive profile of fragile X premutation carriers with and without fragile X-associated tremor/ataxia syndrome. *Neuropsychology* 2008;22:48–60, <http://dx.doi.org/10.1037/0894-4105.22.1.48>.
- Bacalman S, Farzin F, Bourgeois JA, et al. Psychiatric phenotype of the fragile X-associated tremor/ataxia syndrome (FXTAS) in males: newly described fronto-subcortical dementia. *J Clin Psychiatry* 2006;67:87, <http://dx.doi.org/10.4088/JCP.v67n0112>.
- Grigsby J, Brega AG, Jacquemont S, et al. Impairment in the cognitive functioning of men with fragile X-associated tremor/ataxia syndrome (FXTAS). *J Neurol Sci* 2006;248(1–2):227–233, <http://dx.doi.org/10.1016/j.jns.2006.05.016>.
- Hagerman RJ, Coffey SM, Maselli R, et al. Neuropathy as a presenting feature in fragile X-associated tremor/ataxia syndrome. *Am J Med Genet A* 2007;143A:2256–2260, <http://dx.doi.org/10.1002/ajmg.a.31920>.
- Hall DA, Berry-Kravis E, Jacquemont S, Rice CD, Cogswell JB, Zhang L. Prior diagnoses given to persons with the Fragile X-associated tremor/ataxia syndrome. *Neurology* 2005;65:299–301, <http://dx.doi.org/10.1212/01.wnl.0000168900.86323.9c>.
- Jacquemont S, Hagerman RJ, Leehey MA, et al. Penetrance of the fragile X-associated tremor/ataxia syndrome in a premutation carrier population. *JAMA* 2004;291:460, <http://dx.doi.org/10.1001/jama.291.4.460>.
- Leehey MA, Berry-Kravis E, Goetz CG, et al. FMR1 CGG repeat length predicts motor dysfunction in premutation carriers. *Neurology* 2008;70(Pt 2):1397–1402, <http://dx.doi.org/10.1212/01.wnl.0000281692.98200.f5>.
- Brunberg JA, Jacquemont S, Hagerman RJ, et al. Fragile X premutation carriers: characteristic MR imaging findings of adult male patients with progressive cerebellar and cognitive dysfunction. *AJNR Am J Neuroradiol* 2002;23:1757–1766.
- Loesch DZ, Kotschet K, Trost N, et al. White matter changes in basis pontis in small expansion FMR1 allele carriers with parkinsonism. *Am J Med Genet B Neuropsychiatr Genet* 2011;156B:502–506.
- Schrag A, Kingsley D, Phatouros C, et al. Clinical usefulness of magnetic resonance imaging in multiple system atrophy. *J Neurol Neurosurg Psychiatry* 1998;65:65–71, <http://dx.doi.org/10.1136/jnnp.65.1.65>.
- Storey E, Knight MA, Forrest SM, Gardner RJ. Spinocerebellar ataxia type 20. *Cerebellum* 2005;4:55–57, <http://dx.doi.org/10.1080/14734220410019048>.
- Lee J, Lacomis D, Comu S, Jacobsohn J, Kanal E. Acquired hepatocerebral degeneration: MR and pathologic findings. *AJNR Am J Neuroradiol* 1998;19:485–487.
- Hashimoto R, Srivastava S, Tassone F, Hagerman RJ, Rivera SM. Diffusion tensor imaging in male premutation carriers of the fragile X mental retardation gene. *Mov Disord* 2011;26:1329–1336, <http://dx.doi.org/10.1002/mds.23646>.
- Greco CM, Hagerman RJ, Tassone F, et al. Neuronal intranuclear inclusions in a new cerebellar tremor/ataxia syndrome among fragile X carriers. *Brain* 2002;125:1760–1771, <http://dx.doi.org/10.1093/brain/awf184>.
- Hunsaker MR, Greco CM, Spath MA, et al. Widespread non-central nervous system organ pathology in fragile X premutation carriers with fragile X-associated tremor/ataxia syndrome and CGG knock-in mice. *Acta Neuropathol* 2011;122:467–479, <http://dx.doi.org/10.1007/s00401-011-0860-9>.
- Hunsaker MR, Greco CM, Spath MA, et al. Widespread non-central nervous system organ pathology in fragile X premutation carriers with fragile X-associated tremor/ataxia syndrome and CGG knock-in mice. *Acta Neuropathol* 2011;122:467–79, <http://dx.doi.org/10.1007/s00401-011-0860-9>.
- Tassone F, Hagerman RJ, Taylor AK, Gane LW, Godfrey TE, Hagerman PJ. Elevated levels of FMR1 mRNA in carrier males: a new mechanism of involvement in the fragile-X syndrome. *Am J Hum Genet* 2000;66:6–15, <http://dx.doi.org/10.1086/302720>.
- Hagerman RJ, Leavitt BR, Farzin F, et al. Fragile-X-associated tremor/ataxia syndrome (FXTAS) in females with the FMR1 premutation. *Am J Hum Genet* 2004;74:1051, <http://dx.doi.org/10.1086/420700>.
- Arocena DG, Iwahashi CK, Won N, et al. Induction of inclusion formation and disruption of lamin A/C structure by premutation CGG-repeat RNA in human cultured neural cells. *Hum Mol Genet* 2005;14:3661–3671, <http://dx.doi.org/10.1093/hmg/ddi394>.

26. Gokden M, Al-Hinti JT, Harik SI. Peripheral nervous system pathology in fragile X tremor/ataxia syndrome (FXTAS). *Neuropathology* 2009;29:280–284, <http://dx.doi.org/10.1111/j.1440-1789.2008.00948.x>.
27. Cohen S, Masyn K, Adams J, et al. Molecular and imaging correlates of the fragile X-associated tremor/ataxia syndrome. *Neurology* 2006;67:1426–1431, <http://dx.doi.org/10.1212/01.wnl.0000239837.57475.3a>.
28. Soontarapornchai K, Maselli R, Fenton-Farrell G, et al. Abnormal nerve conduction features in fragile X premutation carriers. *Arch Neurol* 2008;65:495–498, <http://dx.doi.org/10.1001/archneur.65.4.495>.
29. Tassone F, Hagerman RJ, Garcia-Arocena D, Khandjian EW, Greco CM, Hagerman PJ. Intranuclear inclusions in neural cells with premutation alleles in fragile X associated tremor/ataxia syndrome. *J Med Genet* 2004;41:e43, <http://dx.doi.org/10.1136/jmg.2003.012518>.
30. Dombrowski C LS, Morel ML, Rouillard P, Morgan K, Rousseau F. Premutation and intermediate-size *FMR1* alleles in 10,572 males from the general population: loss of an AGG interruption is a late event in the generation of fragile X syndrome alleles. *Hum Mol Genet* 2002;11:371–378, <http://dx.doi.org/10.1093/hmg/11.4.371>.
31. Fernandez-Carvajal I, Walichiewicz P, Xiaosen X, Pan R, Hagerman P, Tassone F. Screening for expanded alleles for the *FMR1* gene in blood spots from newborn males in a Spanish population. *J Mol Diagn* 2009;11:371–378, <http://dx.doi.org/10.2353/jmoldx.2009.080132>.
32. Rousseau F, Rouillard P, Morel ML, Khandjian EW, Morgan K. Prevalence of carriers of premutation-size alleles of the *FMR1* gene—and implications for the population genetics of the fragile X syndrome. *Am J Hum Genet* 1995;57:1006–1018.
33. Biancalana V, Toft M, Le Ber I, et al. *FMR1* premutations associated with fragile X-associated tremor/ataxia syndrome in multiple system atrophy. *Arch Neurol* 2005;62:962, <http://dx.doi.org/10.1001/archneur.62.6.962>.
34. Brussino A, Gellera C, Saluto A, et al. *FMR1* gene premutation is a frequent genetic cause of late-onset sporadic cerebellar ataxia. *Neurology* 2005;64:145, <http://dx.doi.org/10.1212/01.WNL.0000148723.37489.3F>.
35. Garcia Arocena D, Louis ED, Tassone F, et al. Screen for expanded *FMR1* alleles in patients with essential tremor. *Mov Disord* 2004;19:930, <http://dx.doi.org/10.1002/mds.20043>.
36. Garland EM, Vnencak-Jones CL, Biaggioni I, Davis TL, Montine TJ, Robertson D. Fragile X gene premutation in multiple system atrophy. *J Neurol Sci* 2004;227:115, <http://dx.doi.org/10.1016/j.jns.2004.08.013>.
37. Hedrich K, Pramstaller PP, Stubke K, et al. Premutations in the *FMR1* gene as a modifying factor in Parkin-associated Parkinson's disease? *Mov Disord* 2005;20:1060, <http://dx.doi.org/10.1002/mds.20512>.
38. Kamm C, Healy DG, Quinn NP, et al. The fragile X tremor ataxia syndrome in the differential diagnosis of multiple system atrophy: data from the EMSA Study Group. *Brain* 2005;128(Pt 8):1855, <http://dx.doi.org/10.1093/brain/awh535>.
39. Kraff J, Tang HT, Cilia R, et al. Screen for excess *FMR1* premutation alleles among males with parkinsonism. *Arch Neurol* 2007;64:1002, <http://dx.doi.org/10.1001/archneur.64.7.1002>.
40. Kraft S, Furtado S, Ranaway R, et al. Adult onset spinocerebellar ataxia in a Canadian movement disorders clinic. *Can J Neurol Sci* 2005;32:450.
41. Kurz MW, Schlitter AM, Klenk Y, et al. *FMR1* alleles in Parkinson's disease: relation to cognitive decline and hallucinations, a longitudinal study. *J Geriatr Psychiatry Neurol* 2007;20:89, <http://dx.doi.org/10.1177/0891988706297737>.
42. Rodriguez-Revenga L, Gomez-Anson B, Munoz E, et al. FXTAS in spanish patients with ataxia: support for female *FMR1* premutation screening. *Mol Neurobiol* 2007;35:324, <http://dx.doi.org/10.1007/s12035-007-0020-3>.
43. Rodriguez-Revenga L, Santos MM, Sanchez A, et al. Screening for FXTAS in 95 Spanish patients negative for Huntington disease. *Genet Test* 2008;12:135–138, <http://dx.doi.org/10.1089/gte.2007.0074>.
44. Toft M, Aasly J, Bisceglia G, et al. Parkinsonism, FXTAS, and *FMR1* premutations. *Mov Disord* 2005;20:230, <http://dx.doi.org/10.1002/mds.20297>.
45. Van Esch H, Dom R, Bex D, et al. Screening for *FMR1* premutations in 122 older Flemish males presenting with ataxia. *Eur J Hum Genet* 2005;13:121, <http://dx.doi.org/10.1038/sj.ejhg.5201312>.
46. Adams SA, Steenblock KJ, Thibodeau SN, Lindor NM. Premutations in the *FMR1* gene are uncommon in men undergoing genetic testing for spinocerebellar ataxia. *J Neurogenet* 2008;22:77–92, <http://dx.doi.org/10.1080/01677060701686242>.
47. Annesi G, Nicoletti G, Tarantino P, et al. FRAXE intermediate alleles are associated with Parkinson's disease. *Neurosci Lett* 2004;368:21–24, <http://dx.doi.org/10.1016/j.neulet.2004.06.049>.
48. Cellini E, Forleo P, Ginestroni A, et al. Fragile X premutation with atypical symptoms at onset. *Arch Neurol* 2006;63:1135–1138, <http://dx.doi.org/10.1001/archneur.63.8.1135>.
49. Cilia R, Kraff J, Canesi M, et al. Screening for the presence of *FMR1* premutation alleles in women with parkinsonism. *Arch Neurol* 2009;66:244–249, <http://dx.doi.org/10.1001/archneur.2008.548>.
50. Costa A, Gao L, Carrillo F, et al. Intermediate alleles at the FRAXA and FRAXE loci in Parkinson's disease. *Park Rel Disord* 2011;17:281–285, <http://dx.doi.org/10.1016/j.parkreldis.2010.12.013>.
51. Deng H, Le W, Jankovic J. Premutation alleles associated with Parkinson disease and essential tremor. *JAMA* 2004;292:1685–1686, <http://dx.doi.org/10.1001/jama.292.14.1685-b>.
52. Kerber KA, Jen JC, Perlman S, Baloh RW. Late-onset pure cerebellar ataxia: differentiating those with and without identifiable mutations. *J Neurolog Sci* 2005;238:41–45, <http://dx.doi.org/10.1016/j.jns.2005.06.006>.
53. Loesch DZ, Khaniani MS, Slater HR, et al. Small CGG repeat expansion alleles of *FMR1* gene are associated with parkinsonism. *Clin Genet* 2009;76:471–476, <http://dx.doi.org/10.1111/j.1399-0004.2009.01275.x>.
54. Macpherson J, Waghorn A, Hammans S, Jacobs P. Observation of an excess of fragile-X premutations in a population of males referred with spinocerebellar ataxia. *Hum Genet* 2003;112:619–620.
55. Rajkiewicz M, Sulek-Piatkowska A, Krysa W, Zdzienicka E, Szirkowicz W, Zaremba J. Screening for premutation in the *FMR1* gene in male patients suspected of spinocerebellar ataxia. *Neurol Neurochir Pol* 2008;42:497–504.
56. Reis AH, Ferreira AC, Gomes KB, et al. Frequency of *FMR1* premutation in individuals with ataxia and/or tremor and/or parkinsonism. *Genet Mol Res* 2008;7:74–84, <http://dx.doi.org/10.4238/vol7-1gmr357>.
57. Seixas AI, Maurer MH, Lin M, et al. FXTAS, SCA10, and SCA17 in American patients with movement disorders. *Am J Med Genet A* 2005;136:87–89.
58. Tan EK, Zhao Y, Puong KY, et al. Expanded *FMR1* alleles are rare in idiopathic Parkinson's disease. *Neurogenetics* 2005;6:51–52, <http://dx.doi.org/10.1007/s10048-004-0200-5>.



59. Wardle M, Majounie E, Muzaimi MB, Williams NM, Morris HR, Robertson NP. The genetic aetiology of late-onset chronic progressive cerebellar ataxia. A population-based study. *J Neurol* 2009;256:343–348, <http://dx.doi.org/10.1007/s00415-009-0015-2>.
60. Yabe I, Soma H, Takei A, Fujik N, Sasaki H. No association between FMR1 premutations and multiple system atrophy. *J Neurol* 2004;251:1411–1412, <http://dx.doi.org/10.1007/s00415-004-0546-5>.
61. Zuhlke C, Budnik A, Gehlken U, et al. FMR1 premutation as a rare cause of late onset ataxia—evidence for FXTAS in female carriers. *J Neurol* 2004;251:1418–1419, <http://dx.doi.org/10.1007/s00415-004-0558-1>.
62. Hall D, Berry-Kravis E, Zhang W, et al. FMR1 gray-zone alleles: Association with Parkinson's disease in Women? *Mov Disord* 2011;26:1900–1906, <http://dx.doi.org/10.1002/mds.23755>.
63. Adams JS, Adams PE, Nguyen D, et al. Volumetric brain changes in females with fragile X-associated tremor/ataxia syndrome (FXTAS). *Neurology* 2007;69:851–859, <http://dx.doi.org/10.1212/01.wnl.0000269781.10417.7b>.
64. Berry-Kravis E, Lewin F, Wu J, et al. Tremor and ataxia in fragile X premutation carriers: blinded videotape study. *Ann Neurol* 2003;53:616–623, <http://dx.doi.org/10.1002/ana.10522>.
65. Rodriguez-Revilla L, Madrigal I, Pagonabarraga J, et al. Penetrance of FMR1 premutation associated pathologies in fragile X syndrome families. *Eur J Hum Genet* 2009;17:1359–1362, <http://dx.doi.org/10.1038/ejhg.2009.51>.
66. Rodriguez-Revilla L, Pagonabarraga J, Gomez-Anson B, et al. Motor and mental dysfunction in mother-daughter transmitted FXTAS. *Neurology* 2010;75:1370–1376, <http://dx.doi.org/10.1212/WNL.0b013e3181f73660>.
67. Horvath J, Burkhard PR, Morris M, Bottani A, Moix I, Delavelle J. Expanding the phenotype of fragile X-associated tremor/ataxia syndrome: a new female case. *Mov Disord* 2007;22:1677–1678, <http://dx.doi.org/10.1002/mds.21571>.
68. Zhang L, Coffey S, Lua LL, et al. FMR1 premutation in females diagnosed with multiple sclerosis. *J Neurol Neurosurg Psychiatry* 2009;80:812–814, <http://dx.doi.org/10.1136/jnnp.2008.160960>.
69. Sarac H, Henigsberg N, Markeljevic J, Pavlisa G, Hof PR, Simic G. Fragile X-premutation tremor/ataxia syndrome (FXTAS) in a young woman: clinical, genetics, MRI and 1H-MR spectroscopy correlates. *Coll Antropol* 2011;35(Suppl 1):327–332.
70. Coffey SM, Cook K, Tartaglia N, et al. Expanded clinical phenotype of women with the FMR1 premutation. *Am J Med Genet A* 2008;146A:1009–1016, <http://dx.doi.org/10.1002/ajmg.a.32060>.
71. Hunter JE, Rohr JK, Sherman SL. Co-occurring diagnoses among FMR1 premutation allele carriers. *Clin Genet* 2010;77:374–381, <http://dx.doi.org/10.1111/j.1399-0004.2009.01317.x>.
72. Chonchaiya W, Nguyen DV, Au J, et al. Clinical involvement in daughters of men with fragile X-associated tremor ataxia syndrome. *Clin Genet* 2010;78:38–46, <http://dx.doi.org/10.1111/j.1399-0004.2010.01448.x>.
73. Loesch D, Sherwell S, Kinsella G, et al. Fragile X-associated tremor/ataxia phenotype in a male carrier of unmethylated full mutation in the FMR1 gene. *Clin Genet* 2011;DOI:<http://dx.doi.org/10.1111/j.1399-0004.2011.01675.x>.
74. Hall DA, Howard K, Hagerman RJ, Lechey MA. Parkinsonism in FMR1 premutation carriers may be indistinguishable from Parkinson disease. *Parkinsonism Relat Disord* 2009;15:156–159, <http://dx.doi.org/10.1016/j.parkreldis.2008.04.037>.
75. Hall DA, Jennings D, Seibyl J, Tassone F, Marek K. FMR1 gene expansion and scans without evidence of dopaminergic deficits in parkinsonism patients. *Parkinsonism Relat Disord* 2010;16:608–611, <http://dx.doi.org/10.1016/j.parkreldis.2010.07.006>.
76. Louis E, Moskowitz C, Friez M, Amaya M, Vonsattel JP. Parkinsonism, dysautonomia, and intranuclear inclusions in a fragile X carrier: a clinical-pathological study. *Mov Disord* 2006;21:420–425, <http://dx.doi.org/10.1002/mds.20753>.
77. Pugliese P, Annesi G, Cutuli N, et al. The fragile X premutation presenting as postprandial hypotension. *Neurology* 2004;63:2188–2189.
78. Chonchaiya W, Agustini U, Pereira G, Tassone F, Hessel D, Hagerman R. Broad clinical involvement in a family affected by the fragile X premutation. *Develop Behav Peds* 2009;30:544–551, <http://dx.doi.org/10.1097/DBP.0b013e3181c35f25>.
79. Bailey DB, Jr., Raspa M, Olmsted M, Holiday DB. Co-occurring conditions associated with FMR1 gene variations: findings from a national parent survey. *Am J Med Genet A* 2008;146A:2060–2069, <http://dx.doi.org/10.1002/ajmg.a.32439>.
80. Moore CJ, Daly EM, Schmitz N, et al. A neuropsychological investigation of male premutation carriers of fragile X syndrome. *Neuropsychologia* 2004;42:1934, <http://dx.doi.org/10.1016/j.neuropsychologia.2004.05.002>.
81. Hunter JE, Allen EG, Abramowitz A, et al. Investigation of phenotypes associated with mood and anxiety among male and female fragile X premutation carriers. *Behav Genet* 2008;38:493–502, <http://dx.doi.org/10.1007/s10519-008-9214-3>.
82. Loesch DZ, Churchyard A, Brotchie P, Marot M, Tassone F. Evidence for, and a spectrum of, neurological involvement in carriers of the fragile X premutation: FXTAS and beyond. *Clin Genet* 2005;67:412, <http://dx.doi.org/10.1111/j.1399-0004.2005.00425.x>.
83. Hessel D, Rivera S, Koldewyn K, et al. Amygdala dysfunction in men with the fragile X premutation. *Brain* 2007;130(Pt 2):404–416, <http://dx.doi.org/10.1093/brain/awl338>.
84. Koldewyn K, Hessel D, Adams J, et al. Reduced Hippocampal Activation During Recall is Associated with Elevated FMR1 mRNA and Psychiatric Symptoms in Men with the Fragile X Premutation. *Brain Imaging Behav* 2008;2:105–116, <http://dx.doi.org/10.1007/s11682-008-9020-9>.
85. Fernandez-Carvajal I, Lopez Posadas B, Pan R, Raske C, Hagerman PJ, Tassone F. Expansion of an FMR1 grey-zone allele to a full mutation in two generations. *J Mol Diagn* 2009;11:306–310, <http://dx.doi.org/10.2353/jmoldx.2009.080174>.
86. Terracciano A, Pomponi MG, Marino GM, et al. Expansion to full mutation of a FMR1 intermediate allele over two generations. *Eur J Hum Genet* 2004;12:333–336, <http://dx.doi.org/10.1038/sj.ejhg.5201154>.
87. Zuniga A, Juan J, Mila M, Guerrero A. Expansion of an intermediate allele of the FMR1 gene in only two generations. *Clin Genet* 2005;68:471–473, <http://dx.doi.org/10.1111/j.1399-0004.2005.00514.x>.
88. Sherman S, Pletcher BA, Driscoll DA. Fragile X syndrome: diagnostic and carrier testing. *Genet Med* 2005;7:584–587, <http://dx.doi.org/10.1097/01.GIM.0000182468.22666.dd>.

89. Kronquist KE, Sherman SL, Spector EB. Clinical significance of trinucleotide repeats in Fragile X testing: a clarification of American College of Medical Genetics guidelines. *Genet Med* 2008;10:845–847, <http://dx.doi.org/10.1097/GIM.0b013e31818c2606>.
90. Maddalena A, Richards CS, McGinniss MJ, et al. Technical standards and guidelines for fragile X: the first of a series of disease-specific supplements to the Standards and Guidelines for Clinical Genetics Laboratories of the American College of Medical Genetics. Quality Assurance Subcommittee of the Laboratory Practice Committee. *Genet Med* 2001;3:200–205, <http://dx.doi.org/10.1097/00125817-200105000-00010>.
91. Dawson AJ, Chodirker BN, Chudley AE. Frequency of FMR1 premutations in a consecutive newborn population by PCR screening of Guthrie blood spots. *Biochem Mol Med* 1995;56:63–69, <http://dx.doi.org/10.1006/bmme.1995.1057>.
92. Loesch DZ, Bui QM, Huggins RM, Mitchell RJ, Hagerman RJ, Tassone F. Transcript levels of the intermediate size or grey zone fragile X mental retardation 1 alleles are raised and correlate with the number of CGG repeats. *J Med Genet* 2007;44:200–204, <http://dx.doi.org/10.1136/jmg.2006.043950>.
93. Bodega B, Bione S, Dalpra L, et al. Influence of intermediate and uninterrupted FMR1 CGG expansions in premature ovarian failure manifestation. *Hum Reprod* 2006;21:952–957, <http://dx.doi.org/10.1093/humrep/dei432>.
94. Murray A, Youings S, Dennis N, et al. Population screening at the FRAXA and FRAXE loci: molecular analyses of boys with learning difficulties and their mothers. *Hum Mol Genet* 1996;5:727, <http://dx.doi.org/10.1093/hmg/5.6.727>.
95. Todd PK, Oh SY, Krans A, et al. Histone deacetylases suppress CGG repeat-induced neurodegeneration via transcriptional silencing in models of fragile X tremor ataxia syndrome. *PLoS Genet* 2010;6:e1001240, <http://dx.doi.org/10.1371/journal.pgen.1001240>.
96. Jacquemont S, Farzin F, Hall D, et al. Aging in individuals with the FMR1 mutation. *Am J Ment Retard* 2004;109:154–164, [http://dx.doi.org/10.1352/0895-8017\(2004\)109<154:AIWTF>2.0.CO;2](http://dx.doi.org/10.1352/0895-8017(2004)109<154:AIWTF>2.0.CO;2).
97. Zesiewicz TA, Sullivan KL, Freeman A, Juncos JL. Treatment of imbalance with varenicline Chantix(R): report of a patient with fragile X tremor/ataxia syndrome. *Acta Neurol Scand* 2009;119:135–138, <http://dx.doi.org/10.1111/j.1600-0404.2008.01070.x>.
98. Ristori G, Romano S, Visconti A, et al. Riluzole in cerebellar ataxia: a randomized, double-blind, placebo-controlled pilot trial. *Neurology* 2010;74:839–845, <http://dx.doi.org/10.1212/WNL.0b013e3181d31e23>.
99. Leehey MA. Fragile X-associated tremor/ataxia syndrome: clinical phenotype, diagnosis, and treatment. *J Investig Med* 2009;57:830–836.
100. Hall D, Berry-Kravis E, Hagerman R, Hagerman P, Jacquemont S, Leehey M. Symptomatic treatment of the fragile X-associated tremor/ataxia syndrome. *Mov Disord* 2006;21:1741–1744, <http://dx.doi.org/10.1002/mds.21001>.
101. Saponara R, Greco S, Proto G, Trubia T, Domina E. Levetiracetam improves intention tremor in fragile X-associated tremor/ataxia syndrome. *Clin Neuropharmacol* 2009;32:53–54, <http://dx.doi.org/10.1097/WNF.0b013e31816a48e2>.
102. Bourgeois JA, Farzin F, Brunberg JA, et al. Dementia with mood symptoms in a fragile X premutation carrier with the fragile X-associated tremor/ataxia syndrome: clinical intervention with donepezil and venlafaxine. *J Neuropsychiatry Clin Neurosci* 2006;18:171–177, <http://dx.doi.org/10.1176/appi.neuropsych.18.2.171>.
103. Hagerman RJ, Hall DA, Coffey S, et al. Treatment of fragile X-associated tremor ataxia syndrome (FXTAS) and related neurological problems. *Clin Interv Aging* 2008;3:251–262.
104. Ortigas MC, Bourgeois JA, Schneider A, et al. Improving fragile X-associated tremor/ataxia syndrome symptoms with memantine and venlafaxine. *J Clin Psychopharmacol* 2010;30:642–644, <http://dx.doi.org/10.1097/JCP.0b013e3181fd10a>.
105. Revuelta GJ, Wilmot GR. Therapeutic interventions in the primary hereditary ataxias. *Curr Treat Options Neurol* 2010;12:257–273, <http://dx.doi.org/10.1007/s11940-010-0075-8>.
106. Feys P, Romberg A, Ruutiainen J, et al. Assistive technology to improve PC interaction for people with intention tremor. *J Rehabil Res Dev* 2001;38:235–243.
107. Surdilovic T, Zhang YQ. Convenient intelligent cursor control web systems for Internet users with severe motor-impairments. *Int J Med Inform* 2006;75:86–100, <http://dx.doi.org/10.1016/j.ijmedinf.2005.07.042>.
108. Aisen ML, Arnold A, Baiges I, Maxwell S, Rosen M. The effect of mechanical damping loads on disabling action tremor. *Neurology* 1993;43:1346–1350.
109. Sanes JN, LeWitt PA, Mauritz KH. Visual and mechanical control of postural and kinetic tremor in cerebellar system disorders. *J Neurol Neurosurg Psychiatry* 1988;51:934–943, <http://dx.doi.org/10.1136/jnnp.51.7.934>.
110. Gibson-Horn C. Balance-based torso-weighting in a patient with ataxia and multiple sclerosis: a case report. *J Neurol Phys Ther* 2008;32:139–146.
111. Morrice BL, Becker WJ, Hoffer JA, Lee RG. Manual tracking performance in patients with cerebellar incoordination: effects of mechanical loading. *Can J Neurol Sci* 1990;17:275–285.
112. Perlmutter E, Gregory PC. Rehabilitation treatment options for a patient with paraneoplastic cerebellar degeneration. *Am J Phys Med Rehabil* 2003;32:158–162, <http://dx.doi.org/10.1097/00002060-200302000-00014>.
113. Gracies JM, Fitzpatrick R, Wilson L, Burke D, Gandevia SC. Lycra garments designed for patients with upper limb spasticity: mechanical effects in normal subjects. *Arch Phys Med Rehabil* 1997;78:1066–1071, [http://dx.doi.org/10.1016/S0003-9993\(97\)90129-5](http://dx.doi.org/10.1016/S0003-9993(97)90129-5).
114. Marsden J, Harris C. Cerebellar ataxia: pathophysiology and rehabilitation. *Clin Rehabil* 2011;25:195–216, <http://dx.doi.org/10.1177/0269215510382495>.
115. Okajima Y, Chino N, Noda Y, Takahashi H. Accelerometric evaluation of ataxic gait: therapeutic uses of weighting and elastic bandage. *Int Disabil Stud* 1990;12:165–168, <http://dx.doi.org/10.3109/03790799009166610>.
116. Silva RC, Saute JA, Silva AC, Coutinho AC, Saraiva-Pereira ML, Jardim LB. Occupational therapy in spinocerebellar ataxia type 3: an open-label trial. *Braz J Med Biol Res* 2010;43:537–542, <http://dx.doi.org/10.1590/S0100-879X2010005000009>.
117. Ilg W, Synofzik M, Brotz D, Burkard S, Giese MA, Schols L. Intensive coordinative training improves motor performance in degenerative cerebellar disease. *Neurology* 2009;73:1823–1830, <http://dx.doi.org/10.1212/WNL.0b013e3181c33adf>.

118. Ilg W, Brotz D, Burkard S, Giese MA, Schols L, Synofzik M. Long-term effects of coordinative training in degenerative cerebellar disease. *Mov Disord* 2010;25:2239–2246, <http://dx.doi.org/10.1002/mds.23222>.
119. Cernak K, Stevens V, Price R, Shumway-Cook A. Locomotor training using body-weight support on a treadmill in conjunction with ongoing physical therapy in a child with severe cerebellar ataxia. *Phys Ther* 2008;88:88–97, <http://dx.doi.org/10.2522/ptj.20070134>.
120. Gill-Body KM, Popat RA, Parker SW, Krebs DE. Rehabilitation of balance in two patients with cerebellar dysfunction. *Phys Ther* 1997;77:534–552.
121. Landers M, Adams M, Acosta K, Fox A. Challenge-oriented gait and balance training in sporadic olivopontocerebellar atrophy: a case study. *J Neurol Phys Ther* 2009;33:160–168.
122. Luft AR, Macko RF, Forrester LW, et al. Treadmill exercise activates subcortical neural networks and improves walking after stroke: a randomized controlled trial. *Stroke* 2008;39:3341–3350, <http://dx.doi.org/10.1161/STROKEAHA.108.527531>.
123. Moseley AM, Stark A, Cameron ID, Pollock A. Treadmill training and body weight support for walking after stroke. *Cochrane Database Syst Rev* 2005:CD002840.
124. Pilutti LA, Lelli DA, Paulseth JE, et al. Effects of 12 weeks of supported treadmill training on functional ability and quality of life in progressive multiple sclerosis: a pilot study. *Arch Phys Med Rehabil* 2010;92:31–36, <http://dx.doi.org/10.1016/j.apmr.2010.08.027>.
125. Wier LM, Hatcher MS, Triche EW, Lo AC. Effect of robot-assisted versus conventional body-weight-supported treadmill training on quality of life for people with multiple sclerosis. *J Rehabil Res Dev* 2011;48:483–492, <http://dx.doi.org/10.1682/JRRD.2010.03.0035>.
126. Broglio SP, Sosnoff JJ, Rosengren KS, McShane K. A comparison of balance performance: computerized dynamic posturography and a random motion platform. *Arch Phys Med Rehabil* 2009;90:145–150, <http://dx.doi.org/10.1016/j.apmr.2008.06.025>.
127. Chong RK, Horak FB, Frank J, Kaye J. Sensory organization for balance: specific deficits in Alzheimer's but not in Parkinson's disease. *J Gerontol A Biol Sci Med Sci* 1999;54:M122–128, <http://dx.doi.org/10.1093/gerona/54.3.M122>.
128. Chong RK, Jones CL, Horak FB. Postural set for balance control is normal in Alzheimer's but not in Parkinson's disease. *J Gerontol A Biol Sci Med Sci* 1999;54:M129–135, <http://dx.doi.org/10.1093/gerona/54.3.M129>.
129. Cohen HS, Kimball KT. Decreased ataxia and improved balance after vestibular rehabilitation. *Otolaryngol Head Neck Surg* 2004;130:418–425, <http://dx.doi.org/10.1016/j.otohns.2003.12.020>.
130. Cohen HS, Kimball KT. Usefulness of some current balance tests for identifying individuals with disequilibrium due to vestibular impairments. *J Vestib Res* 2008;18:295–303.
131. Meli A, Zimatore G, Badaracco C, De Angelis E, Tufarelli D. Vestibular rehabilitation and 6-month follow-up using objective and subjective measures. *Acta Otolaryngol* 2006;126:259–266.
132. Chonchaiya W, Tassone F, Ashwood P, et al. Autoimmune disease in mothers with the FMR1 premutation is associated with seizures in their children with fragile X syndrome. *Hum Genet* 2010;128:539–548, <http://dx.doi.org/10.1007/s00439-010-0882-8>.