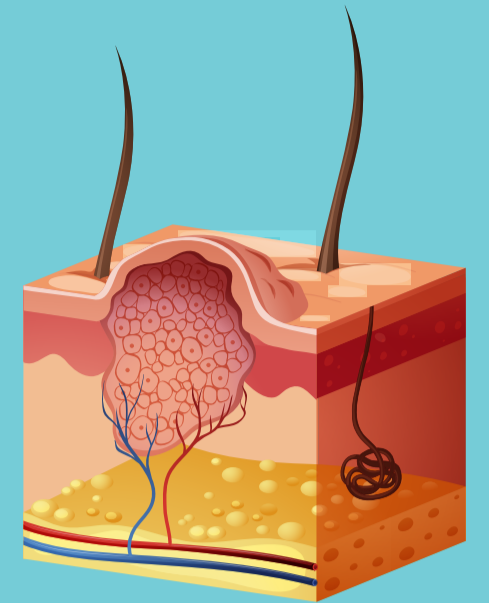


# Genital Skin Lesions (Non-Ulcerative)

Discrete lumps or bumps in the genital region may be due to normal anatomical findings, or may be due to a small number of sexually transmissible infections. Unusual lesions, including pigmented lesions, should be referred for a specialist opinion before any treatment occurs.



Patient complains of Genital Skin Lump(s) / Bump(s)

## Examination

Note the appearance and location of lesions – together with the history, this is usually sufficient to make a diagnosis.

### Normal Anatomical Variants

- Males  
Pearly penile papules (coronal papillae), Fordyce glands.
- Females  
Vestibular papillomatosis, Fordyce glands

### Management

- Reassure patient that the lesions are normal.
- Offer opportunistic sexual health check.
- If unsure of findings, seek second opinion.

### Genital Warts

Exophytic skin lesions that vary in size/shape and number.

#### Males

- Typically at leading edge of prepuce, on frenulum, or more sporadically in coronal sulcus, on penile shaft. Less frequently on scrotum or in pubic area or perianal.

#### Females

- Usually vulval (often posteriorly), perineal, or perianal. Note: Lesions resembling warts and arising in warm moist mucosal sites (e.g. inner labial, anal) – exclude syphilis (Condylomata lata).

### Management

- Treatment options – see Genital Warts guideline
- Pigmented or atypical lesions – refer to sexual health specialist.
- Offer full sexual health

### Molluscum Contagiosum

- Small dome-shaped lesions with waxy colour, and with central umbilication. If large they can assume a more nodular or fleshy appearance.

- Usually pubic, penile, or vulval

### Management

- Will resolve without treatment, but may take many months.
- Treat with cryotherapy.
- Offer full sexual health check.

### Scabies nodules

- History of recent/current scabies.
- 'Nodular' lesions more common in males.
- Usual location: glans penis, shaft or scrotum.
- Typically: 2-10 mm reddish papulonodular lesions; very itchy.

### Management

- Check syphilis serology.
- See Ectoparasites guideline.
- Refer to sexual health specialist if unsure of diagnosis or lesions non-responsive to topical treatment.
- Offer full sexual health check.