

# Prostate cancer: diagnostic utility of multiparametric prostate MRI with 3D spectroscopy in the CMDLT January-June 2023

## Abstract

The prostate gland secretes citrate, the levels of which vary in benign prostatic hyperplasia and tumors. Multiparametric MRI of the prostate, although sensitive, has limitations in its specificity. Spectroscopy can quantify these cellular metabolites. At the La Trinidad Teaching Medical Center, 46 studies were carried out with 3D spectroscopy in patients referred from the urology service from January to June 2023. The objective was to verify the diagnostic usefulness of 3D spectroscopy with multiparametric Magnetic Resonance of the prostate. The findings in the 3D prostate spectroscopy metabolite map were described, the results of the mpMRI PIRADS score and the metabolite map were analyzed, and the anatomical pathological and 3D spectroscopy results were compared. A 1.5T Philips Anchieva resonator was used with 3D prostate spectroscopy sequences in 36 patients. The metabolites in 3D spectroscopy showed correlation with the suspicious criteria according to SCORE PI-RADS, especially in the suspicious nodular areas. The sensitivity and positive predictive value were 88%, while the specificity and negative predictive value were 96%. However, more studies are needed to obtain more conclusive results.

**Keywords:** prostate cancer, BPH, prostatitis, mpMRI, 3D spectroscopy

Volume 12 Issue 2 - 2024

Manuel Antonio Fernandez De Freitas,<sup>1</sup>  
Verónica Hernández Burgos<sup>2</sup>

<sup>1</sup>Centro Médico Docente La Trinidad, Torre Gonzalez Rincones, Sotano 2, Venezuela

<sup>2</sup>Centro Médico Docente la Trinidad, Radiology Service, Venezuela

**Correspondence:** Manuel Antonio Fernandez De Freitas, Centro Médico Docente La Trinidad, Torre Gonzalez Rincones, Sotano 2, Venezuela, Tel 0412-6304806, Email manuelexfernande@gmail.com

**Received:** March 20, 2024 | **Published:** May 21, 2024

**Abbreviations:** Pca, prostate cancer; CMDLT, la trinidad teaching medical center; PI-RADS, prostate imaging data processing and reporting system; PSA, prostate serum antigen; MRI, multiparametric MRI of the prostate; NMR, nuclear magnetic resonance; ADC, apparent diffusion coefficient

## Introduction

Prostate cancer (PCa) continues to represent a threat to men's health, being the leading cause of cancer death in men in the world in 2022 with approximately 268,490 new cases and 34,500 deaths in the United States.<sup>1,2</sup> In this sense, in 2017, according to the Pan American Health Organization, prostate cancer represented the most common cancer in men, with 413,000 new cases and 85,000 deaths per year.<sup>3</sup> In this way, Venezuela was no exception since, according to the Anticancer Society of Venezuela, prostate cancer ranked first in terms of cancer mortality with 3,792 deaths, most frequently in terms of mortality after the age of 75; With 8,277 new cases occupying first place in incidence, the ages of most frequent diagnosis were between 65-74 years.<sup>4</sup> Likewise, the human prostate, as well as in other animals, given that it is a fibromuscular and glandular organ; It has the function of accumulating and secreting high levels of citrate. In processes such as benign prostatic hyperplasia, higher levels of zinc and citrate accumulate; On the other hand, in tumor processes where there is an inability of the malignant cells to accumulate zinc at the intramitochondrial level, the activity of aconitase is inhibited, which in turn prevents the oxidation of citrate and thus the coupled production of ATP, which is essential for tumor progression.<sup>5,6</sup>

In this context, carcinogenesis of the prostate gland is a complex process with various associated factors such as ethnic origin, geographic origin, eating habits, lifestyle, genetics, among other factors; Understanding the metabolism of prostate cancer is relevant for the development of better diagnostic and therapeutic approaches. In this sense, magnetic resonance spectroscopy has proven useful in terms of detection and quantification of metabolites, which is why

it has taken center stage in various studies as a complement in the evaluation of prostate cancer that is characterized by elevated and decreased choline levels. of citrate values.<sup>7-9</sup> Also, prostatitis has been considered a risk factor for the development of prostate cancer and the causal possibility of hyperproliferation in post-inflammatory atrophic acini has been documented, in cases of consequent lesions and proliferative inflammatory atrophy that is associated with preneoplastic and malignant lesions.<sup>10</sup>

Thus, in view of the relevant threat of prostate cancer for the male population, multiple methods have been described for timely diagnosis; the rectal examination performed by the urologist, the prostate antigen (PSA) values, the transrectal ultrasound (USTR), the multiparametric MRI of the prostate and the definitive diagnosis by the anatomopathological result of the sample obtained by taking a biopsy.<sup>11,12</sup> In this sense, Multiparametric Prostate Resonance (mpMRI) has presented many benefits, being less invasive for the patient, with less discomfort considering that new technologies do not require endorectal bovine, it provides better anatomical and functional information of the tissues, greater categorization thanks to the PI-RADS criteria and a decrease in the number of unnecessary biopsies. Therefore, with technological advances in medicine and magnetic resonance imaging diagnostic techniques, new methods for taking biopsies have emerged, such as image fusion biopsy where the images obtained through transrectal ultrasound are associated with the images visualized in the mpMRI and a transperineal approach is used, precisely locating the lesions, significantly reducing the risk of infections.

Furthermore, taking into account that the majority (more than 70%) of prostate tumors are located in the peripheral zone and the rest in the central gland. In cases of prostate growth, there is a challenge in taking biopsies, given that the peripheral tissue is compressed, attributing greater difficulty in locating the cancer with systematic blind biopsies.<sup>13-15</sup> In this sense, the evidence described in international and national literature suggests that multiparametric

MRI of the prostate has high sensitivity, but still limitations in its specificity, which is why the present work raises the question of what its diagnostic usefulness will be. of the 3D spectroscopy of the prostate by Magnetic Resonance in the Radiology Service of the La Trinidad Teaching Medical Center, in patients who attend in the first half of the year 2023. In order to determine if it could correspond with a useful complementary tool in the reports with the system characterization proposed by the PI-RADS 2.1 score.

## Goals

### General objective

Verify the diagnostic utility of 3D spectroscopy with multiparametric Magnetic Resonance of the prostate at the La Trinidad Medical Teaching Center during the first half of 2023.

### Specific objectives

- I. Describe the findings in the metabolite map of 3D prostate spectroscopy, of patients who attend the La Trinidad Teaching Medical Center in the first half of 2023 and obtain suspicion criteria by SCORE PI-RADS 2.1.
- II. Analyze the map of metabolites through 3D spectroscopy in those patients who had findings suggestive of prostatitis and whose history refers to clinical improvement with medical treatment or anatomopathological results that refer to inflammatory changes in patients who attend the teaching medical center. the trinity the first half of 2023.
- III. Analyze the map of metabolites through 3D spectroscopy in those patients who had findings of prostatic growth and who through the clinical history or anatomical-pathological results refer to findings of benign prostatic hyperplasia or hypertrophy of the fibromuscular stroma in the patients who attend. to the La Trinidad Teaching Medical Center in the first half of 2023.

## Methods

### Type of study

The design of the present study was observational analytical cross-sectional Test vs. Test, the first phase with the studies of the patients who attended from January 2023 to June 2023, after applying inclusion and exclusion criteria, the imaging reports were reviewed guided according to the PI-RADS 2.1 categorization, the information obtained by urologists and pathological anatomy. The anatomical-pathological and clinical results of those patients were compared, contrasting the values obtained by the PI-RADS score with what was stated in the metabolite maps obtained by magnetic resonance imaging and in cases with imaging suspicion criteria, they were also contrasted with the anatomical result. pathological, obtaining through the evaluation of true positives and negatives the sensitivity and specificity using the data collection instrument.

### Population and sample

The population was made up of all those studies of multiparametric MRI of the prostate with 3D Spectroscopy carried out in the Dr. Ramón Franco Radiology Service of the La Trinidad Teaching Medical Center during the year 2023 (N = 46) spaces donated by IDACA CA for the present investigation. In this sense, the sample was made up of those patients who met the inclusion and exclusion criteria (n = 36), since given that the formal indication for mpMRI is suspicion of prostate cancer, the population and sample would represent the same entity in the present study, even so, considering the heterogeneity of

the possible PI-RADS SCORE. The inclusion criteria were: patients with mpMRI and 3D spectroscopy system studies with PI-RADS 2 reports with findings suggestive of an inflammatory process, with clinical proof of improvement with medical treatment, and patients with mpMRI and 3D spectroscopy system studies. with reports according to the PI-RADS score that they underwent biopsy with histopathological results, prostatectomy or transurethral resection of the prostate. Regarding the exclusion criteria, they corresponded to: patients who only had mpMRI without 3D spectroscopy, and patients who received hormonal treatment prior to performing mpMRI and 3D spectroscopy. In the study procedure, the images recorded with their respective reports in the PACS and RIS systems respectively were reviewed, in the latter allowing access to the histopathological results in those patients that are available. The values given in the reports according to the PI-RADS score were analyzed, comparing with the confirmatory method of the biopsy and its Anatomical-pathological result, or the clinical development described by the urologists through the medical records, obtaining true positive results. and true negatives, inserting the data through a spreadsheet, in this sense Office Excel was used, and through statistical treatment with analysis of predictive values and areas under the curve, a scheme of sensitivity and specificity of the mpMRI was developed and 3D spectroscopy at the La Trinidad Teaching Medical Center. Data recording was through the data collection format, already provided previously.

## Results

After reviewing the studies carried out and corroborating through the medical records system that the information regarding PSA values, conduct with medical or surgical treatment, data management and analysis of results were carried out using spreadsheets to prepare frequency tables, calculation of sensitivity, specificity, predictive values; mean, median and mode of ages of patients who attended the service for the study for suspected prostate cancer and standard deviation. The mean age of the sample corresponded to 63.97 years, the median 62.5 and the mode 62 with a standard deviation of 7.4.

In Table 1, it can be seen that 21 (58.33%) of the patients who attended the service after applying inclusion and exclusion criteria presented high prostate antigen values while 15 (41.67%) patients showed values within of normal limits. In Table 2, it can be seen that 48% of the patients who obtained results without suspicion criteria (PI-RADS 1 and 2) had elevated PSA values, while 52% had normal values. On the other hand, those patients who had results according to the SCORE PI-RADS with suspicion criteria (3, 4 and 5) showed 81.82% elevated PSA values while only 18.18% maintained values within limits. normal Table 2.

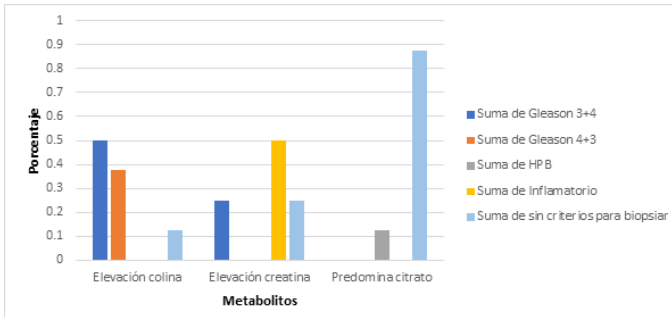
**Table 1** Frequency of PSA data

PSA	Frequency	Percentage (%)
High	twenty-one	58.33
Normal	fifteen	41.67
Total	36	100

**Table 2** PSA / PIRADS relationship

PSA	PIRADS		Total
	Without suspicion criteria	With suspicion criteria	
High	12	9	twenty-one
Percentage (%)	48	81.82	58.33
Normal	13	2	fifteen
Percentage (%)	52	18.18	41.67

The behavior of the different metabolites in the 3D spectroscopy of the prostate contrasted with the suspicion criteria taking into consideration SCORE PI-RADS demonstrated correlation, especially in the nodular areas with suspicion criteria since they presented 87.5% elevation of choline peaks. and in the same percentage there was anatomical-pathological correlation of the findings with PI-RADS and spectroscopy Graph 1.



Graph 1 Metabolite map / anatomical-pathological result relationship.

## Discussion

In contrast to the studies carried out in 2019 by Mazaheri et al.,<sup>17</sup> and 2021 by Michael Deal et al.,<sup>16</sup> the performance of the predictive models was evaluated based on sensitivity, specificity and area. Under the curve of the operating characteristic curves, we obtained similar results that suggest that the predictive model of tumor aggressiveness combined mpMRI together with 3D spectroscopy was better than the mpMRI model alone. The sensitivity and positive predictive value of the findings in 3D spectroscopy with choline elevation corresponded to 88% while the specificity and negative predictive value corresponded to values of 96%, obtaining a result quite similar to that proposed in the international literature. In this sense, demonstrating that the information obtained together by mpMRI and NMR spectroscopy seems to contribute to improving the detection of hidden aggressive diseases, helping in the discrimination of intermediate risks. In contrast to the study carried out in 2018.<sup>18</sup> They had a larger sample size, retrospectively analyzed the clinical and imaging data of 9 patients with prostate cancer, 118 patients with benign prostatic hyperplasia (including those with glandular, stromal and mixed hyperplasia). In their study they did not differentiate between prostate cancer and benign prostatic hyperplasia in the central zone; Certainly, in the present study there were 25% of the patients who presented elevated creatine, who, because they had criteria for histopathological study by SCORE PI-RADS, were taken to a biopsy and obtained a Gleason 3+4 pathological result. In their conclusions, the study could not determine a potential improvement in the use of 3D magnetic resonance spectroscopy in the direction of prostate cancer in the central zone; Considering the sample size of the present study in contrast to the study by Xue-Qin and collaborators, the development of research work along the same lines with a larger sample should be promoted in order to obtain more conclusive results regarding the benefit of spectroscopy in the area. transitional, however our results, consistent with the aforementioned studies, are encouraging for the use of this tool as a complement to multiparametric resonance in the study of prostate pathology.<sup>19-25</sup>

## Conclusion

Despite the size of the sample, it has been presented in this first observational work of 3D spectroscopy of the prostate by multiparametric Resonance at a national level that this tool has

promising results as a complement to the study of prostate pathology, which coincides with the results reported in similar studies in the international literature. The frequency of prostate cancer in the present study was directly proportional to the age of the patients. Elevated PSA values had a greater correlation in patients with imaging findings with high PIRADS scores, while in patients with scores that did not represent suspicion criteria they did not have a statistically significant value in the present study.

In the cases of BPH, the curves showed a predominance of citrate, tumor processes elevation of choline above creatine, in some cases they even showed higher values than the citrate curves. In inflammatory processes, the elevation of creatine was evident, even in cases where choline was subdued. The sensitivity and positive predictive value of the findings in 3D spectroscopy with choline elevation corresponded to 88% while the specificity and negative predictive value corresponded to values of 96%. However, considering the sample size, it is necessary to continue with larger population studies, in the same line of research for more conclusive results, however, those obtained in the present study are promising.

## Authors' declaration

Dr. Manuel Fernandez – Resident of the RAPP in Imaging of the CMDLT – Main Author - I declare that there is no real, potential or potentially perceived conflict of interest (economic, professional or personal) that could result in bias in the publication of this Work.

Dr. Verónica Alejandra Hernandez Burgos – Teaching assistant of the CMDLT radiology service – Tutor – I declare that there is no real, potential or perceived conflict of interest (economic, professional or personal) that could result in bias in the publication of this Job.

## Thanks

I thank God for putting his pieces where he needs them to be, the opportunities in humanity's path to take them and make the most of them for good.

I thank my family who have been, are and will be for me unconditionally.

I thank the institution for its support in the development of this work through the different services, including the research department that always receives those who come with great patience and attention.

I thank Dr. Miguel Ángel Rocha Canales for introducing me to the world of prostate imaging.

I thank Dr. Verónica Hernández for trusting in this project.

I thank Dr. Leidy Navas for having contributed energetically and unconditionally to this research.

## Acknowledgments

None.

## Conflicts of interest

The authors declares that there are no conflicts of interest.

## References

1. Fernandez de Freitas M, Matheus Fernández CI. Prostate cancer: the experience of the radiology service of the la trinidad teaching medical center in the diagnosis through multiparametric magnetic resonance, prostatic ultrasound and their anatomical-pathological correlation. *CMDLT Scientific Magazine*. 2022;16(S).

2. *Prostate Cancer Prevention (PDQ®)–Health Professional Version*. National Cancer Institute. 2022.
3. Cayon A. PAHO/WHO | Regional experts discuss approaches to screening and early detection of prostate cancer in the Americas [Internet]. Pan American Health Organization / World Health Organization. 2022.
4. Brito O. Anticancer Society of Venezuela [Internet] [cancervenezuela.org](http://cancervenezuela.org) 2021. *National diptych on prostate cancer*. 2022.
5. Robles Rodríguez Alfredo, Garibay Huarte Tania Rocío, Acosta Arreguín Eduardo, et al. The prostate: generalities and most frequent pathologies. *Rev Fac Med (Méx)*. 2019;62(4):41–54.
6. Comet Batlle Josep, Vilanova Busquets Joan Carles, Barceló Obregón Joaquim, et al. Diagnosis of prostate cancer using endorectal magnetic resonance spectroscopy. *Arch Esp Urol*. 2006;59(10):953–963.
7. Correa JJ, Pow-Sang J. *Mechanisms of Carcinogenesis in Prostate Cancer*. Mechanisms of Oncogenesis: An update on Tumorigenesis. Dordrecht: Springer Netherlands; 2010. p. 295–304.
8. Carter BS, Bova GS, Beaty TH, et al. Hereditary prostate cancer: Epidemiologic and clinical features. *Journal of Urology*. 1993;150(3):797–802.
9. Sfanos KS, De Marzo AM. Prostate cancer and inflammation: the evidence. *Histopathology*. 2012;60(1):199–215.
10. Labra A, Zúñiga A. Pitfalls in multiparametric prostate MRI. *Rev Chil Radio*. 2019;25(4):128–140.
11. García H, Zapata J, Sánchez A. A global and updated look at prostate cancer. *Scielo Chile*. 2017.
12. Vilanova JC, Comet J, Garcia-Figueiras R, et al. Usefulness of magnetic resonance imaging in prostate cancer. *Radiology*. 2010;52(6):513–524.
13. Metzger GJ, Kalavagunta C, Spilseth B, et al. Detection of prostate cancer: Quantitative multiparametric mr imaging models developed using registered correlative histopathology. *Radiology*. 2016;279(3):805–816.
14. Turkbey B, Rosenkrantz AB, Haider MA, et al. Prostate imaging reporting and data system version 2.1: 2019 update of prostate imaging reporting and data system version 2. *Eur Urol*. 2019;76(3):340–351.
15. Deal M, Bardet F, Walker PM, et al. Three-dimensional nuclear magnetic resonance spectroscopy: a complementary tool to multiparametric magnetic resonance imaging in the identification of aggressive prostate cancer at 3.0T. *Quant Imaging Med Surg*. 2021;11(8):3749–3766.
16. Mazaheri Y, Shukla-Dave A, Goldman DA, et al. Characterization of prostate cancer with MR spectroscopic imaging and diffusion-weighted imaging at 3 Tesla. *Magn Reson Imaging*. 2019;55:93–102.
17. Zhang XQ, Yu XR, Du ZL, et al. Three-dimensional proton magnetic resonance spectroscopy and diffusion-weighted imaging in the differentiation of incidental prostate carcinoma from benign prostate hyperplasia. *Oncol Lett*. 2018;15(5):6541–6546.
18. Niranjani J, Omer A, Harriss E, et al. Negative predictive value of multiparametric magnetic resonance imaging in the detection of clinically significant prostate cancer in the prostate imaging reporting and data system era: a systematic review and meta-analysis. *Eur Urol*. 2020;78(3):402–414.
19. Gray ADR, Connor MJ, Tam J, et al. Can transrectal prostate ultrasound compete with multiparametric MRI in the detection of clinically significant prostate cancer? *Transl Androl Urol*. 2020;9(3):1492–1500.
20. Forment Navarro M, Montesinos García P, Blanco Pérez E, et al. Utility of prostate MRI and the PI-RADS v2.1 system in patients without a prior diagnosis of neoplasia. *Seram*. 2021;1(1):35.
21. Labra W Andrés, Olivares C Juan Pablo, Tapia C María Fernanda. Usefulness of the PI-RADS 2 score in clinical practice. is THE histological study justified? *Rev chil radiol*. 2017;23(4):151–155.
22. Labra WA, Fuente-Alba CS, Schiappacasse FG, et al. Interobserver agreement for the validation of PI-RADS v2. *Rev Argent Radiol*. 2019;83(2):49–55.
23. Van der Leest M, Cornel E, Israël B, et al. Head-to-head comparison of transrectal ultrasound-guided prostate biopsy versus multiparametric prostate resonance imaging with subsequent magnetic resonance-guided biopsy in biopsy-naïve men with elevated prostate-specific antigen: a large prospective multicenter clinical study. *European Urology*. 2019;75(4):570–578.
24. Carrillo J. *Usefulness of magnetic resonance imaging in the diagnosis of prostate cancer*. Unpublished thesis. Central University of Venezuela – Domingo Luciani Hospital. 2020.
25. Klotz L, Lughezzani G, Maffei D, et al. Comparison of micro-ultrasound and multiparametric magnetic resonance imaging for prostate cancer: A multicenter, prospective analysis. *Can Urol Assoc J*. 2021;15(1):E11–E16.