

Variant focal segmental collapsing glomerulosclerosis associated with COVID-19 vaccine and high-risk APOL1 genotype clinical case report and bibliographic review

Abstract

Introduction: The COVID-19 pandemic, produced by a mutant strain of coronavirus SARS-CoV-2, which caused worldwide chaos never seen before, started in China in December 2019. In Brazil the first case was confirmed on February 26, 2020 with a 61-year-old patient and the World Health Organization declared a pandemic on March 11, 2020; the aggressiveness of the disease led to an accelerated search for treatments and vaccines, just in July 2021, there were 184 vaccine candidates against COVID-19; Along with immunization, several adverse effects generated by the various vaccines have been reported, ranging from mild to severe, from minor pain at the puncture site to headache, fever, arthralgias, etc. Severe cases have also been reported, such as anaphylaxis, heart disease, renal alterations, etc. which to date are not fully determined.

Clinical case: It is related to a clinical case report in Brazil of a 16-year-old female patient, with no significant personal history, who received the first dose of the vaccine for COVID-19 (Pfizer-BioNTech) and 3 days later presented with headache, abdominal pain and arterial hypertension; when assessed and with complementary examinations was determined a rapidly progressive glomerulonephritis, she received treatment with corticosteroids for 3 days; with the biopsy resulted in focal and segmental collapsing glomerulosclerosis with moderate tubulointerstitial repercussion (30-40%).

Evolution: The patient developed renal failure and nephritic/nephrotic syndrome.

Conclusion: It is not determined with certainty, but there is the possibility of association of glomerular disease with vaccination for COVID-19, it is necessary to continue with the vaccination campaigns and to reduce the aggressiveness of this disease.

Keywords: COVID-19, pfizer-biontech, moderna, Oxford/ Astra Zeneca vaccines

Volume 12 Issue 1 - 2024

Tânia Claudina Suin Chin,¹ Maria Izabel Neves de Holanda Barbosa,² Mauricio Younes Ibrahim,² Jessica Viviana Velecela Chumbi,² Sebastiam Alejandro Izquierdo Coronel²

¹Nephrologist Chief of the Hospital's Nephrology and Renal Transplant Service Federal Bonsucesso, RJ and scientific director of the Society of Nephrology of the State of Rio De Janeiro, SONERJ, Brazil

²Post-graduate doctor in Nephrology, Pontifical Catholic University of Rio de Janeiro, Brazil

Correspondence: Tânia Claudina Suin Chin, Post-graduate doctor in Nephrology, Pontifical Catholic University of Rio de Janeiro, Brazil, Email tanik@hotmail.es

Received: March 05, 2024 | **Published:** March 26, 2024

Abbreviations: WHO, world health organization; GESFC, collapsing variant focal segmental glomerulosclerosis; FSGS: focal segmental glomerulosclerosis; GC, collapsing glomerulonephritis; FIAT, fibrosis and interstitial atrophy; UA, urinary abnormalities; HRG, high risk genotype; GN, glomerulonephritis

Introduction

Humanity is affected by diseases that emerge unexpectedly, such as the COVID-19 pandemic, caused by a mutant strain of the coronavirus, SARS-CoV-2, which has caused a severe health, economic and social crises around the world. never seen before, began in China in December 2019, in the city of Wuhan. At this location, 27 patients with pneumonia of unknown cause were treated and seven patients were in critical condition. The first case was reported on December 8, 2019 and on January 7, 2020, the Chinese Ministry of Health detected a new coronavirus. On January 24, 2020, 835 cases were recorded in China, on January 13, the first case was detected in Thailand and on January 19 in South Korea, then in different countries around the world.¹ Due to this, the World Health Organization established March 11, 2020 as a pandemic and in Brazil the first case of Covid 19, on February 26, 2020 in a 61-year-old patient.²

The aggressiveness of the disease led to a hasty search for treatments and vaccines. As of July 2021, there are 184 vaccines

for COVID-19 in preclinical progress, 105 in the clinical process and 18 vaccines admitted for emergency by at least one regulatory authority, these include live attenuated or inactivated, protein-based, vector viral and nucleic acid vaccines. By mid-2021, three billion vaccines have been administered worldwide.³ Immunizations should be administered with caution to patients with a history of allergies, therefore, after administration, it is advisable to keep the vaccinated person under observation for 15 minutes.⁴ In terms of effectiveness, after completing the vaccination cycle, the percentages are 95% for the Pfizer/BioNTech vaccine, 94.1% for the Moderna vaccine, 91.6% for the Gamaleya vaccine, 70.4 % for Oxford/AstraZeneca, and Sinovac announced variable efficacy of 50%,65%,78% and 91%.⁵

Just like medications, there are adverse effects generated by the different vaccines, ranging from mild to severe, from mild pain at the puncture site to headache, fever and arthralgia, among others. Serious cases have also been reported, following millions of doses of the Pfizer-BioNTech vaccine administered and millions of doses of the Moderna vaccine administered in the US. Cases of anaphylaxis (levels 1, 2 or 3) were reported in 4.7 patients per million doses of the Pfizer-BioNTech vaccine and 2.5 patients per million doses of the Moderna vaccine, with no mortality.⁴ Also very rare cases with post-vaccination thrombotic risk, were reported to the WHO through the VigiBase system, after studying three vaccines (Pfizer/BioNTech, Moderna

and Oxford/AstraZeneca), over a period of 94 days in 361,734,967 people vaccinated. The total rate of thrombotic events was 0.21 (95% CI 0.19-0.22) per million people vaccinated.⁶ According to the WHO, adverse reactions to medicines, including vaccines, are defined as the set of unwanted effects caused by medications that occur after the administration of a dose of the medication used for prophylaxis, diagnosis or treatment of the disease or to modify a biological function, these include immunologically mediated hypersensitivity reactions, with specificity for antibodies or lymphocytes, generated by exposure to drugs.⁷ Another adverse effect that the COVID-19 vaccine generated is glomerular disease, reported in some studies, such as in a study carried out in Mexico in 2021, where 29 patients were identified with the development of glomerular disease in close temporal association with immunization against SARS-CoV-2. Kidney biopsies indicated IgA nephropathy, minimal change disease, membranous nephropathy, crescentic glomerulonephritis (GN) and collapsing variant focal segmental glomerulosclerosis, the latter with two APOL1 genomic risk alleles (high-risk genotype).⁸ Likewise, some cases of nephrotic syndrome with minimal changes of abrupt onset were reported after the first week of the Pfizer-BioNTech vaccine dose, as well as IgA nephropathy that presented as macroscopic hematuria within 2 days after the second dose. of the Moderna vaccine, as well as other kidney changes that emerged and were reported within 3 weeks after vaccination against COVID-19.⁹ Due to possible associations of adverse reactions to vaccines against COVID-19, the following clinical case is reported.

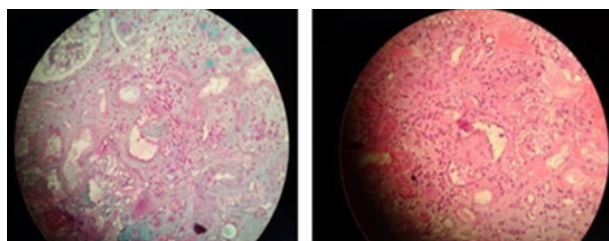
Clinical case presentation

A female patient, 16 years old, black, healthy, with no significant family or personal history, presented with abdominal pain, nausea and vomiting. On 09/23/2021, three days after taking the first dose of the vaccine for COVID-19 (Pfizer-BioNTech), she went to SMS UPA 24 h COMPLEXO GERMAN-AP3.1, where high blood pressure was recorded. Omeprazole and antihypertensives were administered with improvement in the condition and medical discharge. The following day, she returned with significant pain in the epigastrium and hypertensive crisis (BP 220/100), with an X-ray of the chest and abdomen apparently without changes, and referred to HOSPITAL SALGADO FILHO for evaluation by vascular surgery due to a diagnostic hypothesis of dissection of the aorta. After medical evaluation by the vascular surgery team and exclusion of vascular pathology, she was referred for care at the Medical Clinic, where a rapid COVID-19 test was performed, the result of which was negative and after additional tests, renal failure and severe arterial hypertension with creatinine were diagnosed. of 2.5 mg/dl, proteinuria of 4 g/24 h. Amlodipine 5 mg, pulse therapy with methylprednisolone for 3 days and maintenance with prednisone 40 mg per day (1 mg/kg) were prescribed, followed by referral to the Bonsucesso Federal Hospital for evaluation by Nephrology on October 20th.

At presentation, the patient was afebrile, blood pressure was 170/100 mmHg. New rapid COVID-19 test with negative result. Echocardiogram, electrocardiogram and chest x-ray were normal. Laboratory tests revealed serum creatinine of 2.1 mg/dl, urea 85 mg/dl, LDL 124.4 mg/dl, HDL 83 mg/dl, triglycerides 168 mg/dl, total cholesterol 244 mg/dl, hemoglobin 12.4 mg/dl, hematocrit 36.2%, leukocytes 2,690 mm³, platelets 336,000 mm³, albumin 3.5 g/dl, C3 and C4 were normal, ANA, Anti-SM, Anti-DNA, ANCA were non-reactive, anti-HIV, VDRL, Anti-HBs, HbsAg, Anti HBC, Anti-HCV were also non-reactive, in addition, the urine test showed protein 1+ and blood 1+, 24h proteinuria: 3,466mg/24h. Renal ultrasound showed kidneys with normal topography, the right kidney measuring 9.1x2.9 cm and the left kidney 9.5x3.5cm, without hydronephrosis.

Tomography of the abdomen and pelvis was normal, vascular images did not show thrombosis.

Without presenting a favorable evolution, a kidney biopsy was performed on October 28, 2021 (36 days after receiving the COVID-19 vaccine), without complications, and the results were obtained by optical microscopy: 05 glomeruli and 02 arteries in study status, 3 globally sclerotic glomeruli, 01 glomerulus with segmental sclerosing lesion with collapsed tufts and podocyte hyperplasia and hypertrophy, 01 glomerulus within normal limits, fibrosis and interstitial atrophy (FIAT), moderate to severe (30-40%), rare foci of tubular atrophy with cystification. Immunofluorescence: 03 glomeruli under study conditions, the presence of segmental and global IgM 3+ was observed, in 02 glomeruli and C3, Kappa and lambda similar to IgM. Figure 1 The conclusion of the renal biopsy was segmental and focal glomerulosclerosis, collapsing variant, affecting 01 of 02 viable glomeruli, with moderate tubulo-interstitial repercussion (30-40%). Apolipoprotein 1 genotyping was performed, which showed high G1/G1 risk.



Obtido de: os
autores 2022

Figure 1 Kidney biopsy.

The glomeruli are completely sclerosed, retracted and the vascular poles are collapsed.

He was discharged for outpatient control with creatinine 2.1mg/dl and proteinuria 1.4g/24h, maintaining Prednisone 40mg/day, Amlodipine 5mg 12/12h, Hydralazine 25mg 8/8h, Losartan 50mg/day. At the outpatient clinic, he presented progressive loss of renal function, associated with treatment with Tacrolimus 2mg/day for 2 months, a decrease in proteinuria to 680mg/24h, but with an increase in creatinine to 3.4mg/dl. Tacrolimus was suspended and switched to Mycophenolate Mofetil 1g/day associated with corticosteroids. It progressed with worsening renal function, creatinine of 4.3mg/dl and proteinuria to 2.2g/24h, and persistence of arterial hypertension. Currently (after one year and in the middle of the onset of symptoms), the patient presented worsening kidney function, started hemodialysis on January 27, 2023 and is currently awaiting Kidney Transplant.

The patient developed rapidly progressive glomerulonephritis, with renal failure and nephritic/nephrotic syndrome after administration of the first dose of the COVID-19 vaccine (Pfizer-BioNTech). The causality between the vaccine and glomerular disease has not yet been established, but the presence of a high-risk APOL1 genotype may predispose to the disease.

Discussion

This clinical case report occurred in Brazil, referring to a 16-year-old female patient, with no significant personal history, who received the first dose of the COVID-19 vaccine (Pfizer-BioNTech) and three days later presented with headache, abdominal pain and arterial hypertension, and after carrying out complementary tests, he developed nephritic/nephrotic syndrome, renal failure, due to a collapsing variant

focal and segmental glomerulosclerosis, the possible association of the clinical picture with immunization is questioned. Collapsing glomerulopathy may be associated with various inflammatory conditions such as systemic lupus erythematosus, glomerular ischemic injury (thrombotic microangiopathy and sickle cell disease), medications (anthracycline, pamidronate and interferon), infections (HIV, hepatitis B and C, parvovirus B19, cytomegalovirus and Epstein-Barr virus). Recently, a new etiological agent was found, the infection produced by the coronavirus. Segmental and focal collapsing glomerulosclerosis, after COVID-19 infection, is more common in patients with a personal history of kidney disease. Regarding the vaccine for the prevention of COVID-19 disease, to date no studies are confirming the development of kidney disease after immunization.

However, there are case reports of patients with a personal history of kidney disease, who after vaccination experienced worsening of their underlying disease, and also in kidney transplant recipient (KTR) patients, who developed GESFC after vaccination for COVID-19 as This is the case of a 14-year-old patient in Australia, a stable recipient of KRT and who received the Oxford/AstraZeneca vaccine, and within fifteen days he developed severe acute kidney injury (creatinine, 6.0 mg/dl, baseline, 1.4 -2.1 mg/dl) and proteinuria in the nephrotic range, without hematuria. Kidney biopsy demonstrated features compatible with collapsing glomerulonephritis (GC), with acute tubular injury.¹⁰ Another case reported after the application of the first vaccine for COVID-19 was a 54-year-old male patient with chronic kidney disease secondary to autosomal dominant polycystic kidney disease, who underwent kidney transplantation from a living donor in 2013, and who, after immunization with the first dose of the SARS-CoV-2 vaccine, mRNA-1273 (Moderna), presented edema in the lower limbs accompanied by proteinuria in the nephrotic range of 7810 mg/24h, with a slight increase in creatinine of 1.3mg/ dl, plasma albumin at the lower limit of 3.7g/dl and low total protein of 5.8g/dl. Biopsy revealed collapsing glomerulonephritis.¹¹

As another example, the existence of 2 cases of collapsing glomerulopathy after a vaccine based on the adenovirus vector (AdV) of SARS-CoV (Oxford/AstraZeneca) is also reported. In the first case, a 63-year-old female patient, with a history of hypertension, heart failure and dyslipidemia, started 9 days after immunization with the first dose of the Oxford/AstraZeneca vaccine, presented with ankle edema, foamy urine, and tests showing insufficiency. renal disease, the patient also had only 1 risk allele for APOL1 (G1/G0) which, according to current medical literature, is not associated with an increased risk of kidney disease.¹² In the second case, a 58-year-old female patient, with a personal history of multiple myeloma and Chronic Kidney Disease due to cylindrical myeloma nephropathy, after receiving the first dose of the Oxford-AstraZeneca vaccine, presented with pulmonary congestion, massive and acute edema associated with abrupt worsening of kidney disease, the patient had high-risk genotype (HRG) -APOL1 (G2/G2), a genetic condition that had already been associated with an increased risk of collapsing glomerulosclerosis and chronic kidney disease.¹² What is similar to our patient's case is that the presence of a high-risk APOL1 genotype was also determined, which may have predisposed her to the presentation of the disease. Both mRNA and AdV vaccines generate strong neutralizing antibody titers and virus-specific T-cell responses, a study of BNT162b2 (Pfizer-BioNTech) revealed a cumulative incidence of acute kidney injury of 0.005%, mRNA-1273 (Moderna) 1 in 15,185 cases and no description of renal events in Ad26.COVS (Janssen/Johnson & Johnson).¹²

A study carried out in Mexico in 2021 showed that the vaccine for COVID-19 is the main causative agent of glomerulopathy, but

the highest percentage of reported cases were related to the mRNA vaccines (both Pfizer-BioNTech and Moderna) and the appearance of full-blown glomerular disease after the first or second dose of immunization. A lower number of cases of nephropathies have also been reported with the single-dose viral vector (adenovirus) vaccine (AstraZeneca) along with the inactivated virus-based vaccine (Sinovac).⁸ After reviewing clinical cases of patients who presented with kidney disease after vaccination, it was suggested that the condition predominates in patients with a history of kidney disease, but our patient did not present any significant personal history. Similarly, the next case reported was a 29-year-old male patient who, similarly, previously healthy, sought emergency care due to oliguria and edema (an increase of 10kg), which occurred 7 days after the Pfizer-BioNTech vaccination for Covid-19, renal biopsy performed 31 days after vaccination revealed diffusely enlarged glomeruli and mesangial hypercellularity. Of the 20 glomeruli presented, one (5.0%) exhibited FSGS, with proliferation of overlying podocytes. Treated with prednisone, diuretics, angiotensin receptor blockers and statins, after 10 weeks the patient was asymptomatic and with normal laboratory tests, also in this case, it was suggested that the COVID-19 vaccine was related to the administration of an mRNA vaccine, which can induce strong innate and adaptive immune responses. Among these responses, the T-cell response causes the rapid production of cytokines such as interferon-gamma, tumor necrosis factor alpha and interleukin-2, which could trigger podocytopathies and glomerulonephritis.¹³

Although we cannot prove definitive causality, we believe that FSGS in this case could have been caused by a COVID-19 mRNA vaccine for the following reasons: First, a healthy patient suddenly presents with nephrotic syndrome 7 days after immunization. The onset of disease at this time was consistent with previous reports of the COVID-19 mRNA vaccine generating T follicular helper (Tfh) cell responses peaking 7 days after immunization. The Tfh population generated by the mRNA vaccine and the associated cytokine system in susceptible patients may promote podocyte injury; second, previous reports have shown the development of recurrent FSGS lesions 1 to 2 months after kidney transplantation. further supporting that the sclerotic lesions visible in this case may be a consequence of a rapidly progressive podocytopathy triggered by a COVID-19 mRNA vaccine; Third, many viral infections, including COVID-19, are well-known triggers of glomerular injury and stimulate de novo and recurrent GN. Because the mRNA itself can be highly immunogenic, like an intact mRNA virus, the immune responses induced by the COVID-19 mRNA vaccine are analogous to the immune responses induced by the COVID-19 virus, and both result in de novo and recurrent glomerulonephritis. Of note, Focal Segmental Glomerulosclerosis in our case was a non-collapsing cellular variant, whereas COVID-19-induced Focal Segmental Glomerulosclerosis is more commonly the collapsing type.^{9,13} However, since the start of large-scale vaccination, several immune-mediated reactions (including myocarditis and recurrent or de novo glomerulonephritis) have been reported. COVID-19 vaccines have also been reported to generate T-cell activation. Therefore, the occurrence of kidney disease after administration of an mRNA COVID-19 vaccine may be related to the T-cell-mediated immune response that it generates, triggering podocyte injury.^{11,12}

Conclusion

The association of collapsing glomerulosclerosis with COVID-19 viral infection is well established, as a large percentage of patients infected with COVID-19 have developed kidney disease. However,

in the context of vaccination, there are few reports to date. Mass vaccination against the SARS-CoV-2 virus may have adverse effects, Roberta Fenoglio recently published an evaluation of 17 cases of post-vaccination glomerulopathy, most related to minimal glomerular lesions. Although it is not possible to conclusively determine whether there is a causal relationship between vaccination against SARS-CoV-2 and new-onset nephropathies, based on the appearance of urinary abnormalities (UA) and/or renal failure shortly after vaccination, there is a hypothesis that the response to the COVID-19 vaccine by the immune system could be a trigger for nephropathies.¹⁴ Furthermore, the presence of a high-risk APOL1 genotype may predispose to the presentation of the disease, therefore, physicians must be aware of the possibility of developing glomerulopathy associated with vaccination, and continue with vaccination campaigns to reduce the aggressiveness of the aforementioned disease. More studies are needed to verify the cause and risk factors of FSGS related to the administration of the COVID-19 vaccine as well as the mechanisms of kidney injury after immunization with COVID-19.

Acknowledgments

None.

Conflicts of interest

The authors declares that there are no conflicts of interest.

References

1. Maguiña Vargas C, Gastelo Acosta R, Tequen Bernilla A. The new Coronavirus and the Covid-19 pandemic. *Hereditaria medical journal: official organ of the "Alberto Hirtado" School of Medicine, Peruvian Cayetano University Heredia, Lima, Peru.* 2020;31(2):125–131.
2. Santillan Haro A. Epidemiological characterization of COVID-19 in Ecuador. *Inter-American Journal of Medicine and Health.* 2020;3:1–7.
3. Ndwandwe D, Wiysonge CS. Vaccines for covid-19. *Current Opinion in Immunology.* 2021;71:111–116.
4. Picasso J. Vaccine against COVID-19. *Rev Esp Quimioter.* 2021;34(6):559–598.
5. Cairoli E, Espinosa G. Autoimmune diseases and vaccines against COVID-19: decision making in uncertain scenarios. *In Clinical research: development and innovation.* 2021;157(5):247–252.
6. Esparza J, Vizcaíno G, Pujol FH. Vaccine-Associated thrombosis against Covid-19 based on adenoviral vectors: implications for vaccination Pfizer BioNTech or Moderna Venezuela. *Cient Med.* 2021;2(28):1–7.
7. Aguirre Morales N, Gómez-Henao C, Calle AM. Adverse reactions associated with COVID-19 vaccines. *Ces Medicine.* 2021;35(3):230–243.
8. Caza T, Larsen CP, Walker PD, et al. Glomerular disease in temporal association with SARS-CoV-2 RNA vaccination: a series of 16 cases. *Journal of the American Society of Nephrology.* 2021;32:88.
9. Bomback AS, Kudose S, D'Agati VD. De novo and relapsing glomerular diseases after COVID-19 vaccination: what do we know so far? *American Journal of Kidney Diseases: The Official Journal of the National Kidney Foundation.* 2021;78(4):477–480.
10. Jefferis J, Kassiano AJ, Grivei A, et al. SARS-CoV-2 vaccination – associated collapsing glomerulopathy in a kidney transplant recipient. *Kidney Int.* 2022;101(3):635–636.
11. Preciado FG, Ovalles RADC, Codina S, et al. Collapsing glomerulonephritis in a kidney transplant recipient after SARS-CoV-2 mRNA vaccination. *Journal of Clinical Medicine.* 2022;11(13):3651.
12. Neves PD, Caires RA, Guimarães MP, et al. Collapsing glomerulopathy after SARS-CoV-2 adenovirus vector-based vaccine: report of 2 cases. *Kidney Int.* 2022;101(3):637–639.
13. Lim CA, Lee HS, Yoon S, et al. Focal segmental glomerulosclerosis after Pfizer-BioNTech COVID-19 vaccine. *Kidney Research and Clinical Practice.* 2022;41(2):263–266.
14. Roberta Fenoglio, Stefania Lalloni, Martina Marchisio, et al. New onset of nephropathy confirmed by biopsy after vaccination against COVID. *Am J Nephrol.* 2022;53(4):325–330.