

A rare case of uterine arteriovenous malformation masquerading as retained products of conceptus: a case report

Volume 14 Issue 3 - 2024

Introduction

An Arteriovenous malformation (AVM) is essentially an abnormal vascular structural anomalous connection between arteries and veins that bypass the capillaries.¹ While they can be found anywhere in the body, uterine AVMs are relatively rare with only about 100 cases having been reported in literature to date. Herein, we describe an atypical presentation and subsequent management of a uterine AVM which initially appeared to resemble products of conceptus. It is important to differentiate between the two conditions since the management of the former differs widely from the latter and involves a specialized unit.

Case details

A 32-year-old female, para 2, living 2 with a history of two previous medical termination of pregnancies reported to the Gynaecology outpatient at St. George's Hospital, Mumbai with complaints of persistent spotting per vaginum with usage of 2-3 pads per day since one month and complaints of weakness gradually worsening over two weeks. On examination, her pulse was tachycardic with a heart rate of 114 beats/minute, her blood pressure was 90/60 mm of Hg with the presence of generalized pallor. On per abdominal examination, abdomen was soft and there were no signs of acute abdomen. A per speculum examination showed presence of bleeding from the internal os while on a bimanual per vaginal examination, the uterus was found to be bulky, and bilateral fornices were free and non-tender. On detailed questioning, the patient stated that she had amenorrhea for 2 months prior to this bleeding episode and had started spotting per vaginum around 25 days back which has aggravated over the last 7 days or so.

A urine pregnancy test turned out to be negative. On sonographic evaluation, the uterus was 5.4cmX5.1cmX7.3cm (mildly bulky) with heterogeneous echotexture with echogenic areas measuring 2.1cm X 1.87cm X cm2.1 cm with few anechoic areas within and increased vascularity (PSV: 64 cm/sec) within the myometrium which extended into the endometrial cavity. Multiple dilated veins were seen in bilateral adnexa. This led to a differential of uterus arteriovenous malformation (AVM) versus grade 3 retained products of conceptus (RPOC). Considering the high PSV and the type of vascular flow within the myometrium, the diagnosis was more inclined towards AVM (Figure 1).

To be double sure, we tested her beta HCG level which was 36.7 mIU/ml. We performed a pelvic angiogram for better visualization. It showed hypertrophied bilateral uterine arteries and intrauterine spiral arteries with prominent uterine blush, bilateral external iliac arteries and infrarenal abdominal aortogram was normal. In view of these findings, uterine artery embolization was decided upon.

All routine pre-procedure workup was done wherein the patient was found to be severely anaemic with a hemoglobin level of 6.2 g/dL. All of her other investigations were within normal limits. Two

Rajshree D Katke,¹ Sanchari Pal,² Avinash Gutte,³ Shubhangi Nawarange⁴

¹Professor and Head of Unit, Department of Obstetrics and Gynaecology, Grant Government Medical College and St. George's Hospital, India

²Senior Resident, Department of Obstetrics and Gynaecology, Grant Government Medical College and St. George's Hospital, India

³Professor and Head, Department of Radiodiagnosis, Grant Government Medical College and JJ Hospital, India

⁴Assistant Professor, Department of Obstetrics and Gynaecology, Grant Government Medical College and St. George's Hospital, India

Correspondence: Rajshree D Katke, Professor and Head of Unit, Department of Obstetrics and Gynaecology, Grant Government Medical College and St. George's Hospital, Mumbai, India, Email drrajshrikatke@gmail.com

Received: September 03, 2024 | **Published:** September 23, 2024

bags of packed cells were transfused to optimize the hemoglobin to 9.6 g/dL and she was taken up for the embolization with right femoral access. Uterine artery embolization (UAE) has been proven to be a highly successful treatment modality for AVM due to the non-invasive and quick resolution of symptoms.

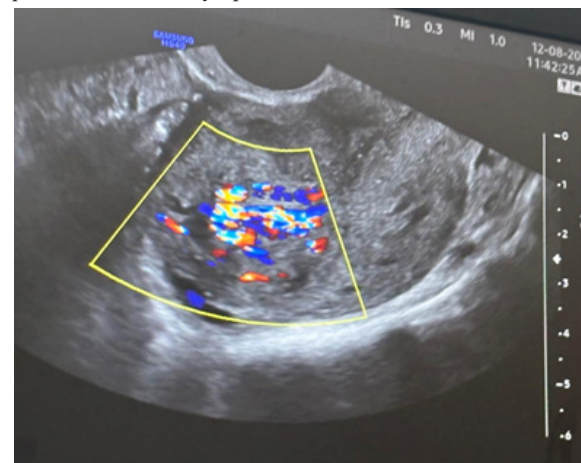


Figure 1 Doppler flow showing increased vascularity within the uterine AVM.

Furthermore, it avoids the associated complications of operative interventions like hysterectomy. Super selective catheterization on the right femoral artery was done using Progreat™ micro catheter and embolization was carried out using polyvinyl (PVA) 150-250 microns particles. Postprocedural angiogram revealed near total (99%)

reduction in vascularity of mass lesion. Post procedure recovery of the patient was uneventful. Her bleeding had stopped completely and she was discharged after one full day of observation post the procedure.

The patient was asked to follow up one week after the procedure wherein she had no complaints at all and had recovered completely. Presently, she has been called for monthly follow-up on long term basis (Figure 2&3).



Figure 2 Pre-embolization DSA showing vascular supply.

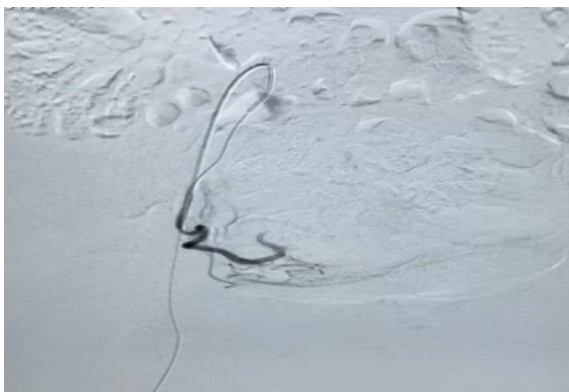


Figure 3 Postembolisation DSA showing reduced vascularity (upto 99%).

Discussion

As per the Mulliken and Glowaki classification system, AVMs can be divided into: (i) high-flow vascular malformations wherein a high-pressure gradient across the arterial and venous system enables a high vascular flow through the nidus comprising of the intervening network of vessels communicating the arteries to the veins; (ii) a direct communication representing a fistulous connection between the arteries and veins without the presence of a nidus.² While AVMs can be found anywhere in the body, uterine AVMs are rare entities with only about 100 cases having been reported so far in literature.³

Uterine AVMs can be either congenital or acquired. Congenital AVM is believed to arise from arrested vascular embryologic development resulting in anomalous differentiation in the capillaries and abnormal communication, between arteries and veins.⁴

When acquired, AVM formation may have a history of some obstetric or Gynaecological surgeries; or may develop in the presence of some pre-existing uterine pathology. They usually present with intractable bleeding which doesn't resolve with normal medical

measures. Often, such bleeding can be life-threatening with the patient developing complications like massive hemoperitoneum and hypovolemic shock.⁵

In the past, AVMs were traditionally diagnosed by laparotomy or incidentally, during examination of the uterus after a hysterectomy.⁶ Presently, ultrasound with color Doppler studies is primarily used to detect this rare condition. While it is safe and non-invasive with no radiation exposure, to date, digital subtraction angiography remains the gold standard of diagnosis.⁶

As seen in our case, hyper vascular retained products of conceptus can be a confusing differential diagnosis for uterine AVMs. Back in 2000, Timmerman, had reported two such cases wherein placental tissue was found in the histopathological studies of patients who were initially diagnosed with uterine arteriovenous malformations.⁷ Sometimes, gestational trophoblastic disease (GTD) might also have similar ultrasound findings of increased uterine vascularity. However, GTD is usually accompanied by increased beta HCG levels.⁸

A lot of patients have a history of procedures like dilatation and curettage, myomectomy etc. Before being diagnosed with an AVM. On detailed elicitation of the history of our patient, we found out that she had a history of intake of Mifepristone and Misoprostol almost one month before she visited us. However, she had not undergone any procedures. The tablets were prescribed to her by a quack given a weakly positive urine pregnancy test, without any sonographic evaluation.

Historically, the primary treatment modality for uterine AVMs was hysterectomy⁹ owing to the often hemodynamically unstable nature of the patients.⁵ However, with advancements in interventional radiology, transcatheter vascular embolization (TCE) is a viable alternative treatment option for patients wishing to preserve fertility. While there has been some concerns about the long-term effects of uterine artery embolization (UAE) on future fertility, there are numerous occasions where patients have conceived with live births post embolization, albeit the rates might be lower.¹⁰

Notably, such patients, when they do conceive later, might have a mildly increased risk of abnormal placentation disorders like placenta accreta syndrome.¹¹ Our patient had two children, and presented to us with tachycardia and hypotension; UAE could save her uterus and the associated complications of having to perform an emergent hysterectomy while also preserving her fertility. Both unilateral and bilateral embolization's may be performed. The choice of laterality is dependent on the feeder vessel to the AVM as seen in angiography.²

Rarely, other treatment modalities may be attempted for patients who are hemodynamically stable but not consenting to UAE due to its fertility implications. UAE is generally attempted with caution in patients who are planning future fertility even though uterine arteries recanalize spontaneously with time.¹⁰ Expectant management, oral contraceptive pills, intramuscular or oral methotrexate have been shown to resolve AVMs in some cases.⁴

Hysteroscopic approach to an AVM wherein the vascular lesion has been resected successfully have been attempted by competent surgeons¹² but one has to remember that this is fraught with the risk of profuse intraoperative bleeding which might even necessitate an emergent hysterectomy.

Currently, the cons of UAE remain its uncertain effect on future fertility and in case of successful conception, the increased risks of abnormal placentation along with its associated risks. Having said all that, UAE remains the most preferred modality for effective treatment

of uterine AVMs. Rapid advancements in interventional radiology is only expected to increase the popularity of this treatment modality.

Conclusion

There is no standard treatment guideline for uterine AVMs since it is an infrequent entity. It is safe to say that each case has to be individualized depending on the patient's symptoms, hemodynamic status, fertility goals and accessibility of medical resources. Hysterectomy for uterine AVMs has largely taken a backseat and is reserved only for life threatening cases in relatively resource-poor areas. For most others, UAE could very well be the treatment of choice that is minimally invasive and preserves fertility as well. Such is the simplicity and minimal adverse effects of the procedure that, in resource-rich settings with the availability of competent infrastructure, UAE is often chosen as the first-line treatment nowadays.

Acknowledgments

None.

Conflicts of interest

The authors declare that there is no conflicts of interest.

References

1. Lowe LH, Marchant TC, Rivard DC, et al. Vascular malformations: classification and terminology the radiologist needs to know. *Semin Roentgenol.* 2012;47(2):106–117.
2. Yoon DJ, Jones M, Taani JA, et al. A systematic review of acquired uterine arteriovenous malformations: pathophysiology, diagnosis, and transcatheter treatment. *AJP Rep.* 2016;6(1):e6–e14.
3. Katimada AT, Kodakkattil SS. Uterine arteriovenous malformations: clinical implications. *Obstetrician & Gynaecologist.* 2015;17(4).
4. Grivell R, Reid K, Mellor A. Uterine arteriovenous malformations: a review of the current literature. *Obstet Gynaecol Survey.* 2005;60(11):761–767.
5. D Katke R, Domkundwar SC, Rathod S. Uterine arterio-venous malformation with hemoperitoneum. *JCR.* 2014;4:60–63.
6. Grivell R, Reid K, Mellor A. Uterine arteriovenous malformations: a review of the current literature. *obstet gynaecol survey.* 2005;60(11):761–767.
7. Timmerman D, Bosch TVD, Peeraer K. Vascular malformations in the uterus: ultrasonographic diagnosis and conservative management. *Euro J Obstet Gynaecol Reprod Biol.* 2000;92:171–178.
8. Gillespie A, Hancock B. *Gestational Trophoblastic Disease.* 3rd ed. 2009.420–429.
9. Yokomine D, Yoshinaga M, Baba Y et al. Successful management of uterine arteriovenous malformation by ligation of feeding artery after unsuccessful uterine artery embolization. *J Obstet Gynaecol Res.* 2009;35(1):183–188.
10. Mohan PP, Hamblin MH, Vogelzang RL. Uterine artery embolization and its effect on fertility. *J Vasc Interv Radiol.* 2013;24(7):925–930.
11. Soeda S, Kyozuka H, Suzuki S, et al. Uterine artery embolization for uterine arteriovenous malformation is associated with placental abnormalities in the subsequent pregnancy: two cases report. *Fukushima J Med Sci.* 2014;60(1):86–90.
12. Calzolari S, Cozzolino M, Castellacci E, et al. Hysteroscopic management of uterine arteriovenous malformation. *JSLs.* 2017;21(2):e2016.00109.