

# Single-unit cantilevered resin-bonded bridge: an alternative for maxillary lateral incisor replacement

## Abstract

Fixed partial denture (FPD) prostheses restore esthetics and function by connecting and fixing to adjacent teeth. Conventional FPDs require, for better retention and resistance, extensive preparations. Those preparations include buccal, palatal or lingual coverage, proximal guide planes, chamfers and /or grooves to optimize retention.<sup>1-4</sup> The removing of such large amount of tooth structure increases the risk of periodontal complications and pulp exposure.<sup>1,3</sup> In 1973, Rochette introduced resin bonded FPDs as a less invasive therapeutic option. He pioneered the use of lingual perforated cast alloy framework with acid etch composite for periodontal splinting of the anterior region.<sup>5</sup> However, early Rochette bridges presented high failure rates. Since then, resin bonded FPDs have evolved with different framework materials and designs. Even though metal frameworks are highly resistant, they do have esthetical and mechanical limits such as the greyish appearance of the abutment teeth and dislodgment by the early loss of retention.<sup>2-4,7</sup> This led to introducing metal free FPDs, also widely developed thanks to adhesive dentistry. The preparation designs for RBFDPs were strictly limited to the enamel. Studies revealed a survival rate of 86% after 3 years without retentive preparation.<sup>6</sup> All Ceramic RBFDPs have been introduced in the early nineties of the last century as a treatment option for missing incisors. Adhesive dentistry has undergone major transformations in current concepts. It has launched new resin bonded FPD designs that allowed to be more conservative such as single unit cantilevered ceramic bridges which become the most commonly used design when replacing lateral incisor especially when implant supported crowns cannot be indicated.<sup>8</sup> Placing an implant is not always possible in cases where there is an insufficient bone height or width or for patients with general pathologies that may limit implant indications. That is why in some cases it is compulsory to indicate an FPD. Anterior ceramic RBFDPs showed promising results and high survival rates. They have proved to be viable and reliable alternative.<sup>8</sup>

**Keywords:** oligodontia, lateral incisor, implant, orthodontia, fixed partial denture, cantilevered bridge, bonding

Volume 15 Issue 2 - 2024

El Ayachi Islam, Riahi Zeineb, Ben Othmen Ilhem, Amara Marwa, Nouira Zohra, Omezzine Moncef, Jilani Saafi, Hadyaoui Dalenda, Harzallah Belhassen

Department of Fixed Prosthodontics, Faculty of Dental Medicine of Monastir, University of Monastir, Research Laboratory of Occlusodontics and Ceramic Prostheses, Tunisia

**Correspondence:** Dr. El Ayachi Islam, DDM, Department of Fixed Prosthodontics, Research Laboratory of Occlusodontics and Ceramic Prostheses LRI6ES15, Faculty of Dental Medicine, University of Monastir, TN 5000, Email ayachiisl23@gmail.com

**Received:** April 09, 2024 | **Published:** April 30, 2024

## Introduction

Tooth agenesis is a frequent congenital human craniofacial abnormality that may be caused by genetic variations and/or environmental factors.<sup>9,10</sup> However, the extent to which genetic and/or environmental factors are involved remains unknown.<sup>11,12</sup> Studies reported a different prevalence of dental agenesis according to the type of dentition, group of teeth, and race.<sup>13,14</sup> It has also been described that it affects 1.37 times females more than males.<sup>16,17</sup> After third molars, maxillary lateral incisors (MLI) have been documented to be the most frequently missing teeth among permanent teeth.<sup>18-20</sup> According to a retrospective study that has been conducted on a sample including 1000 patients during a 6 year period, in the Department of Orthodontics at the Dental Medicine Clinic in Monastir, the congenital absence of MLI was about 3.6% over 7.8% of general tooth agenesis.<sup>21</sup>

The management for agenesis of the MLI primarily offers an alternative between two options: either space closure or space opening via orthodontic treatment. Prosthodontic treatment is often required as an adjunct to orthodontic therapy. The ideal treatment should be the most conservative option that satisfies both esthetic and functional requirements. Space opening for missing MLI is reported to be advantageous, as it provides harmonious facial and tooth development, respects the arch symmetry and allows an ideal intercuspation of canines.<sup>22</sup> In addition, creating an orthodontic space requires minimal equilibration and reshaping on sound teeth.<sup>23,24</sup> When enough space is available in the maxillary arch, an implant-supported replacement should be considered as the most conservative treatment option.

## Case presentation

A 24-year-old healthy female patient with congenitally missing both upper lateral incisors was referred to the department of fixed prosthodontics in the dental clinic of Monastir. She had recently completed orthodontic treatment that included space opening for eventual dental implants. However, radiographic showed insufficient apical inter dental bone volume which did not allow implant placement. Clinical examination revealed bilateral missing maxillary lateral incisors, short edentulous span, a slight deep bite and bilateral class I molar and canine relationships with canine guidance (Figure 1, 2).

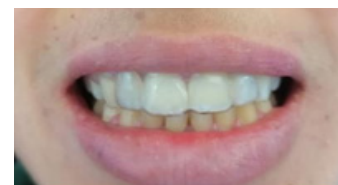

Figure 1 Pre-operative extra-oral view.

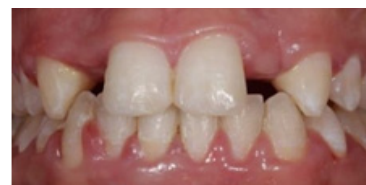

Figure 2 Pre-operative intra-oral view.

Since the occlusal bite in the anterior teeth was located in the third incisal of the palatal surface of maxillary teeth, we have retained the indication of a cantilevered RBFDP. We selected central incisors as abutment teeth since they provide sufficient surface area for bonding with their overall length. The occlusal scheme was marked with an articulator paper to identify impact points. Our preparation limits were then located behind these impact points. (Figure 3) Teeth preparation was entirely restricted to the enamel surface. Palatal surfaces of maxillary central incisors are reduced with a round shaped bur about 0.7mm of the enamel are removed with a supra-gingival finish line (Figure 4).

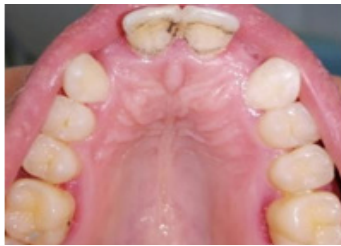

Figure 3 Palatal scheme of the preparation.

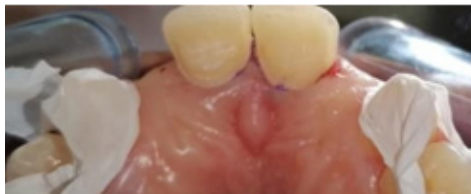

Figure 4 Palatal limits of the preparation.

Palatal preparation is extended to interproximal surfaces to optimize retention. Interproximal preparations adjacent to edentulous sites included interproximal contacts (Figure 5, 6). All line and angles are rounded and prepared for digital impression. A silicone impression was conducted then transferred to dental laboratory. The FPD was manufactured. Prior to cementing, IPS emax RBFDPs were carefully positioned with try-in pastes to verify marginal adaptation, shape, color and occlusion (Figure 7). Internal surfaces of the restorations were conditioned with an 8% hydrofluoric acid for 20 seconds, washed with water and air-dried to be then, silaned (Figure 8, 9). Abutment surfaces of the teeth were etched with a 37% phosphoric acid for 30s then washed and dried (Figure 10, 11). A total etch adhesive system was applied with a 20 s photoactivation. (Figure 12)

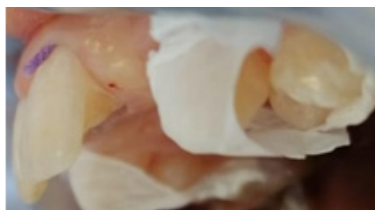

Figure 5 Proximal limits of the preparation.

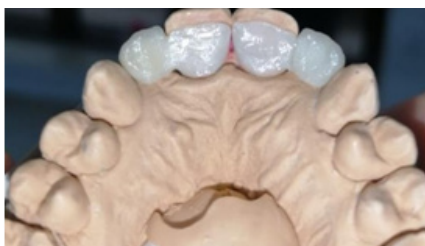

Figure 6 IPS emax single-unit cantilevered bridges.

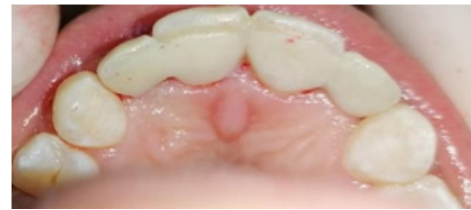
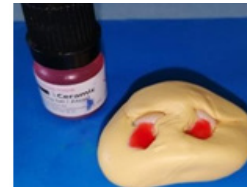
Figure 7 Intra-oral trying of the restorations.



Figures 8 Etching of the internal surfaces of restorations.

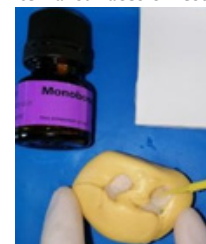
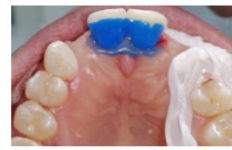
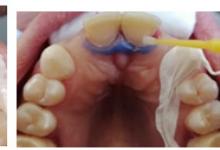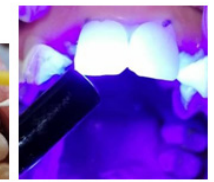Figure 9 Silanization of the restorations.



10



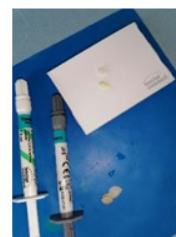
11



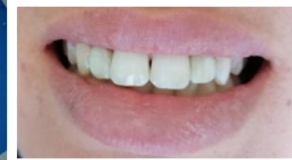12

Figures 10,11,12 Teeth conditioning with a Total-Etch system.

VARIOLINK dual resin cement was applied on the internal surfaces of the restorations and carefully positioned on the preparations (Figure 13). The resin bonded bridge was cemented using bonding resin cement after isolation of the teeth with a light cured isolation (Figure 14). Excess was removed and proceeded to an occlusion control. The patient was instructed to clinical controls every 6months (Figure15).



13



14

Figures 13,14 Final cementation of the restorations.

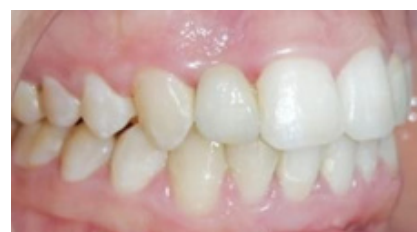

Figure 15 Final result after a two-weeks control.

## Discussion

Oligodontia condition can affect physical, intellectual and psychological maturation of the patient.<sup>25</sup> Its prosthodontic management is important for functional and esthetic rehabilitation. Opening of the space with orthodontic means provides excellent esthetic outcomes and maintains or creates canine guidance. Canine guidance is biologically desirable and has predictable functional results as it protects the future prostheses.<sup>26</sup> Advocates of space closure would argue periodontal conditions with dental or implant supported prostheses.

They have reported the worst periodontal conditions caused by bacterial plaque retention on teeth abutting conventional fixed denture due to excessive contours and maladaptation.<sup>27</sup> Implant supported prostheses in the anterior region could be responsible of major esthetic defects such as gingival retraction,<sup>28</sup> interdental black triangles<sup>29</sup> and infracclusion.<sup>28,30–34</sup> Moreover, a canine-protected occlusion may not be considered as completely stable. It tends to be replaced by group function because of the inevitable physiological wear.<sup>27,34,35</sup> However, Clinicians have to recognize, that space closure is not always possible and that alternative strategies will be needed.<sup>36,37</sup>

Once a suitable sized space has been achieved, different prosthetic options can be available such as implant supported crowns, conventional or adhesive fixed partial denture and even removable prostheses. At this point of the treatment, it is important to discuss different treatment options with the patient. Our patient agreed to an implant treatment.

However, her CBCT showed an insufficient apical bone volume due to the close proximity of the adjacent roots.<sup>38</sup> Among tooth-supported restorations, conventional fixed bridges are considered as the most invasive option. It has been reported that peripheral preparation removes 63% to 72% of the total sound tooth structures.<sup>39,40</sup> Which increases the risk of endodontic treatment for young patients with an important pulp volume.<sup>40,41</sup> RBFDP was first described by Rochette as a technique for splinting mandibular anterior teeth with compromised periodontal state.<sup>40,42</sup>

Metal frame RBFDPs were introduced in the mid-1970s. Howe and Denehy advocated the use of perforated metallic retainers to optimize retention of the luting agent.<sup>43</sup> In early 1980s, Metal-ceramic RBFDP, widely known as Maryland, were presented with an electrolytic etching of the metal surface.<sup>40</sup> Livaditis and Thompson developed a method for etching non perforated metal alloys in order to protect the resin interface from abrasion and leakage.<sup>44,45</sup> It has been reported that RBFDPs with two-retainer design were responsible of dramatic decays mainly caused by frequent partial unilateral debonding.<sup>43,47</sup> Authors explained partial debonding by the difference of dental mobility between the abutment teeth.<sup>48,49</sup>

In order to prevent premature failure, preparation strategies have changed. Tooth preparation should provide a definite outline form and path of insertion for the restoration, therefore optimizing resistance and retention forms. It included slots,<sup>50</sup> grooves,<sup>51</sup> seats,<sup>52,53</sup> to promote mechanical resistance. However, such preparations sacrificed additional tooth structure which lowers the value of the abutment teeth and made them prone to developing caries and fracture. RBFDPs with two retainer design demonstrated a high incidence of unilateral fracture leaving the pontic bonded to a single retainer.<sup>53,54</sup> Debond rates of RBFDP supporting more than one pontic (52%) was double that the frameworks supporting a single pontic.<sup>55</sup>

Kern et al reported a 5-year survival rate reaching 92% for cantilevered RBFDP compared to a 74% rate for traditional two-

retainer designs.<sup>56</sup> All-ceramic RBFDPs demonstrated higher resin bond strengths than fracture strengths.<sup>53,57,58</sup> In order to enhance mechanical properties of RBFDPs, they were transformed into cantilevered designs that provide to be able to minimize shear and torque forces caused by differential movement on the abutments during function.<sup>53,59,60</sup> Metal-ceramic cantilevered RBFDPs recorded high success rates.<sup>53,61,62</sup> However, its main esthetic problem was related to the greyish aspect of the metal framework when bonded to the lingual surface.<sup>63</sup> All-ceramic cantilevered RBFDPs proved to be a reliable conservative prosthetic design that serves either as a minimally invasive definitive prosthesis therapy.<sup>53</sup> They offer better esthetics and less biological damage. This type of bridge provides a similar quality of life that of those with implants. Analysis of the failure modes on zirconia RBFDPs showed 100% adhesive fractures located at the interface of resin-zirconia. Alumina or zirconia ceramics contain lower or non-existent glass phase which may be responsible for inadequate adhesion.<sup>62,63</sup>

## Conclusion

The progress in adhesive dentistry has brought us to reconsider tooth preparation designs. Cantilevered, all-ceramic RBFDPs combine minimally invasive preparation and bond strength. Those restorations should be presented to the patients as a sustainable alternative to implant therapy.

## Acknowledgments

None.

## Conflicts of interest

The authors declare that there are no conflicts of interest.

## References

- Behr M, Leibrock A, Stich W, et al. Adhesive-fixed partial dentures in anterior and posterior areas. Results of an on-going prospective study begun in 1985. *Clin Oral Investig*. 1998;2(1):31–35.
- Botelho M. Resin-bonded prostheses: the current state of development. *Quintessence Int*. 1999;30(8):525–534.
- el-Mowafy O, Rubo MH. Resin-bonded fixed partial dentures—a literature review with presentation of a novel approach. *Int J Prosthodont*. 2000;13(6):460–467.
- Keulemans F, De Jager N, Kleverlaan CJ, et al. Influence of retainer design on two-unit cantilever resin-bonded glass fiber reinforced composite fixed dental prostheses: an in vitro and finite element analysis study. *J Adhes Dent*. 2008;10(5):355–364.
- Balasubramaniam GR. Predictability of resin bonded bridges – a systematic review. *Br Dent J*. 2017;222(11):849–858.
- Boening KW, Ullmann K. A retrospective study of the clinical performance of porcelain-fused-to-metal resin-bonded fixed partial dentures. *Int J Prosthodont*. 2012;25(3):265–269.
- Djermal S, Setchell D, King P, et al. Long-term survival characteristics of 832 resin-retained bridges and splints provided in a post-graduate teaching hospital between 1978 and 1993. *J Oral Rehabil*. 1999;26:302–320.
- Kern M. Fifteen-year survival of anterior all-ceramic cantilever resin-bonded fixed dental prostheses. *J Dent*. 2017;56:133–135.
- Amini F, Rakhshan V, Babaei P. Prevalence and pattern of hypodontia in the permanent dentition of 3374 Iranian orthodontic patients. *Dent Res J (Isfahan)*. 2012;9(3):245–250.

10. Rohilla M. Etiology of various dental developmental anomalies –review of literature. *J Dent Probl Solut.* 2017;4(2):19–25.
11. Woodworth DA, Sinclair PM, Alexander RG. Bilateral congenital absence of maxillary lateral incisors: a craniofacial and dental cast analysis. *Am J Orthod.* 1985;87(4):280–293.
12. Gomes RR, da Fonseca JA, Paula LM, et al. Prevalence of hypodontia in orthodontic patients in Brasilia, Brazil. *Eur J Orthod.* 2010;32(3):302–306.
13. Antunes LAA, Freire JS, Da Silva GIM, et al. Assessment of oral health–related quality of life in adolescents, young adults, and adults with dental agenesis: a comparative study. *Spec Care Dentist.* 2019;39(6):587–592.
14. Mohamed FF, Ge C, Binrayes A, et al. The role of discoidin domain receptor 2 in tooth development. *J Dent Res.* 2020;99(2):214–222.
15. Rosenzweig KA, Garbaski D. Numerical aberrations in the permanent teeth of grade school children in Jerusalem. *Am J Phys Anthropol.* 1965;23(3):277–283.
16. Mahaney MC, Fujiwara TM, Morgan K. Dental agenesis in the dariusleut hutterite brethren: comparisons to selected Caucosoid population surveys. *Am J Phys Anthropol.* 1990;82(2):165–177.
17. Polder BJ, Van't Hof MA, Van der Linden FP, et al. A meta–analysis of the prevalence of dental agenesis of permanent teeth. *Community Dent Oral Epidemiol.* 2004;32(3):217–226.
18. Celikoglu M, Kazanci F, Miloglu O, et al. Frequency and characteristics of tooth agenesis among an orthodontic patient population. *Med Oral Patol Oral Cir Bucal.* 2010;15(5):e797–e801.
19. Fekonja A. Hypodontia in orthodontically treated children. *Eur J Orthod.* 2005;27(5):457–460.
20. Dalle I, Marwen W, Abdallah SB, et al. Agenesis of the upper lateral incisors: Study of an orthodontic population and clinical illustration. *Int Orthod.* 2018;16(2):384–407.
21. Wong TL, Botelho MG. The fatigue bond strength of fixed versus cantilever resin– bonded partial fixed dental prostheses. *J Prosthet Dent.* 2014;111(2):136–141.
22. McNeill RW, Joondeph DR. Congenitally absent maxillary lateral incisors: treatment planning considerations. *Angle Orthod.* 1973;43(1):24–29.
23. Nordquist GG, McNeill RW. Orthodontic vs. restorative treatment of the congenitally absent lateral incisor: long term periodontal and occlusal evaluation. *J Periodontol.* 1975;46(13):139–143.
24. Abu–Hussein M, Abdulgani A, Watted N, et al. Congenitally missing lateral incisor with orthodontics, bone grafting and single–tooth implant: a case report. *J Dent Med Sci.* 2015;14(4):124–130.
25. Westgate E, Waring D, Malik O, et al. Management of missing maxillary lateral incisors in general practice: space opening versus space closure. *Br Dent J.* 2019;226(6):400–406.
26. Silveira GS, de Almeida NV, Pereira DM, et al. Prosthetic replacement vs space closure for maxillary lateral incisor agenesis: a systematic review. *Am J Orthod Dentofacial Orthop.* 2016;150(2):228–237.
27. Thilander B. Orthodontic space closure versus implant placement in subjects with missing teeth. *J Oral Rehabil.* 2008;35(Suppl 1):64–71.
28. Rinchuse DJ, Kandasamy S, Sciote J. A contemporary and evidence–based view of canine protected occlusion. *Am J Orthod Dentofacial Orthop.* 2007;132(1):90–102.
29. Thilander B, Odman J, Lekholm U. Orthodontic aspects of the use of oral implants in adolescents: a 10–year follow–up study. *Eur J Orthod.* 2001;23(6):715–731.
30. Jemt T, Ahlberg G, Henriksson K, et al. Changes of anterior clinical crown height in patients provided with single–implant restorations after more than 15 years of follow–up. *Int J Prosthodont.* 2006;19(5):455–461.
31. Robertsson S, Mohlin B. The congenitally missing upper lateral incisor. a retrospective study of orthodontic space closure versus restorative treatment. *Eur J Orthod.* 2000;22:697–710.
32. De Marchi LM, Pini NI, Hayacibara RM, et al. Congenitally missing maxillary lateral incisors: functional and periodontal aspects in patients treated with implants or space closure and tooth re–contouring. *Open Dent J.* 2012;6:248–254.
33. Storey AT. Functional stability of orthodontic treatment: occlusion as a cause of temporomandibular disorders. In: Nanda R, Burstone CJ, editors. Retention and stability in orthodontics. Philadelphia: Saunders. 1993:20
34. Kokich VO Jr, Kinzer GA, Janakievski J. Congenitally missing maxillary lateral incisors: restorative replacement. *Am J Orthod Dentofacial Orthop.* 2011;139(4):435,437,439.
35. Edelhoff D, Sorensen JA. Tooth structure removal associated with various preparation designs for anterior teeth. *J Prosthet Dent.* 2002;87(5):503–509.
36. Tezulas E, Yildiz C, Evren B, et al. Clinical procedures, designs, and survival rates of all–ceramic resin–bonded fixed dental prostheses in the anterior region: a systematic review. *J Esthet Restor Dent.* 2018;30(4):307–318.
37. holtz G, Nyman S. Endodontic complications following periodontal and prosthetic treatment of patients with the advanced periodontal disease. *J Periodontol.* 1984;55(2):63–68.
38. Rochette AL. Attachment of a splint to enamel of lower anterior teeth. *J Prosthet Dent.* 1973;30(4 Pt 1):418–423.
39. Howe DF, Denehy GE. Anterior fixed partial dentures utilizing the acid–etch technique and a cast metal framework. *J Prosthet Dent.* 1977;37(1):28–31.
40. Livaditis GJ, Thompson VP. Etched castings: an improved retentive mechanism for resin– bonded retainers. *J Prosthet Dent.* 1982;47(1):52–58.
41. Barwacz CA, Hernandez M, Husemann RH. Minimally invasive preparation and design of a cantilevered, all–ceramic, resin–bonded, fixed partial denture in the esthetic zone: a case report and descriptive review. *J Esthet Restor Dent.* 2014;26(5):314–323.
42. Botelho M. Design principles for cantilevered resin–bonded fixed partial dentures. *Quintessence Int.* 2000;31:613–619.
43. Djemal S, Setchell D, King P, et al. Long–term survival characteristics of 832 resin– retained bridges and splints provided in a post–graduate teaching hospital between 1978 and 1993. *J Oral Rehabil.* 1999;26(4):302–320.
44. Chan AW, Barnes IE. A prospective study of cantilever resin bonded bridges: an initial report. *Aust Dent J.* 2000;45(1):31–36.
45. Bassi GS, Youngson CC. An in vitro study of dentin exposure during resin–bonded fixed partial denture preparation. *Quintessence Int.* 2004;35(7):541–548.
46. Rammelsberg P, Pospiech P, Gernet W. Clinical factors affecting adhesive fixed partial dentures: a 6–year study. *J Prosthet Dent.* 1993;70(4):300–307.
47. Simon JF, Gartrell RG, Grogono A. Improved retention of acid–etched fixed partial dentures: a longitudinal study. *J Prosthet Dent.* 1992;68(4):611–615.
48. Barrack G, Bretz WA. A long–term prospective study of the etched–cast restoration. *Int J Prosthodont.* 1993;6(5):428–434.
49. Kern M, Strub JR. Bonding to alumina ceramic in restorative dentistry: clinical results over up to 5 years. *J Dent.* 1998;26(3):245–249.
50. Wyatt CC. Resin–bonded fixed partial dentures: what's new? *J Canad Dent Assoc.* 2007;73(10):933–938.

51. Kern M. Clinical long-term survival of two-retainer and single-retainer all-ceramic resin-bonded fixed partial dentures. *Quintessence Int.* 2005;36(2):141–147.
52. Kern M, Douglas WH, Fechtig T, et al. Fracture strength of all-porcelain, resin-bonded bridges after testing in an artificial oral environment. *J Dent.* 1993;21(2):117–121.
53. Hussey DL, Pagni C, Linden GJ. Performance of 400 adhesive bridges fitted in a restorative dentistry department. *J Dent.* 1991;19(4):221–225.
54. Kern M, Glaser R. Cantilevered all-ceramic, resin-bonded fixed partial dentures: a new treatment modality. *J Esthet Dent.* 1997;9(5):255–264.
55. Lam WY, Botelho MG, McGrath CP. Longevity of implant crowns and 2-unit cantilevered resin-bonded bridges. *Clin Oral Implants Res.* 2012;24(12):1369–74.
56. Botelho MG, Nor LC, Kwong HW, et al. Two-unit cantilevered resin-bonded fixed partial dentures- a retrospective, preliminary clinical investigation. *Int J Prosthodont.* 2000;13(1):25–8.
57. Kern M, Sasse M. Ten-year survival of anterior all-ceramic resin-bonded fixed dental prostheses. *J Adhes Dent.* 2011;13(5):407–410.
58. Sasse M, Eschbach S, Kern M. Randomized clinical trial on single retainer all-ceramic resin-bonded fixed partial dentures: influence of the bonding system after up to 55 months. *J Dent.* 2012;40(9):783–6.
59. Abu-Hussein M, Watted N, Abdulgani A, et al. Treatment of patients with congenitally missing lateral incisors: is an interdisciplinary task. *RRJDS.* 2014;2(4):53–68
60. Abu-Hussein M, Abdulgani A, Watted N, et al. Management of congenitally missing lateral incisors with orthodontics and single-tooth implants(a case report: after one year clinical follow-up). *JMSCR.* 2015;3(3):5011–5019.
61. Abu-Hussein M, Watted N, Abdulgani A, et al. Modern treatment for congenitally missing teeth : a multidisciplinary approach. *Int J Maxillofac Res.* 2015;1(2):179–190.
62. Sillam CE, Cetik S, Ha TH, et al. Influence of the amount of tooth surface preparation on the shear bond strength of zirconia cantilever single-retainer resin-bonded fixed partial denture. *J Adv Prosthodont.* 2018;10(4):286–290.
63. Lehmann KM, Weyhrauch M, Bjelopavlovic M, et al. Marginal and internal precision of zirconia four-unit fixed partial denture frameworks produced using four milling systems. *Materials (Basel).* 2021;14(10):2663.