

LUMBAR DISCREPLACEMENT

Larry T. Khoo M.D., Fred H. Geisler M.D. Ph.D., J.J. Abitbol M.D.

1. Introduction

Multiple intervertebral disc procedures have been developed to deal with abnormalities in the intervertebral disc. These include herniation of the nucleus pulposus, degenerative disc disease, and segmental instability. In recent years, the diagnostic accuracy and description of these abnormalities have been aided by the development of water-soluble myelography, MRI, provocative discogram, diagnostic blocks, and high resolution CT scan techniques with both intravenous and intrathecal contrast. Over the past 15 years, multiple therapeutic advances have also occurred to aid in managing intervertebral disc disease. These have included rigid segmental pedicle screw fixation (which has been shown to enhance the fusion rate over a non-instrumented fusion), single fiber carbon cage, and allograft spacers placed in the anterior column to promote anterior column fusion, demineralized bone matrix, platelet derived autologous growth factor (AGF), bone morphogenic proteins (BMP), and numerous bone graft extenders to eliminate or minimize iliac bone graft harvested during a lumbar fusion procedure. There has also been recognition over the last decade that interbody stabilization and arthrodesis, in addition to posterior instrumentation and arthrodesis, enhances the total lumbar joint fusion rate. The interbody fusion can be accomplished either anteriorly through a separate incision or posteriorly via a PLIF or TLIF approach. Laparoscopic surgery has also been used in spinal surgery for anterior cage insertion and minimally invasive techniques posteriorly and posterolaterally have been developed. There are also several intradiscal therapies with internal decompression of the disc center or heating of the posterior annulus to minimize the

patient's surgical discomfort while potentially relieving some symptoms of low back disorder.

2. Advantages of an Artificial Disc

All of the above techniques, however, either patch over the true disease process or eliminate the joint motion and its normal physiological function. With lumbar artificial disc technology, we now have the ability to fix the problem and restore normal anatomy and physiologic motion rather than simply fuse the back ^(2,4,5,7). Fusion works in many instances because the motion itself of the joint causes pain through its inability to comfortably support the weight of the body. Thus, when it is fused, it no longer moves and hence the motion cannot cause pain. The fusion does, however, cause stress and increased motion in the joints adjacent to the fused level as a direct effect of eliminating motion at the fused level. The theory behind an artificial disc in the lumbar area would be to not only preserve the motion but additionally to correct the abnormal motion that would be present in the degenerative disc and to restore the disc height, lordosis and a normal instantaneous axis of rotation. By doing so, the joints adjacent to the dynamically stable segment would not be subject to abnormal loads and motions. It is hoped with this new technology of artificial lumbar disc that the good results, which have followed the introduction of artificial knees and hips, will likewise be seen in the lumbar spine ⁽¹⁾.

The advantage of the artificial lumbar disc compared with a lumbar fusion is that it reproduces the biomechanics of the normal disc. Additionally, it would reduce the mechanical forces transmitted to the adjacent segments. It has the promise of slowing

or halting the degenerative changes at the adjacent levels. Performing a total discectomy eliminates the chance of a disc herniation and will hopefully retard spondylosis, stenosis, and instability at the dynamically stabilized segment. By restoring the anatomic disc height, the artificial disc would increase the exiting foraminal height and prevent compression on the exiting nerve roots at the level stabilized.

The typical diseased lumbar segment which is considered for artificial lumbar disc treatment is often collapsed in vertical height and has loss of normal lordosis, Modic endplate changes in the bodies adjacent to the effected disc space, and little motion on flexion/extension. Because of the mechanical changes in the degenerative condition in the disc space, this natural disease process is already placing more forces on the adjacent levels. The application of an artificial lumbar disc will restore normal motion, height, and lordosis, and the forces on the adjacent level will be decreased. Thus, an artificial lumbar disc may have beneficial effects compared to the natural history of the unoperated degenerative state.

3. Artificial Lumbar Disc Design

The design of a lumbar artificial disc has multiple very strict requirements. These devices must have superb mechanical strength and endurance. They are designed to last several decades, as many of these devices will be implanted in young individuals. Mechanical testing of 100,000,000 motion cycles over a 40-year life span would be a typical design criteria. The base materials need to be biocompatible with no significant surrounding inflammatory reaction either due to the base material reaction or secondary to any debris. The devices need to induce no organotoxic or carcinogenic reaction from the base material or potential debris. The biomechanical functional movement requirements of an artificial lumbar disc are quite strict, as they need to replicate the full biomechanics of a normal disc. This normal motion includes translation and rotation in all three planes of motion – x, y, and z axes. The implant geometry and materials would determine the static configuration, dynamic motion, schematics, and any constrained nature of the motion. The exact placement of the lumbar artificial disc in the disc space is determined by its biomechanical design. Different designs will require different placement accuracy – the “sweet spot” for

the implant. Fixed pivot devices may need a higher placement precision than devices utilizing a sliding core or an elastopolymer.

History of the lumbar artificial disc goes back to Fernstrom 35 years ago, who first placed spherical metal balls in the disc space. It was noted that a majority of these patients had ball migration into the vertebral body with subsequent collapse of the disc space. Relatively recently, a nucleus pulposus replacement with a hygroscopic gel or fluid filled cylindrical sacs has been developed for use after a standard discectomy in which the annulus is still holding the disc space to a normal height. These are currently under development and have not started a US FDA trial at the current time. Replacements of the entire disc after severe degenerative changes have several designs. These classes of designs have included mechanical bearing devices and a rubber/silicone/polymer nucleus between metal endplates made out of either chromium cobalt or titanium, with the potential of bony ingrowth surfaces at the endplates.

Although many different spinal dynamic stabilization systems go under the category of “artificial disc”, these need to be separated as they have different indications and potentially different applicable disease states. The first group of devices for the lumbar disc are intended to prevent the collapse of a lumbar disc space following a standard free fragment disc herniation surgery^(8,17,18). These devices are designed to be placed in the center of the disc to halt the secondary changes that would happen over the subsequent years and would hopefully provide stability over many decades, eliminating the need for fusion or rebuilding of the disc space at a later date. The second class of devices is for patients with severe degenerative disc disease with loss of the disc height but normal lordosis, instability of the disc, and little to no significant bony pathology posteriorly. This set of devices requires good facets, posterior ligaments, and muscular structures, as the aim to replace only the degenerative disc component of the entire lumbar joint. These are currently what will be termed “artificial lumbar discs” and will be the focus of the rest of this chapter.

Four different designs are currently in US FDA IDE trial currently. It is notable that these devices do not replace the posterior column degenerative changes, nor do they augment them. In fact, a contraindication to any of these devices would be a spondylo-

sis or significant spondylosis with facet hypertrophy and potential or ongoing nerve root compression. The third category of devices increases the posterior column stiffness^(6,14,15), with one currently in a US FDA IDE trial and others reported in European surgical series. The fourth class of devices is the total lumbar joint replacement, which would replace both anterior and posterior components. Currently, no devices are available in any US FDA trial, nor are any being implanted elsewhere in the world. In the lumbar spine, in addition to the hard implants, which have metal ends which attach onto the bony endplates, there are also some soft implants made either of all elastic with potential laminations or of a sac of fiber filled with some fluid or matrix^(9-11,16). Currently, none of the soft implants is in US FDA trials.

There are potential base material problems with all current technology solutions to the bearing surface for the hard lumbar artificial disc replacement designs. Broadly, these fall into three separate classifications: a metal-metal design, metal-ceramic design, or metal-plastic design. The metal-metal designs have the potential problem of metal and/or metal ionic debris; the metal-ceramic designs that the ceramic component may shatter, and that the metal on plastic design that of plastic wear. At first thought, the wear associated with a metal-plastic bearing surface would seem to exclude it from use in the lumbar spine because of excessive long-term wear. This initial opinion is an extrapolation from the well-known fact that the plastic components in the current artificial hips and knees have a 10-year lifetime and then require revision. As the lumbar artificial disc is made of these same base materials, chromium cobalt and high-density polyethylene, it thus might be inferred the lumbar artificial disc would also require the plastic cores to be replaced every ten years. There are three facts, however, which refute the seemingly common sense idea. First of all, with each step, the hip and the knee move approximately 50 degrees, whereas the lumbar spine will only tilt a few degrees. This greatly decreases the "sandpaper effect" by over an order of magnitude. Next, in the lumbar design, the high-density polyethylene is not constrained but is open on the sides. This is a marked contrast to the hips, where the plastic is constrained in a ball/socket-type joint. In the hip joints, the high-pressure points which arise at the constrained metal-plastic interface greatly accelerate the plastic wear. Because of the nonconstrained nature of the plastic

in the lumbar application, there are no wear-accelerated pressure points. Furthermore, there is good experience from Europe that there is no plastic wear in 10 years of implantation, verifying the estimation of the expected lifetime to be far greater than that of the hips and knees.

A separate class of dynamic stabilization devices is currently being studied and tested in the cervical spine. These devices, although also called "artificial disc", vary greatly from the artificial lumbar disc. First of all, the cervical discs are experiencing much lower loads than the lumbar discs, and they have different biomechanical characteristics. But more importantly, in the cervical spine, bony pathology and osteophytes causing radiculopathy and/or myelopathy dominate as causes for intervention, rather than pure axial disc pain, as is the case in the lumbar indication for an artificial disc. The potential patient groups to be studied and outcome variables would be quite different between the cervical and the lumbar artificial disc studies. Furthermore, the results in the lumbar area are not necessarily directly transferable to the cervical spine.

In summary, all artificial discs are not the same. There will be major biomechanical differences between cervical and lumbar implants in the design, the disease treated, and outcome expected. One needs to be concerned about the pathology one is treating, whether the disc is normal disc height, and the presence of degenerative disc disease, osteophytes, and facet disease.

3.a. Prodisc Artificial Lumbar Disc

Prodisc, from Spine Solutions, Inc., was recently acquired by Synthes-Stratec Spine. In a recent press release out of Oberdorf, Switzerland dated February 6, 2003 on their website, Synthes-Stratec listed the purchase price at \$350,000,000 and stated their belief that the global market potential for total disc replacement (Spine Arthroplasty) will grow to 3 billion by 2008. The initial Prodisc product design was designed in the late 1980s and used by Thierry Marmay, a French orthopedic spine surgeon. From 3/1990 to 2/1993, Dr. Marmay implanted this artificial disc in 64 patients. In 1999, he went back to examine these patients. He was able to locate 58 of the surviving 61 patients for a 95% follow-up at 7 to 10 years status post procedure. At that time, he found that all of the implants were intact and mechanically functioning. There had been

no implant removals, revisions, or failures. Furthermore, there was no evidence of subsidence into the bony endplate on follow-up radiographs compared with the peri-operative films. There was a highly significant reduction in patient reported back pain and leg pain, and 92.7% of these patients were either satisfied or extremely satisfied with the results of this procedure. In this study, 2/3 of the patients had a single level implant and 1/3 had two levels. No differences were noted between one and two level diseases. Most importantly, at this long-term follow-up there were no device-related safety issues, no untoward effects, no complications, and no adverse events. This Prodisc was based on spherical articulation and had metal endplates made of chromium cobalt alloy. The current Prodisc (Figure 1), which is now in US FDA

IDE trials, is two chromium cobalt endplates and a high-density polyethylene core, and is applied with an inserter no wider than the implant. It has a fin in the midline to help in the stabilization and positioning. Because the high-density polyethylene is fixed to the inferior plate, it functions as a fixed pivot design and the instantaneous axis of rotation is within the lower body rather than in the disc space.

3.b. Flexicore Artificial Lumbar Disc

Another design, which has just started US FDA IDE trials, is Flexicore (Figure 2). This is a metal-on-metal bearing surface of chromium cobalt. It is a 13mm ball-and-socket joint, which places the stationary center of rotation centrally between the endplates.

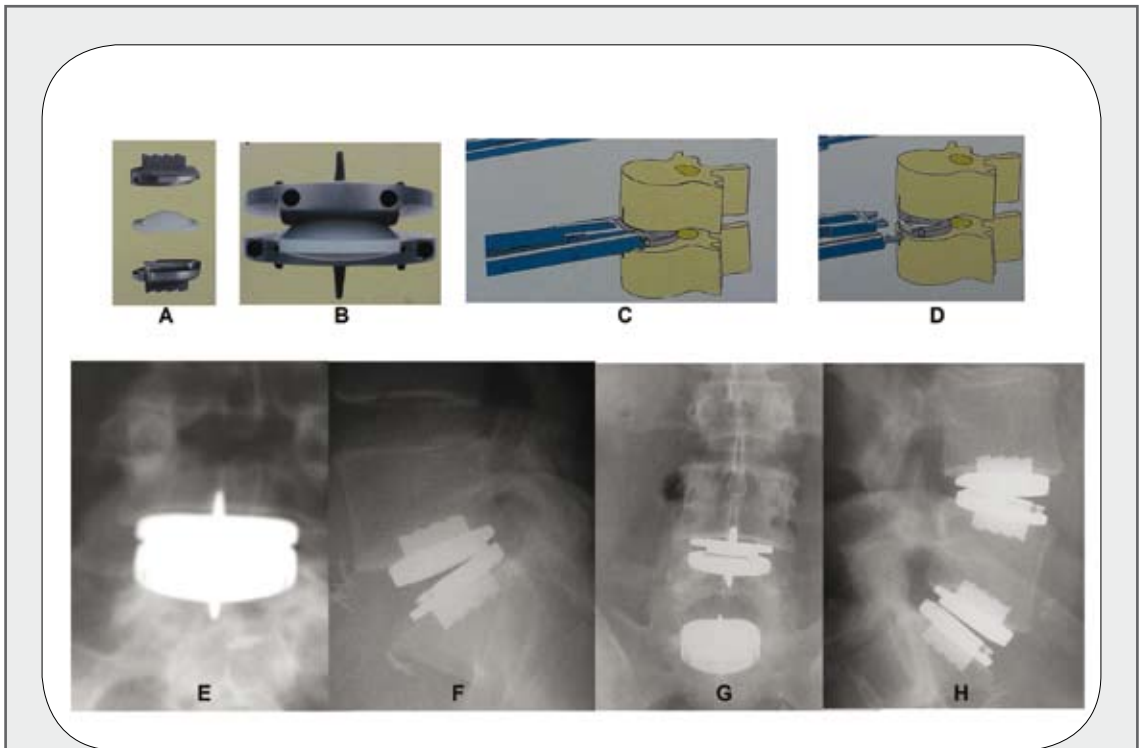


Figure 1:
Prodisc Artificial Lumbar Disc.

- A.** Expanded view showing the two metal endplates and polyethylene core which attach to the lower metal endplate.
- B.** Assembled Prodisc Artificial Lumbar Disc construct.
- C.** Inserter applying Prodisc Artificial Disc to inner space.
- D.** Prodisc in a disc space after detachment of the inserter.
- E/F.** A one-level L5-S1 Prodisc stabilization.
- G/H.** An L4-5 and L5-S1 two level Prodisc stabilization.

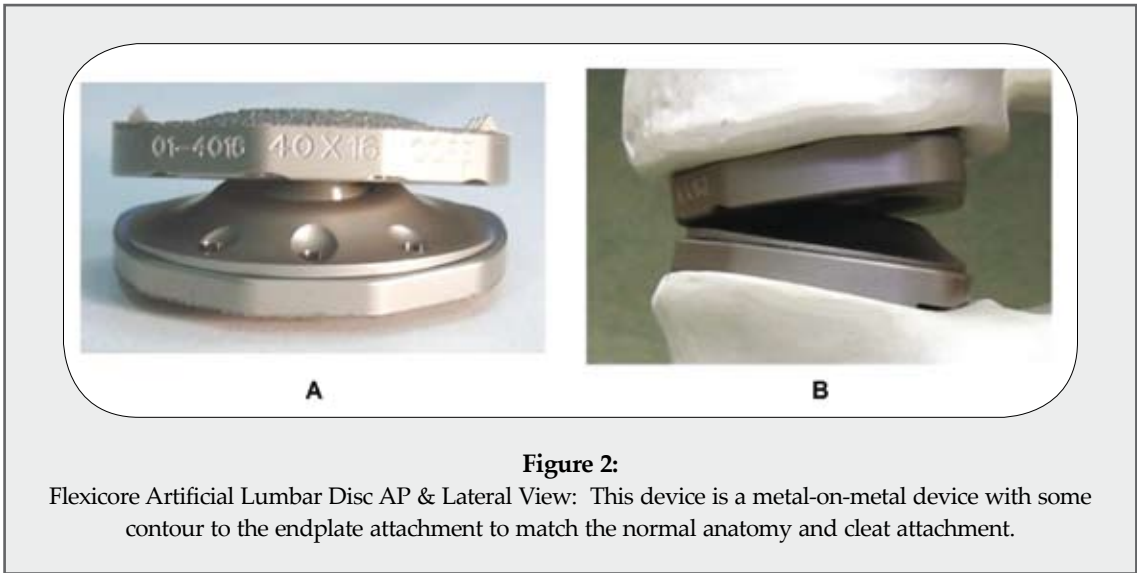


Figure 2:

Flexicore Artificial Lumbar Disc AP & Lateral View: This device is a metal-on-metal device with some contour to the endplate attachment to match the normal anatomy and cleat attachment.

3.c. SB Charité Lumbar Artificial Disc

The SB Charité was designed to restore disc space height and motion segment flexibility, and was specifically design to duplicate the kinematics and dynamics of a normal motion segment (12,13). It was de-

signed to restore anatomic lordosis, which will result in normal facet joint motion loading and unloading (Figure3). The SB Charité uses two metal alloy endplates of chromium cobalt and a high-density polyethylene free-floating core. The free-floating core of-




Figure 3:

SB Charité Artificial Lumbar Disc

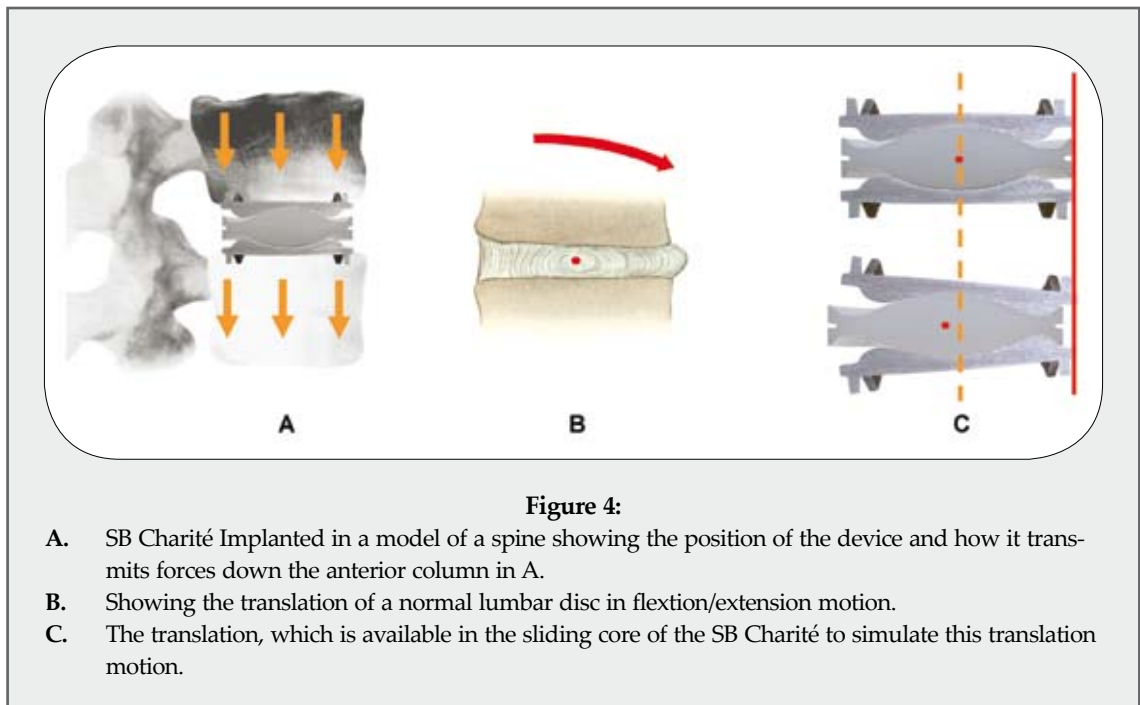
- A. Construct and disassembled parts showing the two metal endplates and ultra high-density polyethylene core.
- B. Shows the various size footprints which are available. The metal endplates are also available in different angulations.

fers the theoretical advantage of allowing the spacer to shift dynamically within the disc space during regular spinal motion, moving posteriorly in flexion and anteriorly in lumbar extension. This provides not only unloading of the posterior facet structures during this normal replication of motion, but also allows forgiveness for slight off-center positioning of the implant.

Several clinical studies have been published documenting the European experience with this disc since 1987. Worldwide experience with this unconstrained anatomic disc replacement is now greater than 10,000 cases. Several studies are historically notable. Cino-tti reported on 46 Italian patients in 1996 with 2 to 5 year follow-up. He noted no implant failures, but did report a re-operation rate of 19% for continued pain. Overall satisfaction was 63%. Lemaire reported his French series in 1997 following 105 patients with a mean follow up of 51 months with 79% good outcomes and no device failures. Zeegers reported 50 patients in 1999 in a Dutch series, which showed 70% good results with 2-year follow-up. The US FDA IDE study was launched in March 2000 with the Texas Back Institute as the principal institution. Since that time, all patients have been enrolled in the FDA multi-center study with complete 2 year follow up to be completed in December of 2003. Entry was finished at the end of 2001, and all patients will be past their

two-year follow-up at 2003 with prompt submission to the FDA plan. Currently, the centers that entered patients into the randomized FDA IDE study have access to the Charité disc on a limited basis as part of a continuing access study.

The SB Charité dynamic stabilizer comes in a variety of base metal sizes as far as the footplate to fit different sized disc spaces⁽¹²⁾. In addition, there are various endplate angles to match the distracted disc space anatomy. The plastic core is inserted between the two metal endplates and also comes in a variety of heights. The sizing of the endplates, angles, and heights are done intraoperatively. The SB Charité is implanted with metal endplates of chromium cobalt on the superior and inferior bony endplates of the disc space and a UHMW polyethylene core in-between the highly polished insert interfaces. There is a slight difference in the curvature between the polyethylene cores and the metal endplates, which allows the core to slide. Spinal forces are transmitted down through the anterior column in a normal manner after the disc is inserted. The core translation allows duplication of anatomic translation (Figures 4, 5 and 6). In the normal physiological circumstances, there is a slight translation during the flexion/extension motion and lateral bending motion. A normal disc is able to handle this translation. In sagittal rotation (flexion-extension) in the normal circumstance,



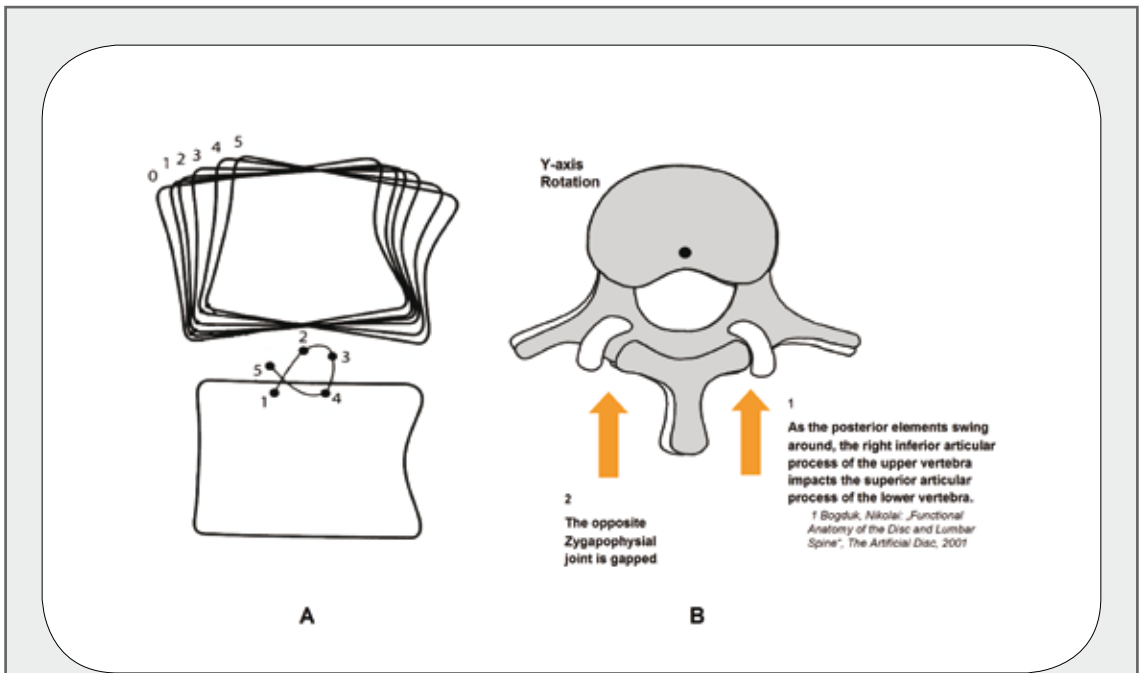


Figure 5:

- A.** Flexion/extension views showing the instantaneous axis of rotation in A and how it changes in a Greek alpha-type pattern during this motion.
- B.** Shows in pure y-axis rotation about a fixed point how the posterior elements would swing, causing more force on one facet than the other.

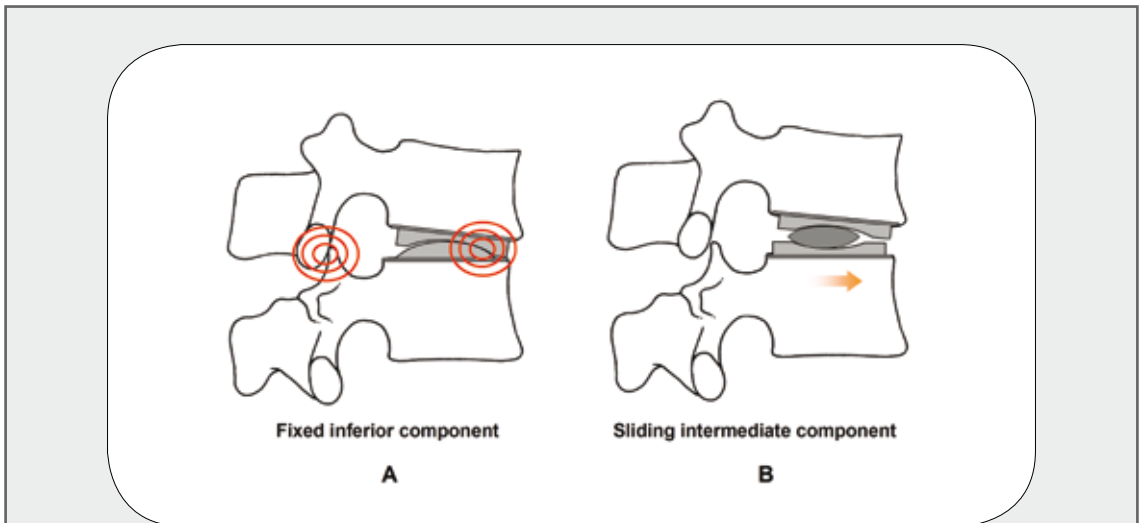


Figure 6:

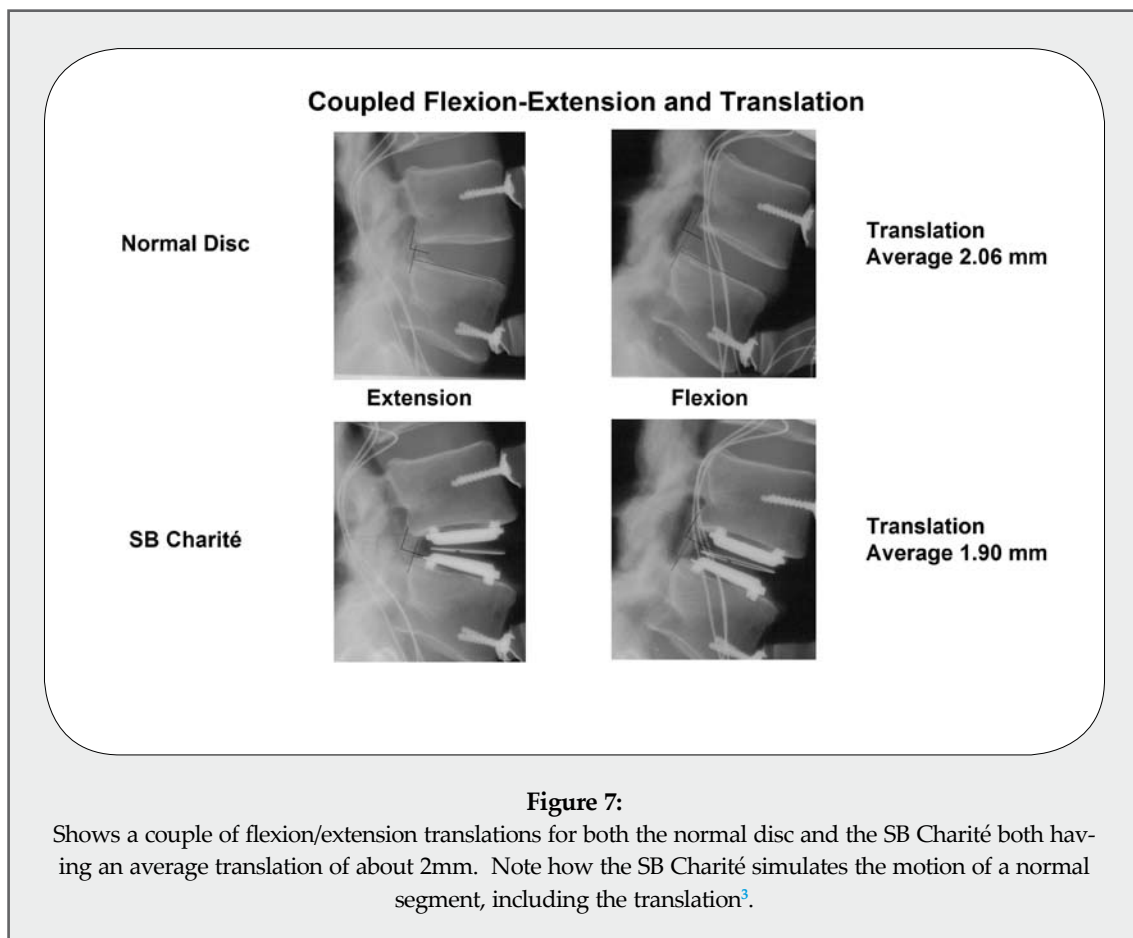
Comparing a fixed inferior component with a sliding intermediary component. In the fixed inferior component during flexion has more force near the front part of the Artificial Disc and potentially jamming of the facets posteriorly. This is in contrast to B where the sliding intermediary component allows translation release force both on the plastic core and the facets posteriorly.

the instantaneous axis of rotation, although generally in the center of the disc, moves in a pattern that duplicates the Greek letter alpha. The Charité duplicates this motion. Coronal motion, likewise, has this slight translation in order to reproduce the normal biomechanics of the intact disc space. Axial rotation also requires a slight coupled rotation-translation to reduce the forces on the posterior facets. Pure axial rotation on a pivot point in the disc space will result in direct compression of one facet joint while releasing the pressure on the other. If one compares a fixed pivot design to a sliding core design, the facet pressure would be more in a fixed pivot design than a sliding core design. The exact clinical benefit for those patients who are most helped by the sliding core design will be determined by the outcome of the clinical studies currently underway. It is evident from measurements of centers of intervertebral rotation in cadavers that the SB Charité not only preserves normal motion (Figure 7) at the repaired disc space, but also at adjacent levels³. Fusion has been

reported to greatly distort the instantaneous axis of rotation at adjacent levels³.

This mobile sliding core in the Charité artificial disc works in a similar fashion to the mobile knee bearing in many of the contemporary knee designs. In essence, this could be considered a second generation device or an advanced type design over a fixed pivot, much like the mobile core in the knee is considered an advanced design over fixed bearings. In biomechanical studies, this mobile sliding core results in true physiological restoration of the lumbar segment.

The SB Charité US FDA study studied one level disease only - L4-5 and L5-S1 (Figure 8). The patients had no radiculopathy, although they could have referred buttock or upper leg pain. Those patients with predominant pain below the knee were excluded from the study. Patients had a positive discogram with concordant pain, and most had MRI's showing collapsed disc space, black disc on T2 weighting



indicating decreased water content of the disc, and Modic endplate changes. There were no major social issues. This pivotal study enrolled 360 patients and was randomized between the SB dynamic stabilizer and a BAK stand alone ALIF with autologous iliac crest bone arthrodesis.

A typical patient x-ray is in [figure 8A](#) at L5-S1. The corresponding MRI shows the Modic endplate changes in the collapse of L5-S1, as well as some water loss in L4-5 in this particular patient ([Figure 8B](#)). The discogram would have excluded L4-5 as the significant pain generator. Another patient is shown in [Figure 8C](#) in which L4-5 is the major pain generator with a minor loss of water at L5-S1. In this patient, the L5-S1 disc space would have been excluded as a major pain generator by discography.

The surgical approach to the L4/5 and L5/S1 area is performed using standard general surgery tech-

niques to gain access to the retroperitoneal space and dissect the great vessels from the lumbar disc spaces⁽¹³⁾. In the surgical procedure, the anterior longitudinal ligament is opened for the width of the disc implant; a generous discectomy is performed, with care taken not to disturb the bony endplates, although all of the cartilaginous endplates are removed. The discectomy is enlarged to expose the cortical bone circumferential rim. Deviations from perfectly flat endplates are encountered usually posteriorly with a posterior lipping or slightfish mouthing noted. These are removed with a .25-inch chisel or a Kerrison punch. This disc space preparation is performed in anticipation of accepting the flat metal endplates of the Charité implant. Care needs to be taken during this stage not to damage the bony endplates, as these support the metal plates of the artificial disc. Additionally, especially at L5-S1, the anterior longitudinal ligament in the degenerative

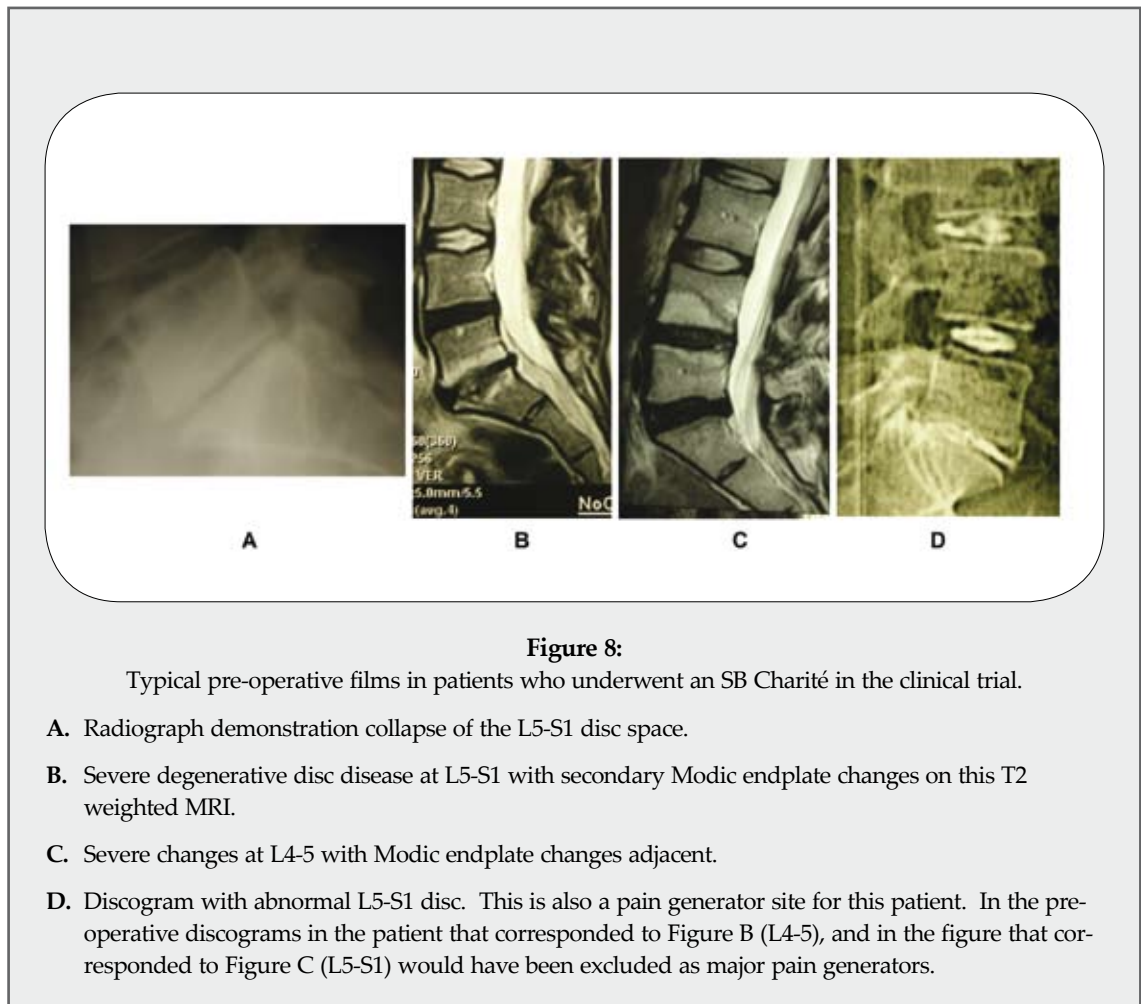


Figure 8:

Typical pre-operative films in patients who underwent an SB Charité in the clinical trial.

- A. Radiograph demonstration collapse of the L5-S1 disc space.
- B. Severe degenerative disc disease at L5-S1 with secondary Modic endplate changes on this T2 weighted MRI.
- C. Severe changes at L4-5 with Modic endplate changes adjacent.
- D. Discogram with abnormal L5-S1 disc. This is also a pain generator site for this patient. In the pre-operative discograms in the patient that corresponded to Figure B (L4-5), and in the figure that corresponded to Figure C (L5-S1) would have been excluded as major pain generators.

disease stage can be exceptionally thick (sometimes getting over 1cm). This needs to be removed to clearly define the anterior bony margin, such that when the implant is placed, it can be verified both with fluoroscopy as well as visually that the anterior cleats of the implant are below the anterior cortical margin. Once this is accomplished, a sizer is used to assess the disc space to choose the matching metal endplate footprint. A spreader is then placed into the disc space to perform parallel distraction. This parallel disc space distraction is accomplished by using a paint paddle-type instrument, which is placed within the spreader; the posterior ligament is actually stretched and/or ripped to some extent, increasing the posterior height of the disc space. Despite the heaviness of the distractor, closing only on the handles will effectively fishmouth the disc space distraction, opening up mostly only the anterior disc with little or no posterior distraction. The parallel distraction is accomplished by using force to twist the paint paddle instrument between the distractor blades and then just taking up the slack with the distractor handles. Once the disc space has been distracted, often additional disc material that was contained within the buckled ligament within the neural canal is delivered into the disc space. This is then removed with a Kerrison or biopsy punch. The distracted space may provide a better view of the posterior osteophytes and their removal is completed. Next, the metal endplates of the artificial disc are inserted and tapped into position. Care is taken to have the centerline marked as determined by fluoroscopy either with a burn mark or with a self-tapping 3.5mm screw placed within the bony body adjacent to the disc space. The screw is smooth on the top, allowing the great vessels to slide over if necessary and also providing an unambiguous unique marker. The screw is also seen on a A-P and lateral fluoroscopy. The metal endplates of the implant are impacted into the disc space, positioned posteriorly within the disc space, and then parallel distracted. At this expansion with the paint paddle instrument parallel distraction, it is essential that only the very lateral edges of the implant are touched, as one does not want to scratch the inside of the cups. Scratching the articulating metal cups of the implant would result in a very significant increase in the amount of plastic wear. Once the endplates have been put in, trial cores size the distracted space and then the final core is placed. Verification

is made that the plastic core is in the correct position to articulate with the cups and then distraction is fully taken off. Then with a slight tapping on the core, the endplate sliders are removed. During the procedure of the disc space distraction, in approximately 2/3 of the cases some epidural bleeding or significant bone bleeding along the posterior edge is encountered. This is easily handled with strips of Avitene placed in the disc space and then compressed down against the remaining posterior longitudinal ligament area with a standard 4x4 sponge. After allowing this to sit for approximately 2 to 3 minutes, the sponge can be removed, leaving the thin layer of Avitene in place. This is easier to do during the initial discectomy or after the metal endplates have been inserted than after the core is inserted. A-P and lateral fluoroscopy are used to aid in positioning the device and to provide final radiological verification. Visual verification is also used anteriorly to ascertain that the implant is recessed below the anterior cortical margin. A bone tamp is used on the sides of the metal endplates of the implant to do minor adjustments and also to impact the anterior cleats within the bony structure (Figures 9 through 14).

If the SB Charité were required to be revised, there would be two approaches. One approach would be to redo the anterior surgery. This would involve dissecting the retroperitoneal area and dealing with the postop scarring and hence increased risk of great vessel damage compared to an unoperated case. This would allow removal of the SB Charité lumbar disc. The plastic core would be removed first, and then the metal endplates could be separated from the bony endplates by using a chisel between them and levering away from the bone into the disc space. This would allow the placement of another artificial disc in the disc space, as the bony endplates would not be significantly damaged. Alternately, a posterior operation with rod-screw stabilization and posterior lateral fusion could be used to fuse the lumbar segment, which would use the SB Charité as an anterior load share. More important than the exact surgical technique used would be clinically characterizing the pain generator if the patient had reoccurring or persistent pain. This would have to be done by a variety of radiologic and provocative studies. Discogram at adjacent levels would be helpful, as would epidural facet injections, and potentially even an anesthetic discogram

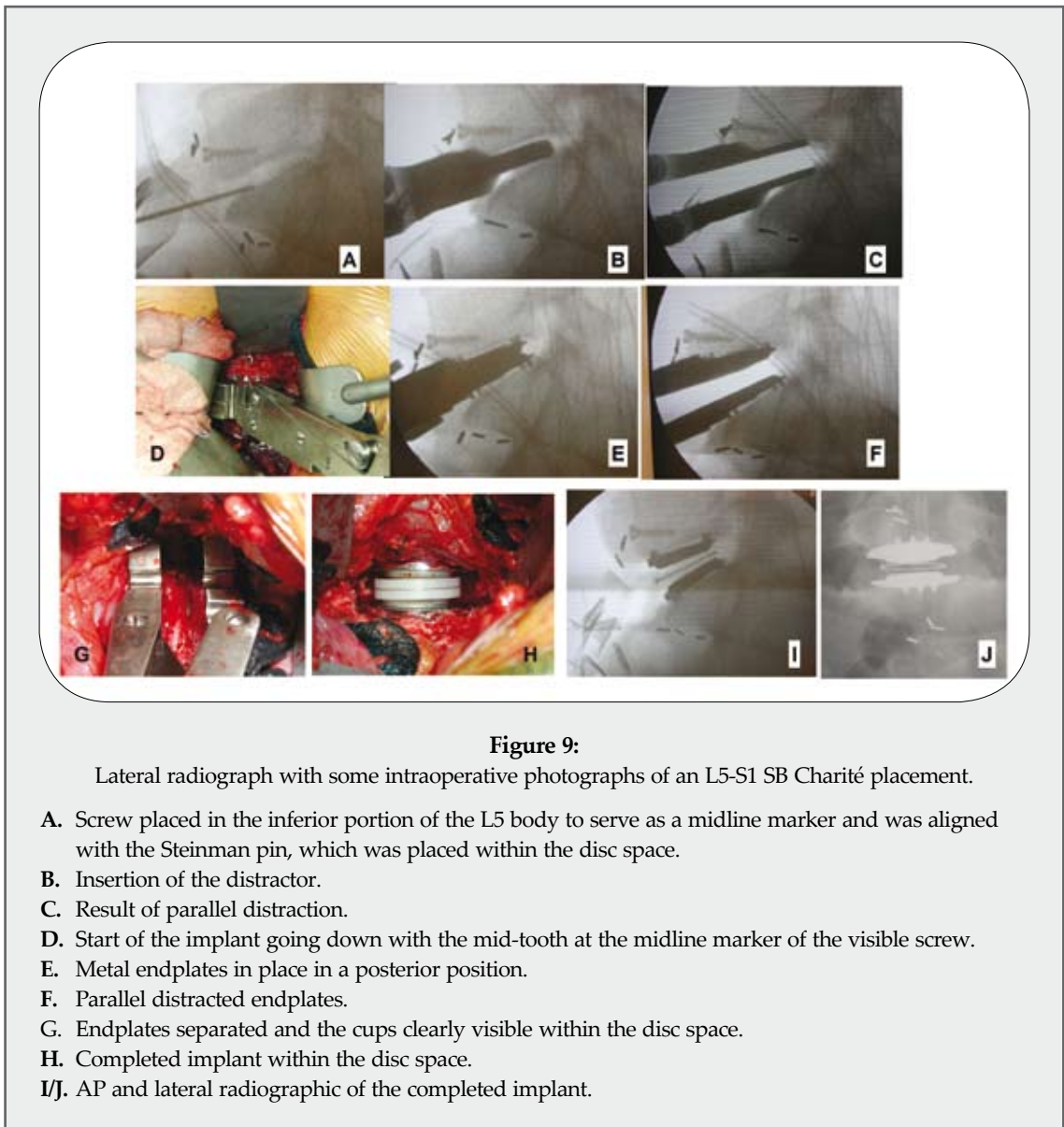


Figure 9:

Lateral radiograph with some intraoperative photographs of an L5-S1 SB Charité placement.

- A. Screw placed in the inferior portion of the L5 body to serve as a midline marker and was aligned with the Steinman pin, which was placed within the disc space.
- B. Insertion of the distractor.
- C. Result of parallel distraction.
- D. Start of the implant going down with the mid-tooth at the midline marker of the visible screw.
- E. Metal endplates in place in a posterior position.
- F. Parallel distracted endplates.
- G. Endplates separated and the cups clearly visible within the disc space.
- H. Completed implant within the disc space.
- I/J. AP and lateral radiographic of the completed implant.

at adjacent levels to see if that would remove a majority of the pain.

Although detailed outcome studies analysis will await the submission to the FDA, it is the author's opinion that the artificial disc patients are doing quite well clinically. Initially, the outcome of the groups in the first months is considerably different. In the fusion patients, a bone graft is taken and the patients are within a brace for three months. With the SB Charité artificial lumbar disc, there is no bone graft taken, so there is no bone graft to heal no brace used. Walking and mobility happen quickly with both procedures. The abdominal incision usually heals and is only a

minor discomfort in 2 to 3 weeks. The LINK Charité artificial disc is a finished surgical technique, as it requires no bony healing or fusion to occur. When the patient gets to the recovery room, the surgical procedure is like putting a hinge on a door - the door is ready to use once the hinge is put on. In the patients with a stabilization and arthrodesis ALIF, however, the bone has to heal to a mature fusion, which can take 6 to 12 months. There is also potential for bony non-union.

In follow-up x-ray studies, the patients have mobility in both flexion/extension and lateral bending in the level that was dynamically stabilized

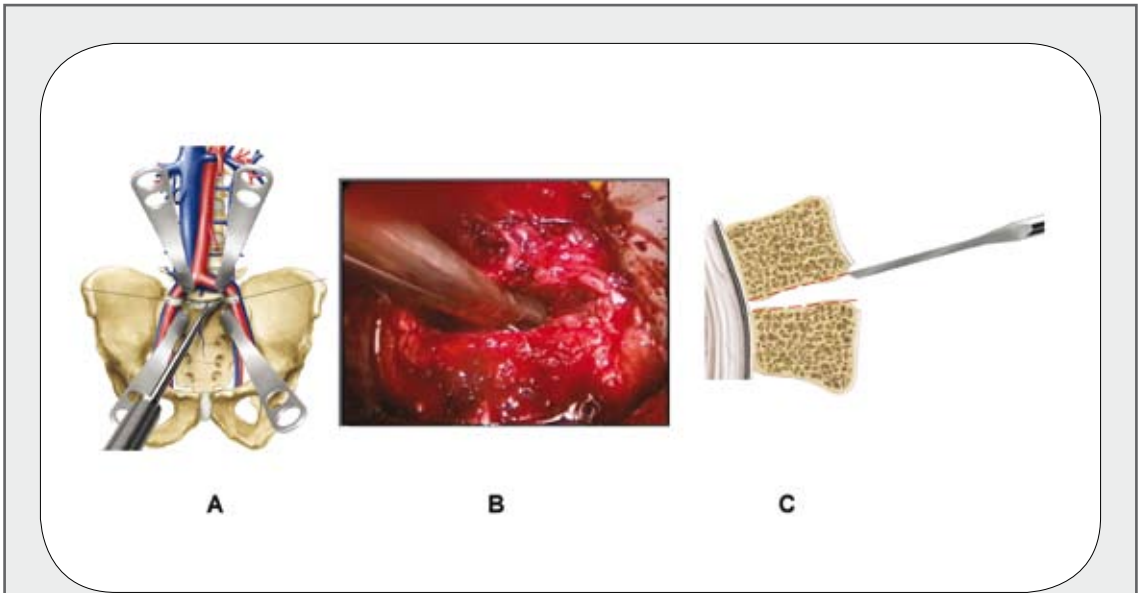


Figure 10:
Preparation of the disc space.

- A. Removal of the disc
- B. Video picture showing the removal of the disc
- C. Demonstrates a chisel flattening out the endplates as necessary.

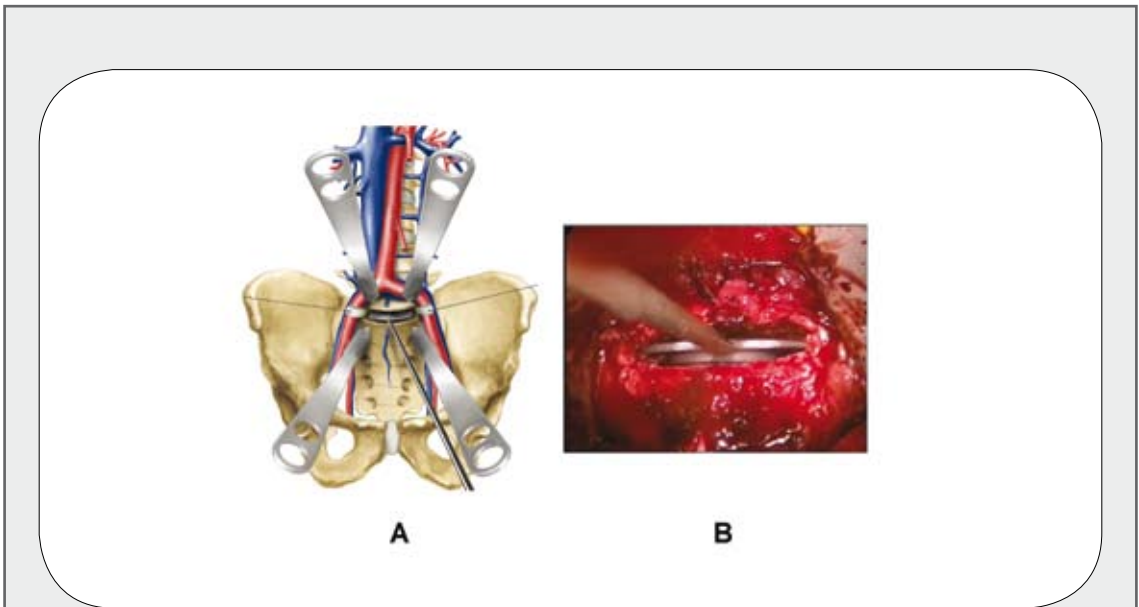


Figure 11:
A/B. Shows sizer going into the disc space, which determines the size of the footplate of the SB Charité to be used.

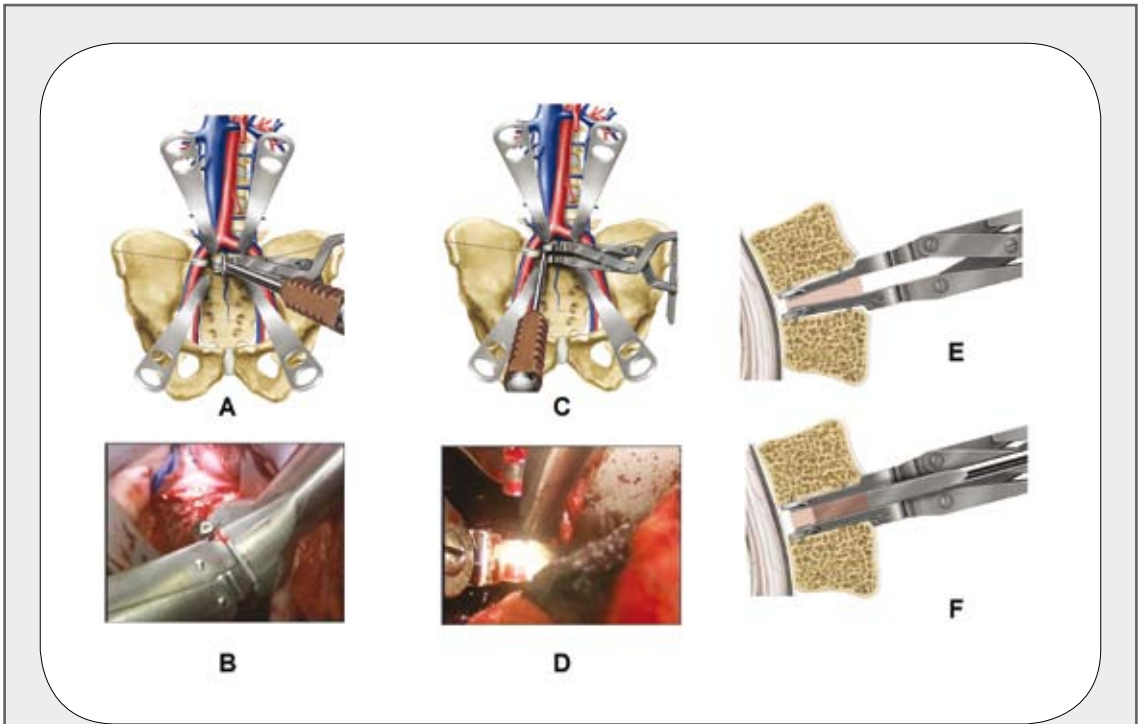


Figure 12:

This figure demonstrates the application of the distractor and the parallel distracting showing how a second unit is placed on in A&B to provide impact force for driving the metal endplates down to the desired posterior position. C&D show the paint-paddle-type instrument used for the parallel distraction. E/F show how the parallel distraction is obtained by first obtaining some distraction in E, inserting of the parallel paint paddle-type device and turning it at right angles to provide force at the posterior ligament to separate that and distract it out.

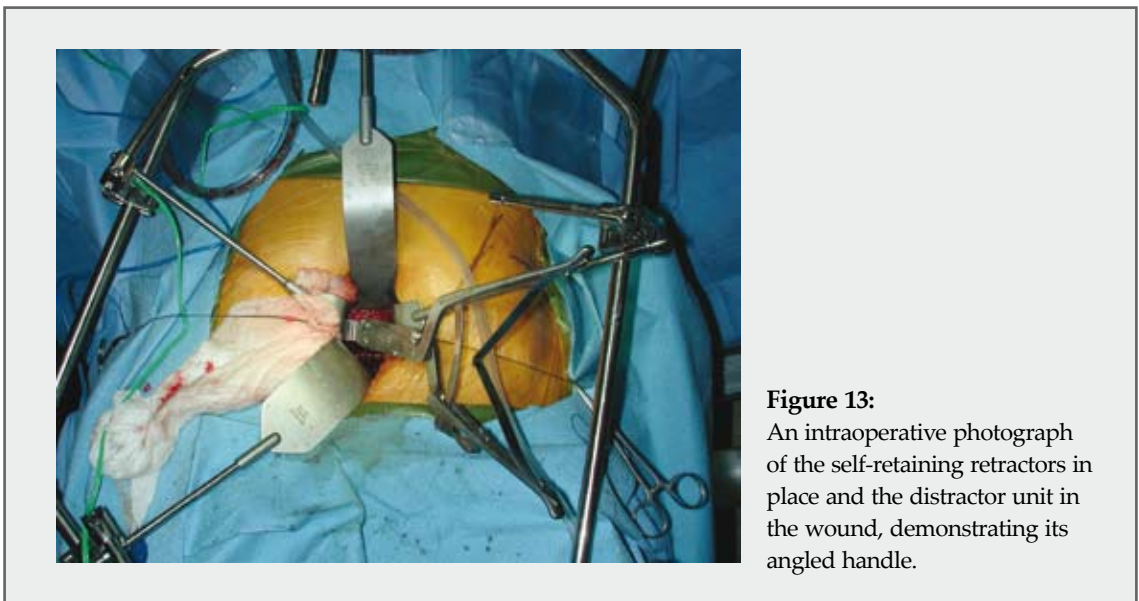


Figure 13:

An intraoperative photograph of the self-retaining retractors in place and the distractor unit in the wound, demonstrating its angled handle.



Figure 14:

A series off of intraoperative video showing the trial core in A. B shows the disc space is distracted with the metal cups clearly visible in the posterior longitudinal ligament. C shows the core being inserted. D shows the core in place with good position and the core and the cups being verified visually. E shows the final construct.

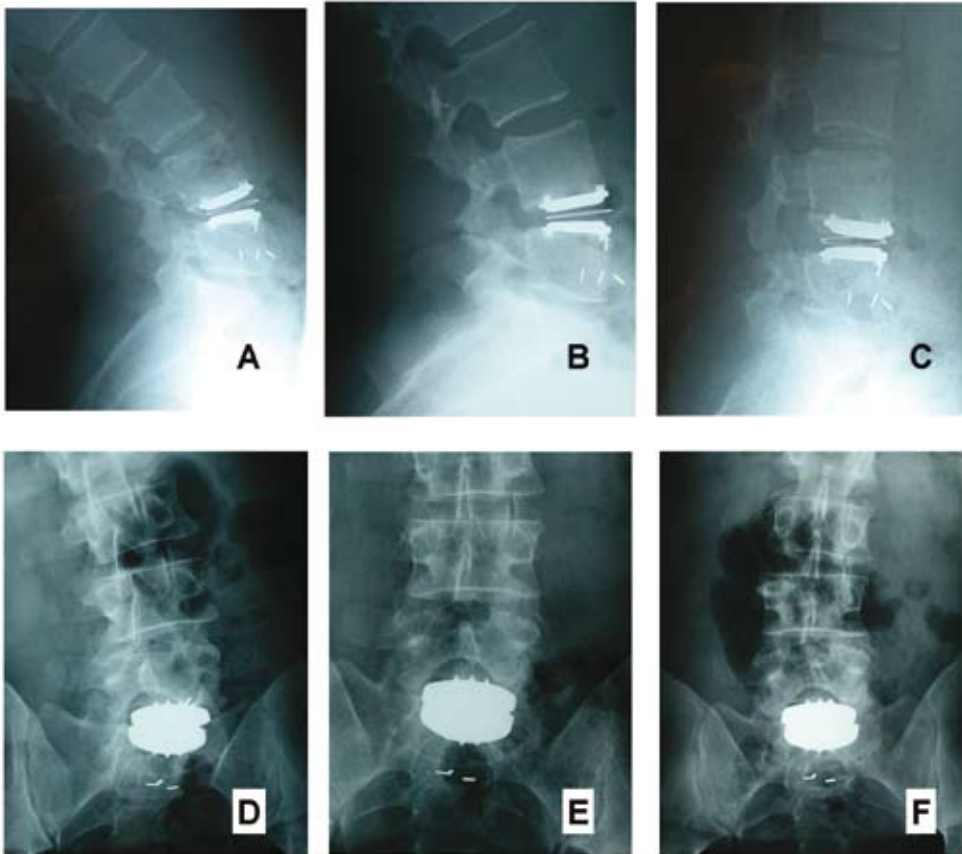


Figure 15:

A patient in flexion/extension and lateral bending showing clear motion of the device in both angulation and with translation of the core in both planes of motion.

(Figure 15). X-ray evidence shows clear movement of the core translation with the flexion/extension movement. The author's initial impression is that the clinical outcome results are comparable or better than historical fusion results reported in the literature.

4. Conclusion

Estimations as to when these devices will be available on the US market vary greatly. At the time of this chapter's writing, it is estimated that the SB Charité will be available by Spring/Summer 2004. The Prodisc may be delayed 1 to 3 years beyond that. Flexicore and Marerick are just starting their IDE trials and may be delayed 4 to 5 years. All other designs would be five years or more out.

In conclusion, lumbar dynamic stabilization with a SB Charité artificial lumbar disc dynamic stabilizer is a promising treatment modality for axial lumbar pain and preserving joint motion in selected patients. The two-year clinical outcome after a single level discogenic degenerative disc disease appears superior to historical fusion results. Additional research will be done in the coming years to see whether topping off a lumbar fusion will help prevent adjacent level disease and whether this device can be used below a scoliosis when the degenerative changes occur, and whether multilevel disease will have the same good clinical response as the single level appears to be having in this clinical study.

5. References

1. Arnold PM, Kirschman DL, Meredith C. Prosthetic Vertebral Disc Replacement. In AR V, RR B, SM Z eds. Principles and Practice of Spine Surgery. Philadelphia: Mosby, 2003:379-84.
2. Bao QB, McCullen GM, Higham PA, et al. The artificial disc: theory, design and materials. *Biomaterials* 1996;17:1157-67.
3. Cunningham BW, Godron JD, Dmitriev AE, et al. Biomechanical Evaluation of Total Disc Replacement Arthroplasty: An In Vitro Human Cadaveric Model. *Spine* 2003;28:S110-S7.
4. Dooris AP, Goel VK, Grosland NM, et al. Load-sharing between anterior and posterior elements in a lumbar motion segment implanted with an artificial disc. *Spine* 2001;26:E122-9.
5. Eijkelkamp MF, van Donkelaar CC, Veldhuizen AG, et al. Requirements for an artificial intervertebral disc. *Int J Artif Organs* 2001;24:311-21.
6. Freudiger S, Dubois G, Lorrain M. Dynamic neutralisation of the lumbar spine confirmed on a new lumbar spine simulator in vitro. *Arch Orthop Trauma Surg* 1999;119:127-32.
7. Hedman TP, Kostuik JP, Fernie GR, et al. Design of an intervertebral disc prosthesis. *Spine* 1991;16:S256-60.
8. Klara PM, Ray CD. Artificial nucleus replacement: clinical experience. *Spine* 2002;27:1374-7.
9. Korge A, Nydegger T, Polard JL, et al. A spiral implant as nucleus prosthesis in the lumbar spine. *Eur Spine J* 2002;11:S149-53.
10. Kotani Y, Abumi K, Shikinami Y, et al. Artificial intervertebral disc replacement using bioactive three-dimensional fabric: design, development, and preliminary animal study. *Spine* 2002;27:929-35; discussion 35-6.
11. Lee CK, Langrana NA, Parsons JR, et al. Development of a prosthetic intervertebral disc. *Spine* 1991;16:S253-5.
12. Link HD, Buttner-Janzen K. Link SB Charité artificial disc: history, design, and biomechanics. In DL K, JR J eds. *Spinal Restabilization Procedures*. Amsterdam: Elsevier Science BV, 2002:293-316.
13. McAfee PC. Artificial disc prosthesis: the Link SB Charité III. In DL K, JR J eds. *Spinal Restabilization Procedures*. Amsterdam: Elsevier Science BV, 2002:299-310.
14. Senegas J. Mechanical supplementation by non-rigid fixation in degenerative intervertebral lumbar segments: the Wallis system. *Eur Spine J* 2002;11:S164-9.
15. Stoll TM, Dubois G, Schwarzenbach O. The dynamic neutralization system for the spine: a multi-center study of a novel non-fusion system. *Eur Spine J* 2002;11:S170-8.
16. Urbaniak JR, Bright DS, Hopkins JE. Replacement of intervertebral discs in chimpanzees by silicone-dacron implants: a preliminary report. *J Biomed Mater Res* 1973;7:165-86.
17. Wilke HJ, Kavanagh S, Neller S, et al. [Effect of artificial disk nucleus implant on mobility and intervertebral disk height of an L4/5 segment after nucleotomy]. *Orthopade* 2002;31:434-40.
18. Wilke HJ, Kavanagh S, Neller S, et al. Effect of a prosthetic disc nucleus on the mobility and disc height of the L4-5 intervertebral disc postnucleotomy. *J Neurosurg* 2001;95:208-14.