

# Relationship of Mandibular Ramus Dimensions to Lower Third Molar Impaction

Talat Hasan Al-Gunaid<sup>1,2</sup> Abdul Kadir Bukhari<sup>3</sup> Sara M. El Khateeb<sup>4,5</sup> Masaki Yamaki<sup>6</sup>

<sup>1</sup> Department of Pediatric Dentistry and Orthodontics, College of Dentistry, Taibah University, KSA

<sup>2</sup> Department of Orthodontics and Pediatric Dentistry, Faculty of Dentistry, Ibb University, Yemen

<sup>3</sup> Department of Pediatric Dentistry and Orthodontics, College of Dentistry, Taibah University, KSA

<sup>4</sup> Department of Basic Dental Sciences, College of Dentistry, Princess Nourah Bint Abdulrahman University, KSA

<sup>5</sup> Department of Oral Medicine, Periodontology, Diagnosis and Radiology, Faculty of Dentistry, Ain Shams University, Cairo, Egypt

<sup>6</sup> Department of Oral Life Science, Division of Orthodontics, Graduate School of Medical and Dental Sciences, Niigata University, Japan

**Address for correspondence** Talat Hasan Al-Gunaid, DDS, PhD, Associate Professor and Coordinator, Department of Pediatric Dentistry and Orthodontics, College of Dentistry, Taibah University, KSA (e-mail: gunaid2000@hotmail.com).

Eur J Dent 2019;13:213–221

## Abstract

**Objectives** The aim of this study was to investigate the mandibular ramus features that could contribute to the etiology of mandibular third molar impaction.

**Materials and Methods** Two hundred and forty subjects were divided into two groups: impacted group: 115 subjects presented with an impacted mandibular third molar, and control group: 125 subjects with the normal mandibular third molar eruption. Digital panoramic radiographs were used, and four angular and twelve linear measurements were done. Comparisons between groups were done using Student's *t*-test. Pearson correlation and linear regression tests were used to assess the degree of relationship between retromolar space and mandibular measurements.

**Results** Control group showed significant greater measurements in most of the variables, whereas the impacted group showed significant larger gonial angle and larger inclination of lower posterior teeth than the control group. Significant correlations were found between retromolar space and coronoid height, ramal heights, ramus notch depths, the inclination of lower posterior teeth, and retromolar space/3M width ratio in both groups.

**Conclusion** The present study found that the configuration of the mandibular ramus appears to be discrete in many aspects in the erupted other than impacted lower third molars subjects, which might be a possible cause for the impaction.

## Keywords

- ▶ ramal dimensions
- ▶ lower third molar
- ▶ impaction

## Introduction

Third molars are the most frequently impacted tooth in the dental arch.<sup>1</sup> The influence of the third molars on the anterior teeth crowding and its stability after orthodontic treatment is controversial. However, no evidence to support or deny the fact that these teeth are the only or even the primary etiological factor in the post-treatment incisor crowding.<sup>2</sup>

The etiology of third molar impaction is unclear. However, it has been reported that it might be linked with the short distance from the distal surface of the second molar to the ramus,<sup>3-6</sup> the mandibular growth amount and direction,<sup>3,7-9</sup> the width and remodeling of the ramus, degree of the third molar maturation, and might be due to the inclination of posterior teeth and discrepancy between the dentition and the jaws.<sup>3</sup>

Panoramic radiographs are widely used in the profession of dentistry<sup>10,11</sup> as it gives quick, low-cost, small radiation dosages and provides a bilateral view of the mandible compared with other sophisticated diagnostic tools. It is also considered as one of the proper radiographic techniques that used to assess lower third molar space and mandibular linear and angular dimensions. The drawbacks include distortion and magnification errors.<sup>12</sup> Ongkosuwito et al<sup>13</sup> compared orthopantomogram (OPG) with lateral cephalogram using three mandibular length measurements. They concluded that measurements of mandibular lengths such as condy- lion (Co)–gonion (Go), gonion–menton, and condy- lion–menton on the lateral cephalogram are as useful as on an OPG. They insisted on that the choice of whether to use panoramic radiograph or lateral cephalogram depends on the clinician's personal experience and that both methods can be equally well applied.

Our hypothesis suggests no association between the lower third molar impaction and mandibular ramus measurements. Therefore, the aim of this study was directed to investigate the mandibular ramus features that could contribute to the etiology of mandibular third molar impaction and compare them with a control group of normal erupted lower third molars.

## Materials and Methods

The current study had been approved by the Research Ethics Committee, College of Dentistry, Taibah University. The material of this study comprised the records of 2,981 consecutive patients seeking dental treatment at the Faculty of Dentistry, Taibah University. The OPGs are routinely taken for all patients attending our college hospital and used for screening and pretreatment evaluation.

Out of 2,981 panoramic radiographs, only 240 OPG of male and female patients and their related data were selected from these records. The inclusion criteria were: all patients were 21 years old or older, good quality of OPG, complete normal mandibular dentition, complete root formation of lower third molars, no history of orthodontic treatment, and nonsyndromic patients.

The sample was divided into two groups according to the status of the mandibular third molars:

- Impacted group: It comprised of 115 subjects (68 males and 47 females). A mandibular third molar was considered impacted if it is either partially erupted or impacted and was not in functional occlusion.
- Control group: It comprised of 125 subjects (89 males and 36 females) with the normal mandibular third molar eruption.

The mean age of the total sample was  $27.2 \pm 6.7$  years (range: 21–54 years). The mean age of the impacted mandibular third molar group was  $23.5 \pm 3.2$  years and  $30.5 \pm 6.9$  years for the control group. Digital panoramic radiographs were taken using the panoramic–cephalometric machine (Kodak 8000 C Digital Panoramic and Cephalometric, the Netherland). Two experienced technicians took

all digital panoramic radiographs according to the standard instructions provided by the manufacturer. The magnification of the device was  $\times 1.15$ .

The radiographs were then imported to analysis software for tracing and measurements. Nineteen landmarks were defined on the radiographs (►Fig. 1, ►Table 1). Four angular and twelve linear measurements were done (►Figs. 2 and 3, ►Tables 2 and 3) using Image J 1.48a software (National Institutes of Health, Bethesda, United States). All measurements were done to the nearest two decimal points obtained from the software program.

To evaluate and correct the magnification errors and to set the scale of the software program to a known distance, two stainless steel wires (0.07 mm) one vertical, parallel to the long axis of the tooth, and one horizontal, parallel to the incisal edge, were bonded to the upper central incisors of the second author. Each length of wire was premeasured using a digital caliper. Additionally, we also measured the mesiodistal width of the second molar from a study model of the same person and then used as a known distance. One investigator did all tracings and measurements.

## Methodological Error

An error analysis of tracing and measurements were performed using 30 radiographs traced twice at the 1-month interval. The method error was calculated using intraclass correlation coefficient.

## Statistical Analysis

The normality test of Shapiro–Wilk was applied to the data. The data were found to be normally distributed. Mean and standard deviation for the two samples and comparisons between control and impacted groups were done using Student's *t*-test. Pearson correlation and linear regression tests were used to assess the degree of relationship between retromolar space and mandibular measurements. All statistical analyses were performed using SPSS 17.0 software (version 17.0, SPSS, Chicago, Illinois, United States). Our level of significance was set at  $p < 0.05$ .

## Results

The method error was minimal, and the results demonstrated that the reliability for all measurements was excellent and was found to be between 0.89 and 0.99 (►Table 4).

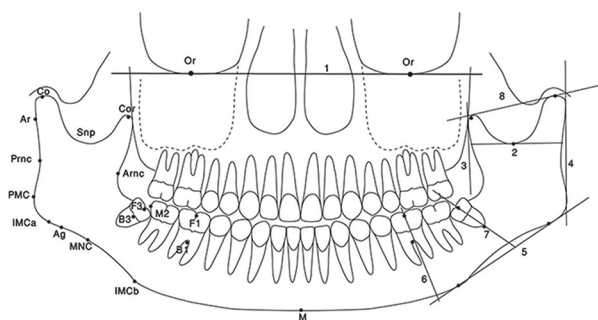


Fig. 1 Landmark and Reference planes

**Table 1** Landmarks and reference planes

Landmarks	Description
Orbitale (Or)	The lowermost point of the bony orbit
Condylion (Co)	Most superior point of the head of the mandibular condyle
Coronoid point (Cor)	Most superior point of the coronoid process
Sigmoid notch point (Snp)	The deepest point of the sigmoid notch of the mandible
Articulare (Ar)	A constructed point at the intersection between the external contour of the cranial base and the dorsal contour of the condylar head or neck
PMC	The point of greatest convexity on the posterior border of the angular process of the mandible (PMC)
Posterior ramus notch (Prnc)	The deepest point of the posterior ramus notch concavity
Anterior ramus notch (Arnc)	The deepest point of the anterior ramus notch concavity
Gonion (Go)	The constructed point of intersection of the ramus plane and the mandibular Plane
IMCa	Posterior point of greatest convexity on the inferior border of the mandible
IMCb	Anterior points of greatest convexity on the inferior border of the mandible
MNC	The deepest point of the mandibular inferior border notch concavity.
Antegonion point (Ag)	The point in the antegonial notch of the mandible joins the ramus and body of the mandible
Mandibular midpoint (M)	The most inferior midline point on the mandibular symphysis located by projecting the mental spine on the lower mandibular border
F1	The midpoint of the occlusal surface corresponding to fossa of the first molar
B1	The point corresponding to the bifurcation of the first molar
F3	The midpoint of the occlusal surface corresponding to fossa of the third molar
B3	The point corresponding to the bifurcation of the third molar
M2	The distal contact point of lower second molar
1. Orbitale plane	The line connecting the orbitale (Or) points bilaterally
2. Sigmoid notch plane	A tangential line is drawn from the deepest point on the sigmoid notch (Snp) parallel to the orbital plane
3. Z–plane	A line tangent to descending anterior border of the ramus of mandible and perpendicular to the sigmoid notch plane
4. Ramus plane	A tangential line of the posterior ramus connecting point Ar with the point of greatest convexity on the posterior border of the angular process of the mandible (PMC)
5. Mandibular plane	A tangential line of the lower border of the mandibular body [a tangent through the two points of greatest convexity on the inferior border of the mandible (IMCa and IMCb)].
6. Long axis of the first molar	A line is drawn through the midpoint of the occlusal surface and the midpoint of the bifurcation
7. Long axis of the third molar	A line is drawn through the midpoint of the occlusal surface and the midpoint of the bifurcation
8. Condyle coronoid plane	A-line connecting condylion (Co) and coronoid (Cor) points

**Table 5** compares the means and standard deviations of the mandibular dimensions between control and impacted groups. Control group showed significant larger measurements in most of the variables presented by longer condylar length ( $p < 0.001$ ), longer coronoid process length ( $p < 0.05$ ), longer ramus height (measured from sigmoid notch point, Snp–antegonion point, Ag) ( $p < 0.001$ ), longer total ramus height (measured from Co–Go) ( $p < 0.001$ ), wider ramal width ( $p < 0.001$ ), deeper sigmoid notch depth ( $p < 0.001$ ), deeper posterior and anterior notch depths ( $p < 0.001$ ), larger retromolar space ( $p < 0.001$ ), higher retromolar area to third molar

ratio ( $p < 0.001$ ), and larger angle of impaction ( $p < 0.001$ ) than impacted group. On the contrary, the impacted group showed only two significant larger measurements than control group presented by a larger gonial angle ( $p < 0.01$ ), and larger inclination of lower posterior teeth ( $p < 0.05$ ) than the control group.

**Table 6** shows the correlations coefficient between retromolar space and mandibular dimensions in both control and impacted groups. Significant correlations were found between coronoid height, ramal height, and total ramal height with retromolar space in both groups ( $p < 0.001$ ).

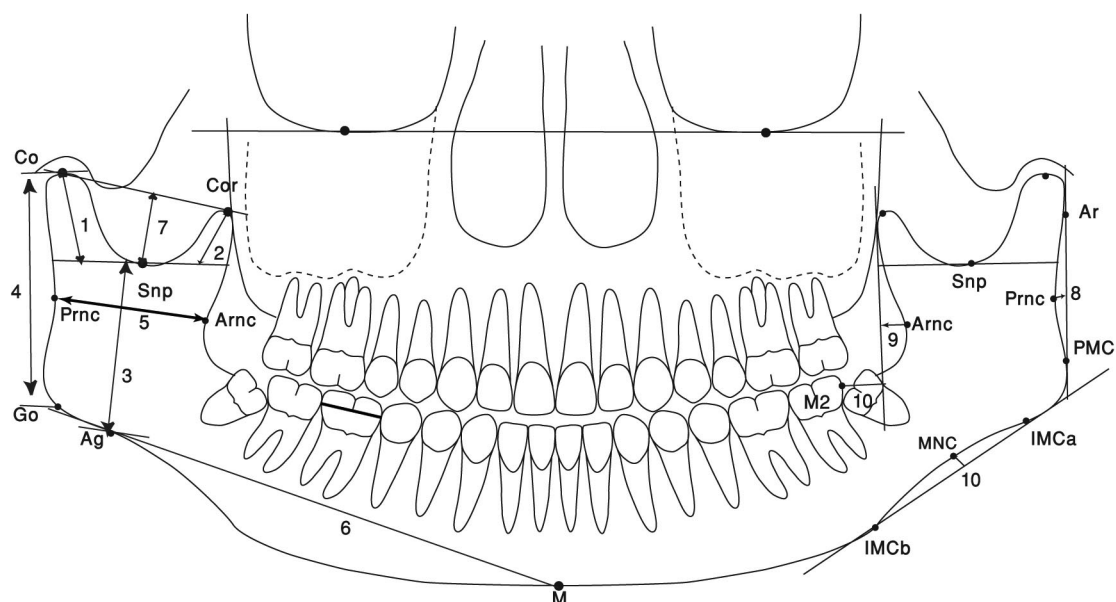


Fig. 2 Linear Measurements

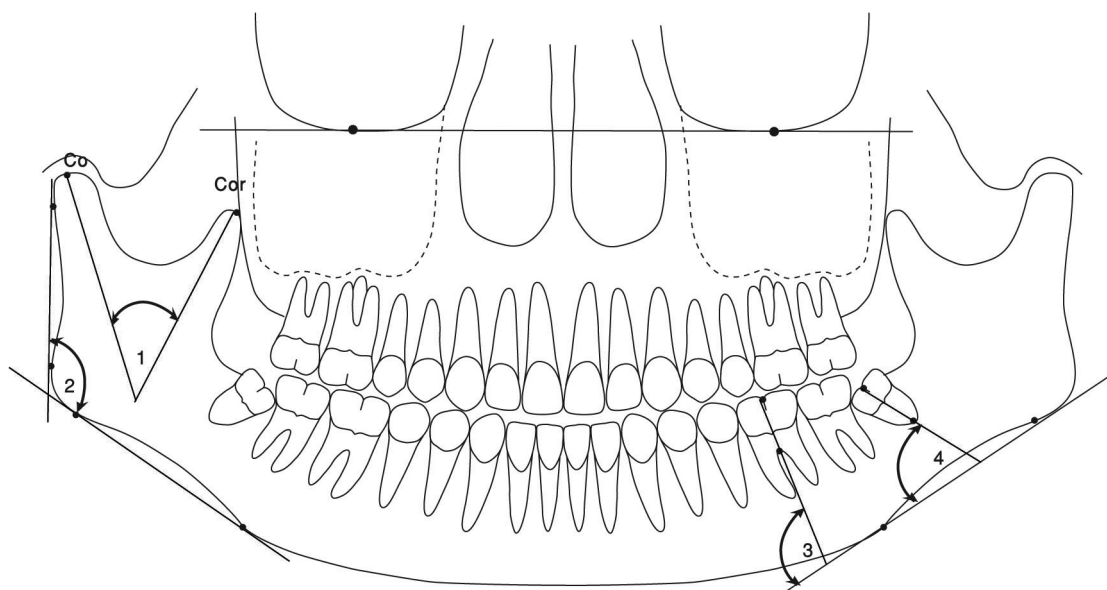


Fig. 3 Angular Measurements

Ramal width showed a significant correlation with retromolar space only in the impacted group ( $p < 0.05$ ). Also, posterior ramus notch depth, anterior ramus notch depth, the inclination of lower posterior teeth, and retromolar space/3M width ratio showed a significant correlation with retromolar space in both groups ( $p < 0.001$ ). Furthermore, gonial angle and angle of impaction showed significant association with retromolar space only in the control group ( $p < 0.001$ ).

## Discussion

The mean age of the total sample was  $27.2 \pm 6.7$  years, which is close to the average age reported for the eruption of a

mandibular third molar.<sup>14-16</sup> Scherstén et al<sup>17</sup> suggested that 20 to 25 years is the most appropriate age for studying the incidence of mandibular third molar impaction. For this reason and in an attempt to minimize the influence of such factors on the measurements, the subjects included in this study were 21 years old or older, as this age essentially completes growth and all third molars have their roots completed by this time.

About the ramal dimensions, condylar length, coronoid length, ramus height, and total ramus height were significantly longer in the normal group than the impacted group. This finding disagrees with the result of Capelli,<sup>18</sup> who reported that long ascending ramus seems to be indicative of third molar impaction. Also, our result is not in line with that of

**Table 2** Linear measurements

Measurement	Abbreviation	Description
1. Condyle length	Co-Snp (mm)	Measured from condylion to sigmoid notch plane along the long axis of the condylar process
2. Coronoid length	Cor-Snp (mm)	Measured from coronoid point to sigmoid notch plane along the long axis of the coronoid process
3. Ramus height	Snp-Ag (mm)	The distance between sigmoid notch point to antegonion point (excluding condyle and coronoid)
4. Total ramus height	Co-Go (mm)	The distance between condylion to gonion
5. Ramus width	Prnc-Arnc (mm)	The distance from anterior to posterior ramal walls at the level of the midpoint
6. Mandibular body length	Go-M (mm)	Measured from gonion point to mandibular midpoint
7. Sigmoid notch depth	(mm)	The distance along a perpendicular line from the deepest point of the sigmoid notch to a line extending from condylion and coronoid process
8. Posterior ramus notch depth	(mm)	The distance along a perpendicular line from the deepest point of the ramus notch concavity (Prnc) to a line connecting point Ar with the point of greatest convexity on the posterior border of the angular process of the mandible (PMC)
9. Anterior ramus notch depth	(mm)	The distance along a perpendicular line from the deepest point of the anterior ramus notch concavity (Arnc) to Z-line (a line perpendicular to sigmoid notch plane and tangent to descending anterior border of the ramus of mandible)
10. Antegonial notch depth	(mm)	The distance along a perpendicular line from the deepest point of the mandibular inferior border notch concavity (MNC) to mandibular plane
11. Retromolar space	M2-Z (mm)	The distance between the distal contact point of the second molar and a line perpendicular to Z plane.
12. Third Molar Width	(mm)	The mesiodistal tooth width
Retromolar space/3M width	Ratio	Retromolar space divided by the Third molar width

**Table 3** Angular measurements

Measurement	Abbreviation	Description
1. Angle between condyle and Coronoid process	Co-Cor °	Formed by the intersection between the two lines drawn from Co and Cor along their long axis
2. Gonial angle	Ar and PMC-IMCa and IMCb °	The angle formed by drawing two lines: the ramus plane (Ar and PMC) and the mandibular plane (IMCa and IMCb)
3. Inclination of lower posterior teeth	L6-MP °	The angle formed between the long axis of the first molar (drawn through the midpoint of the occlusal surface and the midpoint of the bifurcation) and the mandibular plane
4. Angle of Impaction	L8-MP °	The angle formed between the long axis of the third molar (drawn through the midpoint of the occlusal surface and the midpoint of the bifurcation) and the mandibular plane

Hasan,<sup>19</sup> who failed to find any significant difference between normal and impacted groups.

In this study, the control group showed significant wider ramal width than the impacted group ( $p < 0.001$ ). This result is not in line with the results obtained by Hassan,<sup>19</sup> who found significant wider ramal width in the impaction group. This difference may be a result of the different measurement technique used, sampling differences.

The results of the present study showed that the sigmoid notch depth was significantly deeper in the control

group than in the impacted group ( $p < 0.001$ ). This might be explained with reference to the following factors that may influence the sigmoid notch depth: ramus heights, condylar and coronoid process heights, and the angle between the condyle and coronoid processes, in which the control group showed significant longer ramus heights and significantly smaller angle between condyle and coronoid process than impacted group (this means less backward and forward slope of the anterior and posterior borders of the ramus in the control group). This hints that sigmoid notch depth is

**Table 4** Methodological tracing errors

Variable	Reliability	Lower bond	Upper bond	p-Value
Condyle length (mm)	0.99***	0.98	0.99	0.000
Coronoid length (mm)	0.99***	0.98	0.99	0.000
Ramus height (mm)	0.91***	0.82	0.95	0.000
Total ramus height (mm)	0.89***	0.78	0.94	0.000
Ramal width (mm)	0.94***	0.89	0.97	0.000
Mandibular body length (mm)	0.95***	0.91	0.97	0.000
Sigmoid notch depth (mm)	0.97***	0.95	0.98	0.000
Posterior ramus notch depth (mm)	0.99***	0.99	0.99	0.000
Anterior ramus notch depth (mm)	0.99***	0.99	0.99	0.000
Antegonial notch depth (mm)	0.99***	0.99	0.99	0.000
Third molar width (mm)	0.99***	0.99	0.99	0.000
Retromolar space (mm)	0.98***	0.97	0.99	0.000
Angle between condyle and coronoid process (deg)	0.98***	0.97	0.99	0.000
Gonial angle (deg)	0.92***	0.84	0.96	0.000
Inclination of lower posterior teeth (deg)	0.96***	0.93	0.98	0.000
Angle of Impaction (deg)	0.99***	0.98	0.99	0.000

\*\*\* $p < 0.001$ .

**Table 5** Means and standard deviations of the mandibular dimensions between control and impacted groups

Variable	Control group (n = 125)		Impacted group (n = 115)		p-Value
	Mean	SD	Mean	SD	
Condyle length (mm)	17.51	3.28	16.18	3.04	0.0000
Coronoid length (mm)	13.16	3.20	12.50	3.06	0.03
Ramus height (mm)	46.22	6.34	44.32	5.62	0.001
Total ramus height (mm)	58.20	6.88	54.47	6.44	0.000
Ramal width (mm)	29.04	3.97	27.81	3.11	0.000
Mandibular body length (mm)	88.52	9.35	87.54	7.56	0.23
Sigmoid notch depth (mm)	13.87	2.46	12.93	2.18	0.000
Posterior ramus notch depth (mm)	2.88	0.97	2.52	0.80	0.000
Anterior ramus notch depth (mm)	3.40	2.06	2.78	1.57	0.001
Antegonial notch depth (mm)	1.87	1.02	1.81	0.91	0.47
Third molar width (mm)	11.04	0.93	10.93	0.96	0.23
Retromolar space (mm)	10.72	3.61	8.21	3.48	0.000
Retromolar space/3M width ratio	0.97	0.34	0.75	0.32	0.000
Angle between condyle and coronoid process (deg)	39.68	8.74	41.21	9.35	0.07
Gonial angle (deg)	122.81	10.68	125.47	8.24	0.004
Inclination of lower posterior teeth (deg)	81.25	10.76	83.74	11.99	0.02
Angle of Impaction (deg)	72.07	13.64	39.13	22.73	0.000

Note: n = number of subjects.

more likely to be more in-depth in the control group; however, the present findings stand alone, and further investigations are required before such conclusions are drawn.

According to the results of this study, the posterior and anterior ramus notch depths were significantly shallower in the impacted group than in the normal group ( $p < 0.001$ ).

This finding might be due to the failure of remodeling and resorption of the anterior and posterior surfaces of the ramus, and more backward and forward slopes of the anterior and posterior borders of the ramus presented by the significant smaller angle between the condyle and coronoid process in the impacted group.



**Table 6** Correlation between retromolar space and mandibular measurements

Variable	Control group				Impacted group			
	Retromolar space				Retromolar space			
	<i>r</i>	<i>R</i> <sup>2</sup>	<i>R</i> <sup>2 (ADJ)</sup>	<i>p</i> -Value	<i>r</i>	<i>R</i> <sup>2</sup>	<i>R</i> <sup>2 (ADJ)</sup>	<i>p</i> -Value
Condyle length	0.08	0.006	0.002	0.231	0.07	0.005	0.001	0.260
Coronoid length	0.17	0.03	0.03	0.007	0.17	0.029	0.025	0.007
Ramal height I	0.17	0.03	0.02	0.008	0.36	0.126	0.123	0.000
Ramal height II	0.18	0.03	0.03	0.005	0.34	0.115	0.111	0.000
Ramal width	0.04	0.00	-0.003	0.567	0.15	0.022	0.018	0.020
Corpus length	0.09	0.01	0.00	0.164	0.11	0.013	0.009	0.070
Sigmoid notch depth	0.06	0.00	0.00	0.377	0.10	0.011	0.007	0.103
Posterior ramus notch depth	0.30	0.09	0.09	0.000	0.18	0.033	0.03	0.004
Anterior ramus notch depth	0.45	0.20	0.20	0.000	0.37	0.134	0.131	0.000
Antegonial notch depth	0.00	0.00	0.00	0.979	0.05	0.002	-0.002	0.468
Third molar width	0.12	0.01	0.01	0.066	0.07	0.005	0.001	0.254
Gonial angle	0.18	0.03	0.03	0.004	0.07	0.005	0.001	0.249
Angle between condyle and coronoid process	0.01	0.00	0.00	0.862	0.07	0.005	0.001	0.277
Inclination of lower posterior teeth	0.28	0.08	0.08	0.000	0.23	0.054	0.05	0.000
Angle of Impaction	0.35	0.12	0.12	0.000	0.05	0.002	-0.002	0.435
Retromolar space/3M width ratio	0.96	0.927	0.927	0.000	0.97	0.945	0.945	0.000

Note: *r* = Pearson correlation coefficient; *R*<sup>2</sup> = squared multiple correlation coefficient; *R*<sup>2 (ADJ)</sup> = adjusted coefficient of determination, *p* < 0.05.

When comparing mandibular body length (Go–mandibular midpoint, M) between groups, no statistically significant difference was found. This is consistent with previous studies of Dierkes<sup>20</sup> and Kaplan<sup>21</sup> but disagrees with the findings of Hassan,<sup>19</sup> Broadbent,<sup>8</sup> Björk,<sup>9</sup> and Capelli<sup>18</sup> who reported significant smaller mandibular length in the impacted third molars subjects.

The results of the present study showed that the mean retromolar space measured from a line tangent to descending anterior border of ramus to the distal surface of the second molar (M2–Z) was found to be 10.7 ± 3.6 mm in the control group, and 8.2 ± 3.4 mm in the impacted group. The retromolar space was significantly larger in the erupted group than in the impacted group (*p* < 0.001).

Uthman<sup>22</sup> measured the retromolar space on panoramic radiographs, and concluded that this distance should be higher than 11 mm for females and 12 mm for males; this is within the range of the present investigation for men in the control group.

Our mean value of both groups (10.7 ± 3.6 mm for control group and 8.2 ± 3.4 mm for impacted group) was less than that reported by Hattab and Alhajja<sup>16</sup> for Jordanians (14.4 ± 2.4 mm for erupted group and 11.06 ± 2.6 mm for impacted group) and Qamruddin et al<sup>23</sup> for Pakistanians (16.3 ± 2.5 mm for normal group and 11.2 ± 3.6 for impacted group).

On the other hand, Behbehani et al<sup>3</sup> using lateral cephalograms suggested that the eruption space could be a good predictor for third molar eruption when measured

to Ricketts' Xi point rather than to the anterior border of the ramus. They believed that it might be due to the large method error, and the complexity of locating the anterior border of the ramus on the lateral cephalograms, especially with double contours of the right and left sides in projection. In the present study, the eruption space was measured from the distal surface of the second molar to the anterior border of the ramus (M2–Z). Our finding is in line with the previous report that panoramic radiographs can offer better measurement due to the simplicity of locating the anterior border of the ramus and absence of double counters between the right and left sides and less method error.<sup>24</sup>

The average space/crown width ratio was 0.97 for the control group and 0.75 for the impacted group. This result is close to the value obtained by Hattab and Alhajja<sup>16</sup> for Jordanian subjects, and that might be due to the similarity of the inclusion criteria and ethnic background. Previous reports<sup>16,25</sup> indicated that when the ratio of retromolar space to third molar crown width is at least 1, 69% of third molars erupt, a finding inconsistent with our present study.

Based on the results of the present study, there was a significant difference between groups about the gonial angle in which the control group showed smaller gonial angle than the impacted group. Our finding is in agreement with the results of previous studies.<sup>15,16</sup>

Some studies reported smaller and acuter gonial angle among impacted group compared with the normal group,<sup>25,26</sup> which has not been detected in our sample in which the control group showed smaller gonial angle than the impacted

group. Our finding disagrees with the results obtained by Behbehani et al<sup>3</sup> who reported that small mandibular plane and gonial angles are associated with an increased risk for mandibular impaction.

Regarding the angulations of lower posterior teeth, the mandibular first molar inclinations were found to be in a more upright position in the impacted group compared with the control group ( $p < 0.05$ ), resulting in less retromolar space that might lead to insufficient space required for the eruption of third molars in the impacted group. On the contrary, the third molar was more inclined in the impacted group than in the normal group ( $p < 0.001$ ). It has been demonstrated that the higher the inclination of the posterior teeth, the greater is the probability of impaction.<sup>15,27,28,29,30</sup> Our results support the findings of Ricketts,<sup>5</sup> Capelli,<sup>18</sup> Hassan,<sup>19</sup> Shiller,<sup>28</sup> Richardson,<sup>31</sup> and Begg<sup>32</sup> in that the initial angulation of the lower third molar to the mandibular plane can be a factor in predicting impaction. Additionally, Uthman<sup>22</sup> concluded that the third molar angle should be greater than 40° as the angle decreases, the chances for impaction increases, which supports the results of the present study.

This study showed a significant but weak correlation between coronoid height, ramal height, and total ramal height with retromolar space required for the eruption of the third molar. These parameters could be a relevant indicator for predicting the eruption or impaction of third molars. The same tendency could be applied to the posterior ramus notch depth, anterior ramus notch depth, the inclination of lower posterior teeth, and retromolar space/3M width ratio, which showed a significant correlation with retromolar space.

The present study showed no correlation between the size of the gonial angle and the impaction of the third molars. It has been reported that a smaller and acuter gonial angle was more common among members of the impacted group,<sup>25,26</sup> a tendency that has not been detected in our sample. Our finding is in agreement with the results of previous studies of Hattab and Alhaija,<sup>16</sup> Hassan,<sup>19</sup> Mollaoglu et al<sup>27</sup> and disagrees with that of Behbehani et al.<sup>3</sup> who reported that small mandibular plane and gonial angles are associated with an increased risk for mandibular impaction.

In spite of the limitation of this study of using two-dimensional radiographs, some obvious variations between groups included in this study are possibly helpful during prediction and treatment planning. However, further research using a contemporary approach such as cone beam computed tomography to elucidate the difference between groups is recommended.

## Conclusion

The present study found that the configuration of the mandibular ramus appears to be discrete in many aspects in the erupted other than impacted lower third molar subjects, which might be a possible cause for the impaction.

### Conflict of Interest

None declared.

## References

- Andreasen JO, In: epidemiology of third molar impaction. Andreasen, JO, Peterson, JK, Laskin, DM, eds. Textbook and Color Atlas of Tooth Impactions. Copenhagen: Munksgaard;1997;222-223
- Bishara SE. Third molars: a dilemma! Or is it? Am J Orthod Dentofacial Orthop 1999;115(6):628-633
- Behbehani F, Artun J, Thalib L. Prediction of mandibular third-molar impaction in adolescent orthodontic patients. Am J Orthod Dentofacial Orthop 2006;130(1):47-55
- Bjork A, Jensen E, Palling M. Mandibular growth and third molar impaction. Acta Odontol Scand 1956;14:231-272
- Ricketts RM. A principle of arcial growth of the mandible. Angle Orthod 1972;42(4):368-386
- Schulhof RJ. Third molars and orthodontic diagnosis. J Clin Orthod 1976;10(4):272-281
- Forsberg CM, Vingren B, Wesslén U. Mandibular third molar eruption in relation to available space as assessed on lateral cephalograms. Swed Dent J 1989;13(1-2):23-31
- Broadbent B. The influence of the third molars on the alignment of teeth. Am J Orthod 1943;29:312-330
- Bjork A. Variations in the growth pattern of the human mandible: longitudinal radiographic study by the implant method. J Dent Res 1963;42(1):400-411
- Alrahabi M, Zafar M. Anatomical variations of mental foramen: a retrospective cross-sectional study. Int J Morphol 2018;36(3):1124-1129
- Al-Zoubi H, Alharbi AA, Ferguson DJ, Zafar MS. Frequency of impacted teeth and categorization of impacted canines: a retrospective radiographic study using orthopantomograms. Eur J Dent 2017;11(1):117-121
- Gupta S, Jain S. Orthopantomographic analysis for assessment of mandibular asymmetry. J Indian Orthod Soc 2012;46:33-37
- Ongkosuwito EM, Dieleman MM, Kuijpers-Jagtman AM, Mulder PG, van Neck JW. Linear mandibular measurements: comparison between orthopantomograms and lateral cephalograms. Cleft Palate Craniofac J 2009;46(2):147-153
- Haralabakis H. Observations on the time of eruption, congenital absence and impaction of the third molar teeth. Trans Eur Orthod Soc 1957;33:308-309
- Hattab FN. Positional changes and eruption of impacted mandibular third molars in young adults. A radiographic 4-year follow-up study. Oral Surg Oral Med Oral Pathol Oral Radiol Endod 1997;84(6):604-608
- Hattab FN, Alhaija ES. Radiographic evaluation of mandibular third molar eruption space. Oral Surg Oral Med Oral Pathol Oral Radiol Endod 1999;88(3):285-291
- Scherstén E, Lysell L, Rohlin M. Prevalence of impacted third molars in dental students. Swed Dent J 1989;13(1-2):7-13
- Capelli J, Jr. Mandibular growth and third molar impaction in extraction cases. Angle Orthod 1991;61(3):223-229
- Hassan AH. Mandibular cephalometric characteristics of a Saudi sample of patients having impacted third molars. Saudi Dent J 2011;23(2):73-80
- Dierkes DD. An investigation of the mandibular third molars in orthodontic cases. Angle Orthod 1975;45(3):207-212
- Kaplan RG. Some factors related to mandibular third molar impaction. Angle Orthod 1975;45(3):153-158
- Uthman AT. Retromolar space analysis in relation to selected linear and angular measurements for an Iraqi sample. Oral Surg Oral Med Oral Pathol Oral Radiol Endod 2007;104(4):e76-e82
- Qamruddin I, Qayyum W, Haider SM, Siddiqui SW, Rehan F. Differences in various measurements on panoramic radiograph among erupted and impacted lower third molar groups. J Pak Med Assoc 2012;62(9):883-887



- 24 Indira AP, Markande A, David MP. Mandibular ramus: an indicator for sex determination - a digital radiographic study. *J Forensic Dent Sci* 2012;4(2):58-62
- 25 Ganss C, Hochban W, Kielbassa AM, Umstadt HE. Prognosis of third molar eruption. *Oral Surg Oral Med Oral Pathol* 1993;76(6):688-693
- 26 Richardson ME. The etiology and prediction of mandibular third molar impaction. *Angle Orthod* 1977;47(3):165-172
- 27 Mollaoglu N, Çetiner S, Güngör K. Patterns of third molar impaction in a group of volunteers in Turkey. *Clin Oral Investig* 2002;6(2):109-113
- 28 Shiller WR. Positional changes in mesio-angular impacted mandibular third molars during a year. *J Am Dent Assoc* 1979;99(3):460-464
- 29 Garcia RI, Chauncey HH. The eruption of third molars in adults: a 10-year longitudinal study. *Oral Surg Oral Med Oral Pathol* 1989;68(1):9-13
- 30 Ventä I, Murtomaa H, Turtola L, Meurman J, Ylipaavalniemi P. Clinical follow-up study of third molar eruption from ages 20 to 26 years. *Oral Surg Oral Med Oral Pathol* 1991;72(2):150-153
- 31 Richardson M. Changes in lower third molar position in the young adult. *Am J Orthod Dentofacial Orthop* 1992;102(4):320-327
- 32 Begg PR. Stone Age man's dentition. *Am J Orthod* 1954;40:298-312