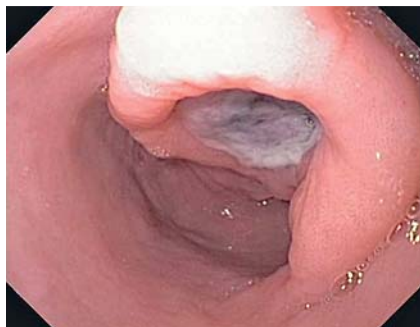

## Endoscopic ultrasound-guided angiotherapy of a large bleeding gastrointestinal stromal tumor

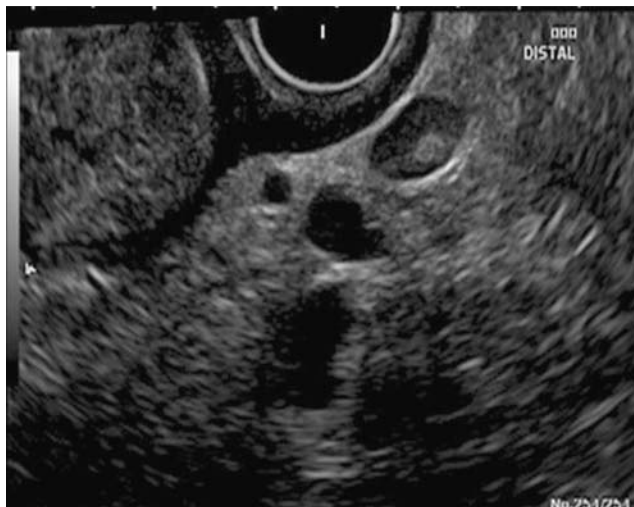

**Fig. 1** Large subepithelial lesion at the incisura with a deep clean-based ulcer.

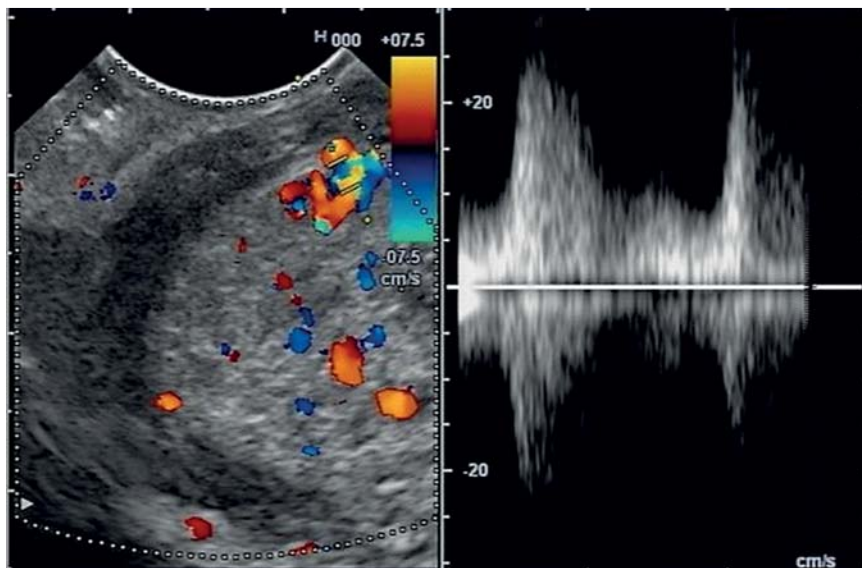
Bleeding gastrointestinal stromal tumors (GISTs) have historically been managed with either surgical resection or radiologic embolization. Occasional reports exist of endoscopic therapies such as hemoclips [1], endoloop ligation [2], and endoscopic ultrasound (EUS)-guided angiotherapy [3]. We herein present the case of an elderly patient with recurrent bleeding from a large gastric GIST who was successfully treated with EUS-guided angiotherapy.

A 94-year-old man with severe aortic stenosis presented with symptomatic anemia and hemoglobin of 5.9 g/dL. Esophagogastroduodenoscopy (EGD) identified a large subepithelial lesion at the incisura with a depressed 15-mm central ulcer (● **Fig. 1**). EUS revealed a 40×45-mm hypoechoic well-circumscribed lesion with areas of cystic degeneration arising from the muscularis propria. A corresponding 7-mm hypoechoic malignant-appearing lymph node was identified (● **Fig. 2**). Fine needle aspiration (FNA) confirmed a diagnosis of GIST. Although surgical resection was indicated, the patient's age and multiple comorbidities precluded this.

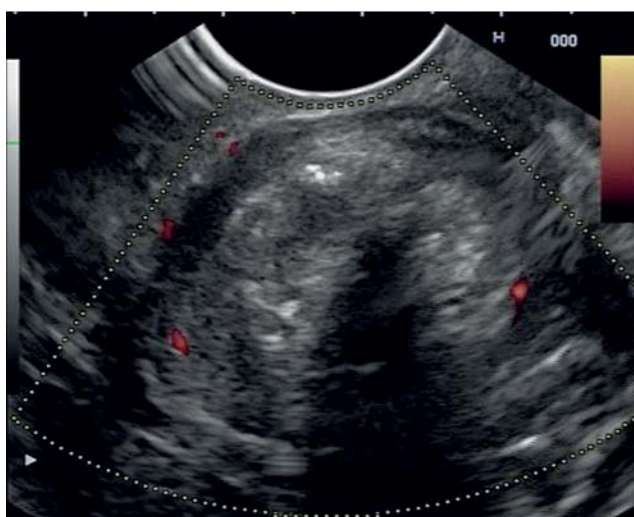
EUS-guided angiotherapy was considered a suitable option. A curved linear-array echoendoscope (Olympus GF-UC(T)140P-OL5; Olympus America Inc., Center Valley, Pennsylvania, USA) was used, and a vessel deep to the GIST ulcer was identified. Pulse wave Doppler confirmed arterial flow (● **Fig. 3**; ● **Video 1**). After the patient had been given an intravenous injection of cefotetan 2 g, a 19-gauge needle (Flex 19; Boston Scientific, Natick, Massachusetts, USA) was used to puncture the target artery and 2 mL of N-butyl 2-cyanoacrylate (Histoacryl; B. Braun Medical,



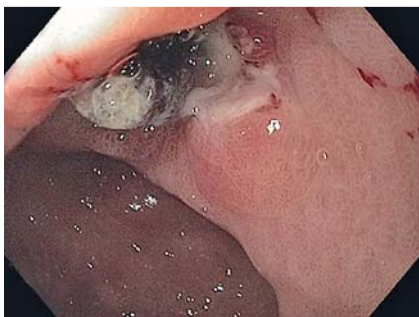**Fig. 2** Endoscopic ultrasound image showing the typical appearance of a gastrointestinal stromal tumor (GIST) with an associated malignant-appearing lymph node.



**Fig. 3** Pulse wave Doppler demonstrating arterial waveforms from the artery that was feeding the tumor.



**Fig. 4** Doppler image after cyanoacrylate injection showing an absence of vascularity and a posterior acoustic shadow.



**Fig. 5** Endoscopic view 4 weeks after angiotherapy showing the ulcer, which had reduced in size from 15 mm to 7 mm, along with a small volume of extravasated cyanoacrylate.

Bethlehem, Pennsylvania, USA) was injected followed by an immediate flush of 2 mL of 5% dextrose.

Cyanoacrylate deposition was seen within the lesion as an area of increased echogenicity with posterior acoustic shadowing. Power Doppler confirmed a near absence of vascularity within the GIST (▶ Fig. 4). Repeat EGD/EUS after 4 weeks revealed a substantial reduction in the size of the lesion and the central ulcer. There was a small amount of cyanoacrylate seen protruding through the ulcer bed (◉ Fig. 5). At 6-month follow-up,

#### Video 1

Endoscopic ultrasound (EUS)-guided angiotherapy of a gastrointestinal stromal tumor (GIST).

there was no further evidence of gastrointestinal bleeding.

EUS-guided angiotherapy, as opposed to hemostatic techniques employed under direct endoscopic vision can delineate vascular anatomy and deliver targeted therapy to the vessel of interest [4]. Furthermore, immediate assessment of efficacy through color Doppler can be obtained. Important technical aspects that should be considered include using a 19-gauge needle as the larger diameter will allow a rapid injection. Additionally, we advise against aspiration of blood to confirm the position of the needle as this may lead to cyanoacrylate polymerization within the needle itself.

EUS-guided angiotherapy appears safe, effective, and technically feasible for the management of bleeding GISTs. Importantly, its application is not limited by the lesion's size. Future directions for its use may include patients with bleeding GISTs requiring a bridging therapy prior to surgery and those not suitable for surgical resection.

Endoscopy\_UCTN\_Code\_TTT\_1AS\_2AB

**Competing interests:** Mouen A. Khashab is a consultant for Boston Scientific and Olympus America and has received research support from Cook Medical. Anthony Kalloo is a founding member, equity holder, and consultant for Apollo Endosurgery.

**Vivek Kumbhari, Bilal Gondal, Patrick I. Okolo III, Anne Marie Lennon, Joanna K. Law, Vikesh K. Singh, Payal Saxena, Eun Ji Shin, Marcia I. Canto, Anthony N. Kalloo, Mouen A. Khashab**

Department of Medicine and Division of Gastroenterology and Hepatology, The Johns Hopkins Medical Institutions, Baltimore, Maryland, USA

#### References

- 1 Khashab MA, Cramer HM, Liangpunsakul S. Role of hemoclips in the management of acute bleeding from a gastric stromal tumor: a case report and review of the literature. *J Med Case Rep* 2007; 14: 136
- 2 Arezzo A, Verra M, Miegge A et al. Loop-and-let-go technique for a bleeding, large sessile gastric gastrointestinal stromal tumor (GIST). *Endoscopy* 2011; 43 (Suppl. 02): E18–E19
- 3 Levy MJ, Wong Kee Song LM, Farnell MB et al. Endoscopic ultrasound (EUS)-guided angiotherapy of refractory gastrointestinal bleeding. *Am J Gastroenterol* 2008; 103: 352–359
- 4 Gonzalez JM, Giacino C, Pioche M et al. Endoscopic ultrasound-guided vascular therapy: is it safe and effective? *Endoscopy* 2012; 44: 539–542

#### Bibliography

**DOI** <http://dx.doi.org/10.1055/s-0033-1344875>  
*Endoscopy* 2013; 45: E326–E327  
 © Georg Thieme Verlag KG  
 Stuttgart · New York  
 ISSN 0013-726X

#### Corresponding author

**Mouen A. Khashab, MD**  
 Department of Gastroenterology  
 Johns Hopkins Hospital  
 1800 Orleans St, Suite 7125 B  
 Baltimore  
 Maryland 21205  
 USA  
 Fax: +1-443-683-8335  
 mkhasha1@jhmi.edu