

Splenic artery pseudoaneurysm treated with thrombin injection guided by endoscopic ultrasound

Thrombin was first described as an aneurysmal occlusion agent in 1986. Since that time its therapeutic potential has been increasingly recognized. Percutaneous injection of thrombin has been reported as effective in the management of femoral pseudoaneurysms [1,2]. We present a case of pancreatic pseudoaneurysm of the splenic artery, which was successfully treated using a new approach that consisted of thrombin injection under endoscopic ultrasound (EUS) guidance.

A 29-year-old man with a history of multiple episodes of acute pancreatitis, heavy alcohol consumption, and heavy smoking for 15 years complained of abdominal pain that worsened after meals. Examination by EUS of the pancreas identified a pseudoaneurysm at the level of the pancreatic body, which was represented by a well-defined, 4.5-cm maximal diameter echogenic lesion containing an anechoic area of 2 cm with flow detected by Doppler, which communicated with the splenic artery by a 4.5-mm neck (● Fig. 1). A complementary three-dimensional (3D) computed tomography (CT) angiogram was performed, which confirmed the EUS findings (● Fig. 2). Under EUS control 1 mL of thrombin (500 UI/mL) was injected into the lesion through the posterior gastric wall via a 22-G Echotip needle (Wilson Cook, Winston-Salem, North Carolina, USA), and instantaneous obliteration occurred (● Fig. 3 and 4). A small focal splenic infarction without clinical relevance was identified on a CT scan performed 1 week later, which was probably due distal embolization. A repeat CT angiogram and EUS performed 4 months later confirmed persistence of the occlusion (● Fig. 5).

There have been few reports published that describe the procedure of thrombin injection into visceral pseudoaneurysms under EUS guidance [3]. An important point to be considered is the presence of a small neck forming the communication between the pseudoaneurysm and the artery, which increases the success of the treatment and decreases the risk of distant embolization. EUS-guided treatment of visceral pseudoaneurysms with thrombin injection can be successfully per-

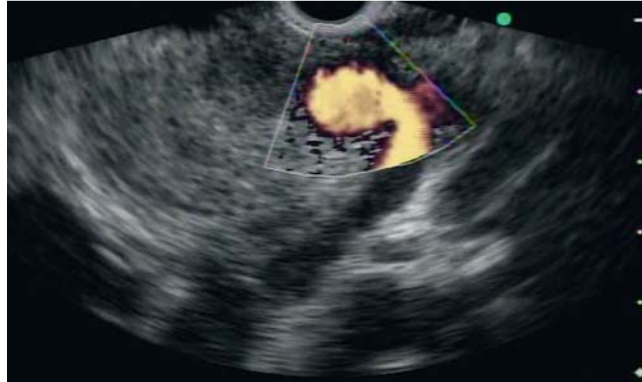

Fig. 1 Color Doppler image of the pseudoaneurysm.

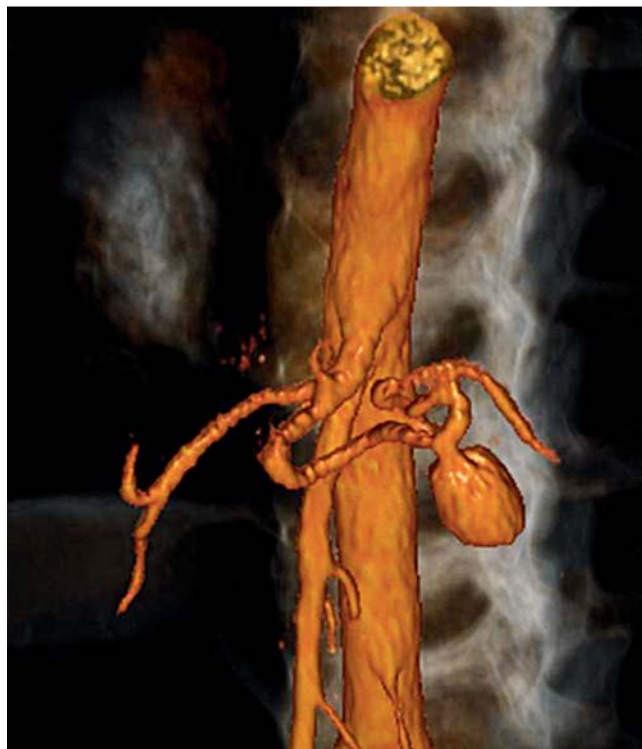

Fig. 2 Three-dimensional (3D) computed tomography (CT) angiogram showing the pseudoaneurysm of the splenic artery.

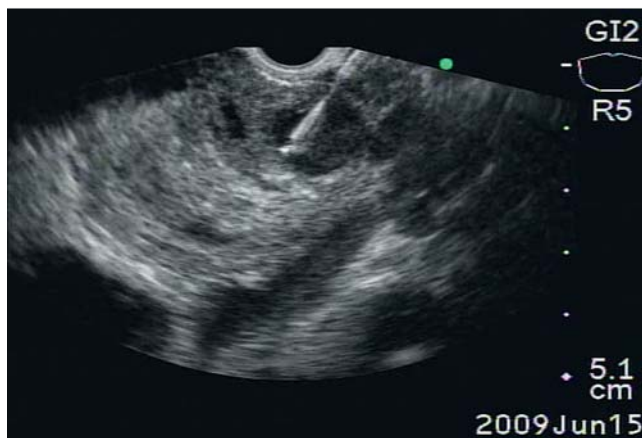


Fig. 3 EUS image showing the needle inside the pseudoaneurysm.

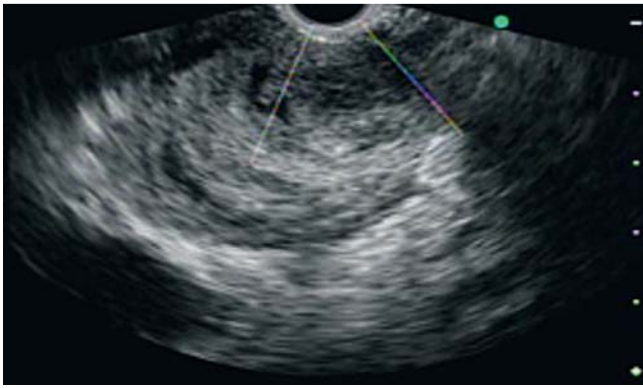


Fig. 4 EUS image taken immediately after the occurrence of thrombosis showing lack of flow within the splenic artery.

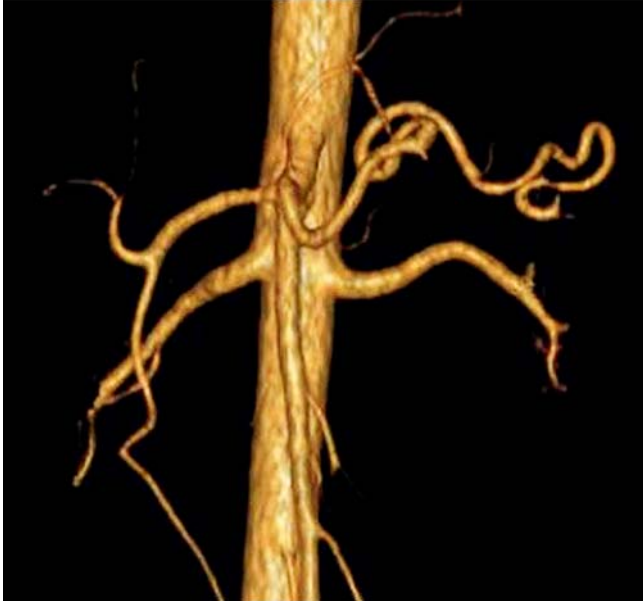

Fig. 5 Three-dimensional (3D) computed tomography (CT) angiogram taken 4 months later showing the splenic artery without the pseudoaneurysm sac.

formed. Although long-term follow-up is not yet available, the technique seems to be promising.

Endoscopy_UCTN_Code_TTT_1AS_2AG

Competing interests: None

D. M. Chaves, F. F. M. Costa, S. Matuguma, M. E. Lera dos Santos, E. G. H. de Moura, F. Maluf Filho, P. Sakai

Gastrointestinal Endoscopy Unit, Hospital das Clínicas, São Paulo University Medical School, Brazil

References

- 1 Sheiman RG, Brophy DP. Treatment of iatrogenic pseudoaneurysms with percutaneous thrombin injection: experience in 54 patients. *Radiology* 2001; 219: 123–127
- 2 Ferguson JD, Whatling PJ, Martin J et al. Ultrasound guided percutaneous thrombin injection of iatrogenic femoral artery pseudoaneurysms after coronary angiography and intervention. *Heart* 2001; 85: e5
- 3 Roach H, Roberts SA, Salter R et al. Pancreatic Pseudoaneurysm Treated by EUS-Guided Thrombin Injection. *Endoscopy* 2005; 37: 876–878

Bibliography

DOI 10.1055/s-0030-1256740

Endoscopy 2012; 44: E99–E100

© Georg Thieme Verlag KG Stuttgart · New York · ISSN 0013-726X

Corresponding author

D. M. Chaves, PhD

Hospital das Clínicas – FMUSP

Serviço de Endoscopia do Hospital das Clínicas

Av. Dr. Eneias de Carvalho Aguiar 255

Prédio dos ambulatórios, Piso 6, Sala 3

CEP-05403-900

São Paulo/SP

Brazil

dalton.chaves@fleury.com.br